

The background features a light gray gradient with several realistic water droplets of various sizes scattered across the surface. In the center, there is a faint, circular logo or watermark that is partially obscured by the text.

PENYAKIT PARU OKUPASIONAL

DIAN YULIARTHA LESTARI

- PENYAKIT PARU OKUPASIONAL HARUS DIPIKIRKAN PADA SETIAP PASIEN DENGAN MASALAH PERNAPASAN
- PENYAKIT PARU OKUPASIONAL MENYERTAI PAJANAN TERHADAP ASAP ATAU DEBU ORGANIK MAUPUN ANORGANIK

TABLE 15-6 Lung Diseases Caused by Air Pollutants

Agent	Disease	Exposure
MINERAL DUSTS		
Coal dust	Anthracosis Macules Progressive massive fibrosis	Coal mining (particularly hard coal)
Silica	Caplan syndrome Silicosis	Foundry work, sandblasting, hard rock mining, stone cutting, others
Asbestos	Caplan syndrome Asbestosis Pleural plaques Caplan syndrome Mesothelioma	
Beryllium	Carcinoma of the lung, larynx, stomach, colon Acute berylliosis Beryllium granulomatosis Lung carcinoma (?)	Mining, fabrication
Iron oxide	Siderosis	Welding
Barium sulfate	Baritosis	Mining
Tin oxide	Stannosis	Mining
ORGANIC DUSTS THAT INDUCE HYPERSENSITIVITY PNEUMONITIS		
Moldy hay	Farmer's lung	Farming
Bagasse	Bagassosis	Manufacturing wallboard, paper
Bird droppings	Bird-breeder's lung	Bird handling
ORGANIC DUSTS THAT INDUCE ASTHMA		
Cotton, flax, hemp	Byssinosis	Textile manufacturing
Red cedar dust	Asthma	Lumbering, carpentry
CHEMICAL FUMES AND VAPORS		
Nitrous oxide, sulfur dioxide, ammonia, benzene, insecticides	Bronchitis, asthma Pulmonary edema ARDS Mucosal injury Fulminant poisoning	Occupational and accidental exposure

- THESE DISORDERS ARE CAUSED BY AEROSOLS

- MINERAL DUST - FUMES
- ORGANIC DUST - VAPORS

- FOLLOWING FACTORS DETERMINE THE OUTCOME OF INHALATION:

- THE AMOUNT OF DUST RETAINED

→ FUNCTIONING OF ORIGINAL CONCENTRATION, DURATION OF EXPOSURE, EFFECTIVENESS OF CLEARANCE MECHANISM

- SIZE, SHAPE AND BUOYANCE OF PARTICLES

→ >5 UM FILTERED IN UPPER AIRWAYS

→ < 1 UM SUSPENDED AND EXHALED

→ 1-5 UM SETTLE IN THE ALVEOLI → PATHOLOGICALLY SIGNIFICANT

- PHYSICOCHEMICAL REACTIVITY AND SOLUBILITY OF PARTICLES

PNEUMOCONIASIS

- SUMBER → BATU BARA
 - ANORGANIK (MUSKOVIT, KAOLIN)
 - TRACE ELEMENT (ARSEN, TITANIUM, BERILIUM)
- INSIDEN DAN PROGRESIVITAS → PAJANAN KUMULATIF & PERINGKAT BATU BARA (COAL RANK)
- PENILAIAN PNEUMOCONIASIS → INTERNASIONAL LABOUR ORGANIZATION (BERDASARKAN UKURAN OPASITAS RADIOLOGIS)

COAL WORKER'S PNEUMOCONIASIS

- ANTHRACOSIS → SMALL, HARMLESS ACCUMULATION IN THE LUNGS OF URBAN DWELLERS AND SMOKERS
- CWP
 - SIMPLE CWP
 - COMPLEX CWP

SIMPLE CWP

- DIAGNOSIS RADIOLOGIS ATAU PATOLOGIS TANPA ADANYA GEJALA
- LESI AWAL :
 - KUMPULAN MACROFAG MENGANDUNG DEBU DI SEKITAR BRONCHIOLUS DAN ALVEOLI
 - LESI HITAM (MAKULAR) MULTIPLE BILATERAL, <1 CM, 2/3 ATAS PARU
 - DAPAT DISERTAI EMFISEMA LOKA (SENTRILOBULER)

COMPLEX CWP

- GEJALA BERKAITAN DENGAN : EMFISEMA BULOSA
 - SESAK, BATUK, DISPNEU EKSERSIONAL, DAPAT BERKEMBANG MENJADI COR PULMONALE
- DITEMUKAN ADANYA FIBROSIS YANG MASIF PROGRESIF
 - AREA FIBROSIS ELASTIS (RUBBERY) LUAS, > 1CM, LOBUS ATAS

HISTOLOGI

- DIDAPATKAN AGGREGASI DUST-LADEN MACROFAG DENGAN SEDIKIT FIBROSIS (**COAL DUST MACULES**) DI LOBUS ATAS, DISERTAI DENGAN EMPHEMA LOKAL
- COAL DUST MACULES DAPAT DITEMUKAN DI DINDING BRONCHIOLUS DAN ALVEOLI
- DITEMUKAN PULA NODUL FIBROSIS YANG MENGANDUNG COAL DUST MACULES (**COAL DUST NODULES**) DI BRONCHIOLUS
- COAL DUST NODUL MEMBERIKAN GAMBARAN AREA FIBROCOLLAGEN DIBAGIAN SENTRAL YANG BERPUTAR (WHORL) DENGAN BAGIAN TEPI MENGANDUNG DUST-LADEN MACROPHAG MEMBERIKAN GAMBARAN **MEDUSA HEAD**




Figure 147.1 Whole lung section of simple coal worker's lung showing coal dust macules, predominantly involving the upper lung lobe. (Gough-Wentworth whole section by Dr. Jethro Gough and Dr. I.E. Wentworth courtesy of Dr. Allen R. Gibbs and Dr. Richard Attanoos.)



Figure 147.2 Whole lung section of coal worker's lung with coalescing nodules, forming progressive massive fibrosis. (Gough-Wentworth whole section by Dr. Jethro Gough and Dr. I.E. Wentworth courtesy of Dr. Allen R. Gibbs and Dr. Richard Attanoos.)

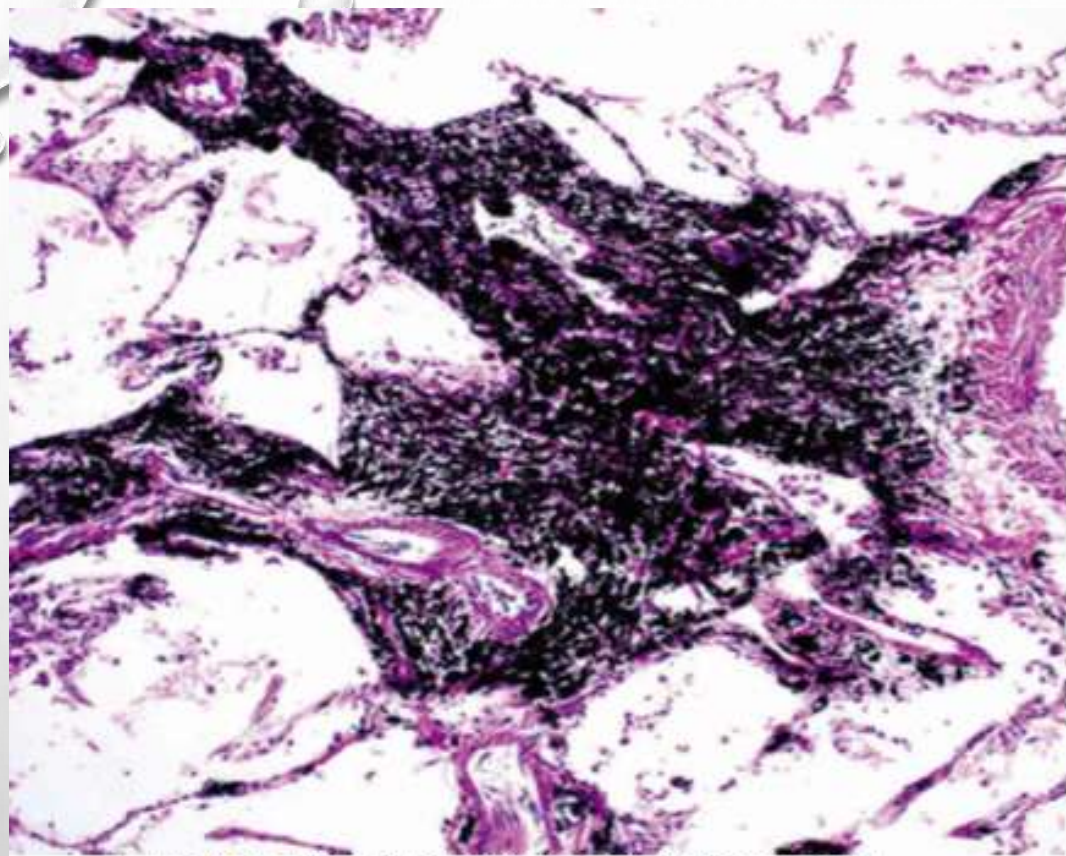


Figure 147.5 Coal dust macule containing coal dust-laden macrophages involving alveolar walls; fibrous tissue is apparent, and there is no fibrosis.

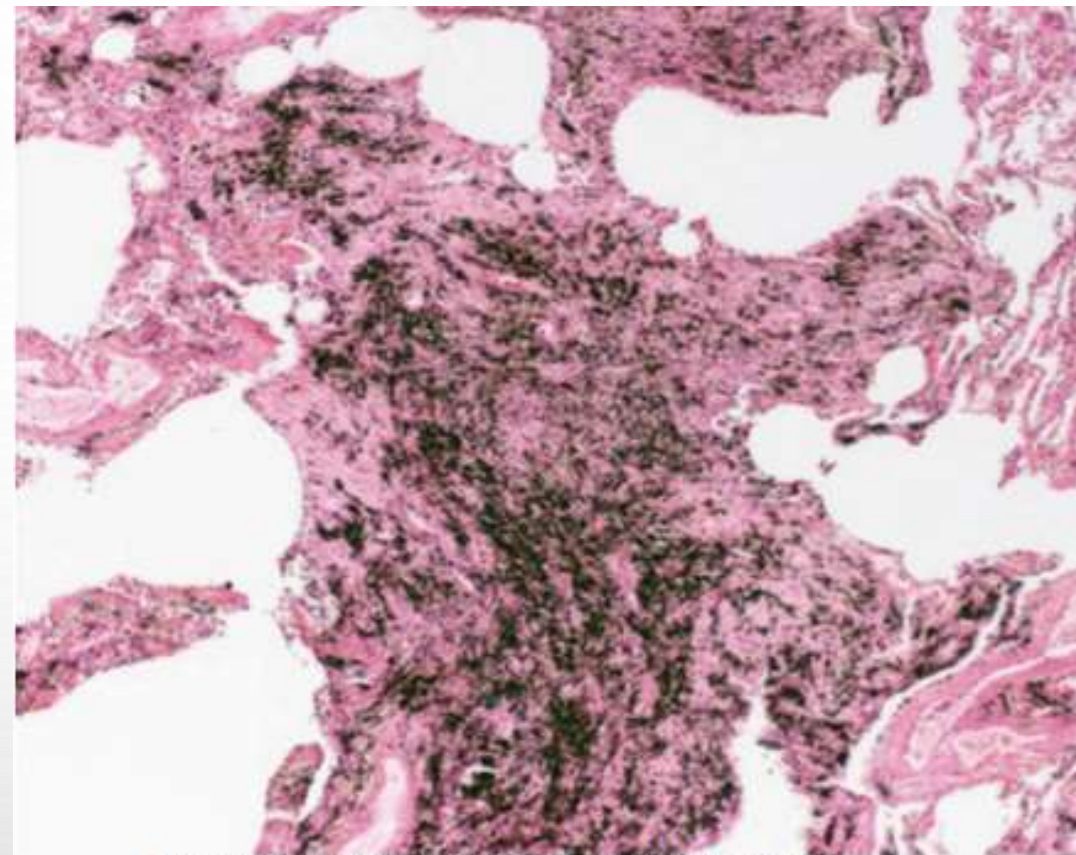


Figure 147.6 Coal dust nodule with dust-laden macrophages and fibrosis.

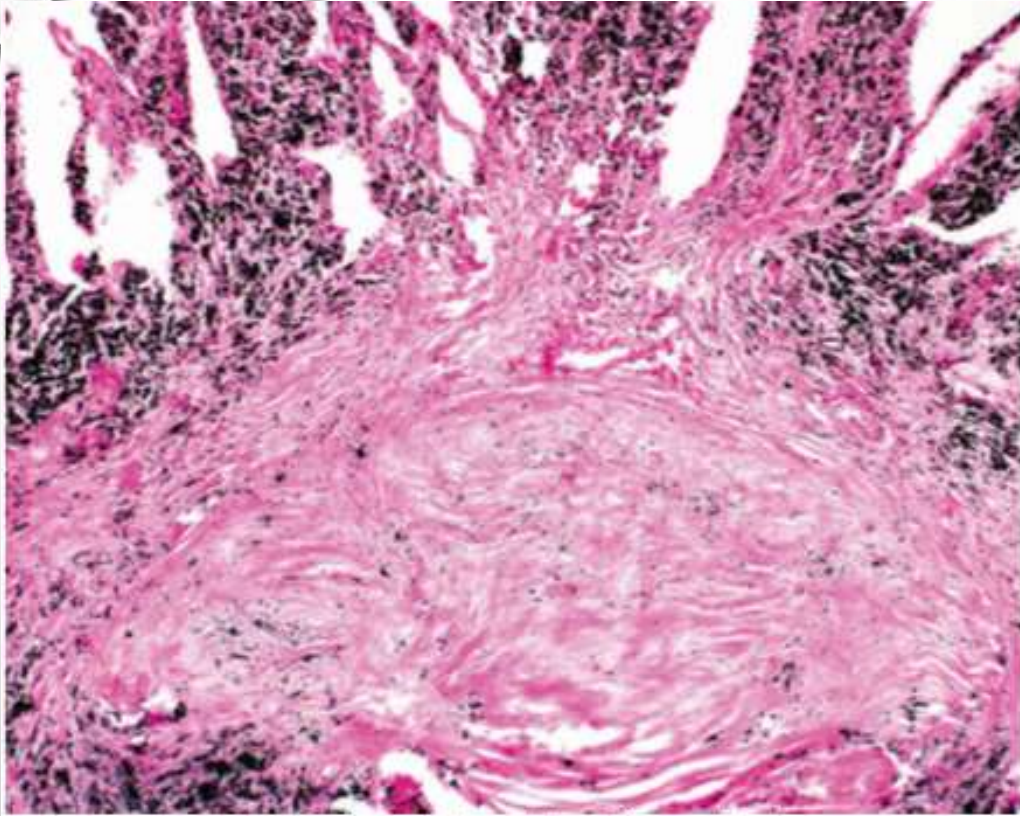


Figure 147.7 Coal dust nodule with dust-laden macrophages and fibrosis, showing whorls of dense hyalinized collagen, denoting exposure to coal dust containing quartz silica, and a "medusa head" of surrounding dust-laden macrophages.

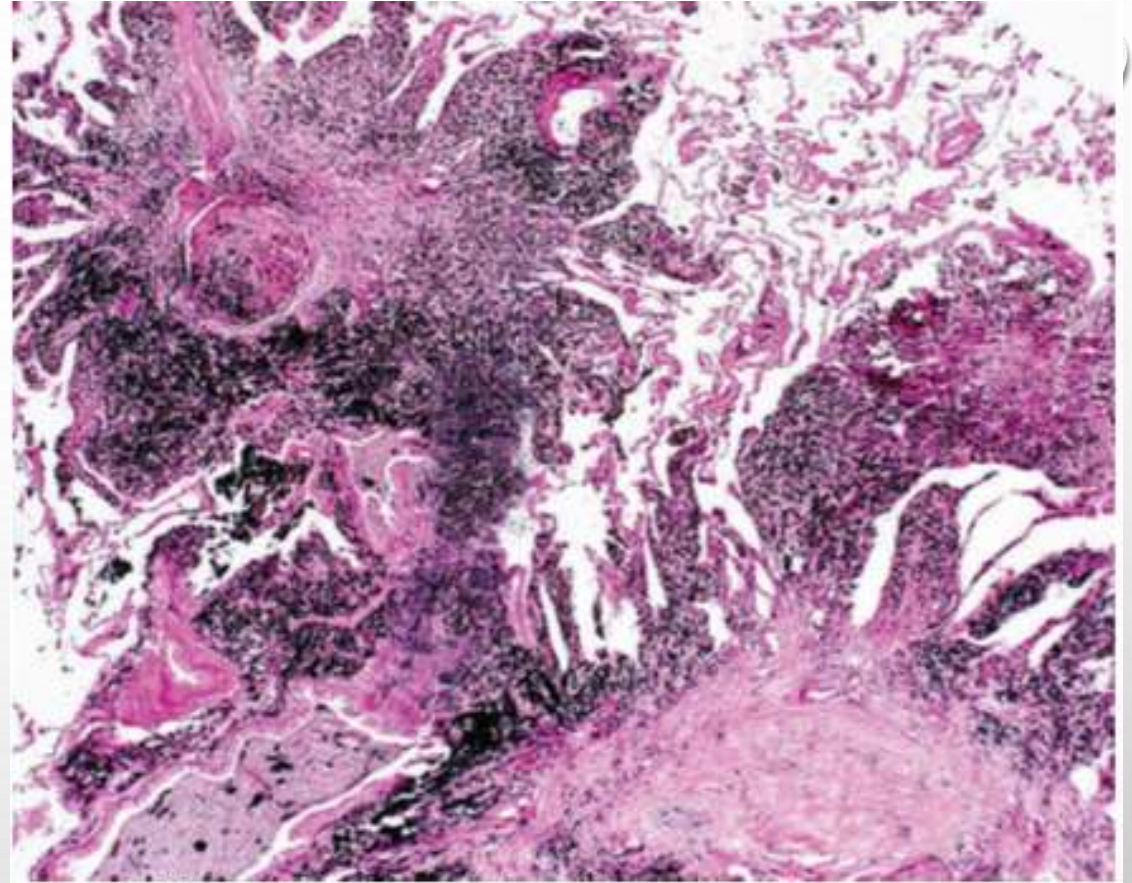


Figure 147.8 Coal dust nodules may coalesce, ultimately resulting in progressive massive fibrosis with confluent areas of fibrosis 2 cm and larger.

SINDROM KAPLAN

- PNEUMOCONIASIS + RHEMATOID
- RADIOLOGI PARU → LESI BULAT DI DAERAH PERIFER
- LESI PARU MENDAHULUI NYERI SENDI
- HPA :
 - NODUL BULAT (MM-CM), KAVITAS +, KALSIFIKASI +
 - KOMBINASI NODUL REMATOID + FIBROSIS
 - ZONA TENGAH : BAHAN KOLAGEN + DEBU
 - ZONA PERIFER : FAIBROSIS PALISADE

SILICOSIS

- PENYAKIT FIBROTIK PARU AKIBAT INHALASI DEBU YANG MENGANDUNG KRISTAL SILICON DIOKSIDA
- PROGRESIFITAS TERGANTUNG : UKURAN PERTIKEL, BENTUK MINERAL, KERENTANAN INDIVIDU
- PAJANAN SILICA → PENGGALIAN, PEMOTONGAN BATU, PERTAMBANGAN, PEMBUATAN TEROWONGAN
- GAMBARAN KLINIS :
 - BERGANTUNG PADA LAMA DAN INTENSITAS PAJANAN
 - AKUT → DISPNEU AKUT DISERTAI AKUMULASI LIPOPROTEIN DI ALVEOLI
 - KRONIS → GEJALA SAMA DENGAN FIBROSIS MASIF PROGRESIF

- SIMPLE SILICOSIS = NODULAR SILICOSIS = CHRONIC SILICOSIS → ADANYA NODUL SILICA < 1 CM
- BIASANYA PAPARAN 20-40 TAHUN
- PROGRESIVE MASSIVE FIBROSIS → NODUL SILICA > 2 CM
- NODUL SILICA → NODUL BERBATAS JELAS, TERDIRI DARI JARINGAN IKAT HYALIN-COLLAGEN YANG BERPUTAR (WHORL), CALSIFIKASI +/-; SERING DITEMUKAN PADA SUBPLEURA ATAU UPPER LOBE
- PLEURAL NODULES → CANDLE WAX LESION OR PLEURAL PEARLS



Figure 144.2 Whole lung section of nodular silicosis from a slate worker; note rounded to oval masses of hyalinized collagen.

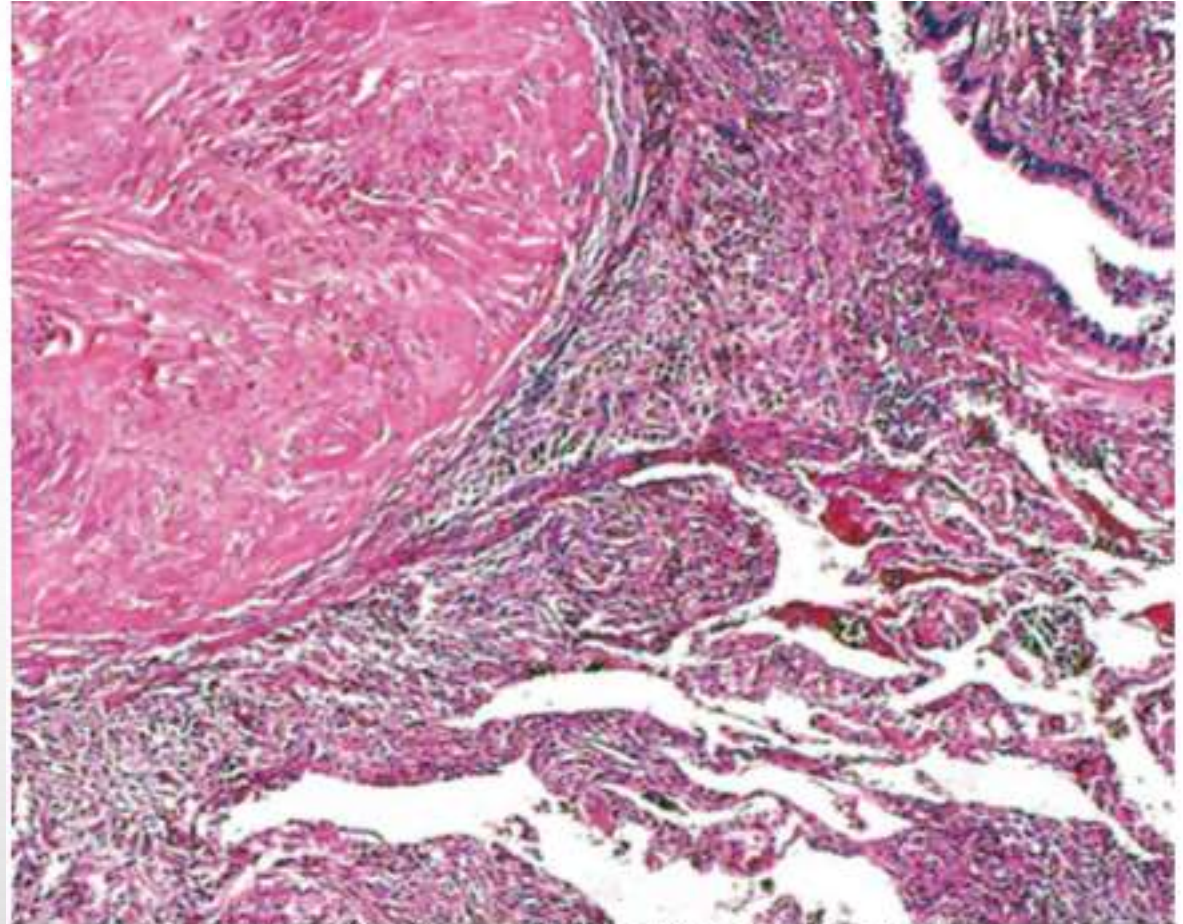


Figure 144.3 Silicotic nodule showing central whorl of almost acellular hyalinized collagen and anthracotic pigment and peripheral dust-laden macrophages.

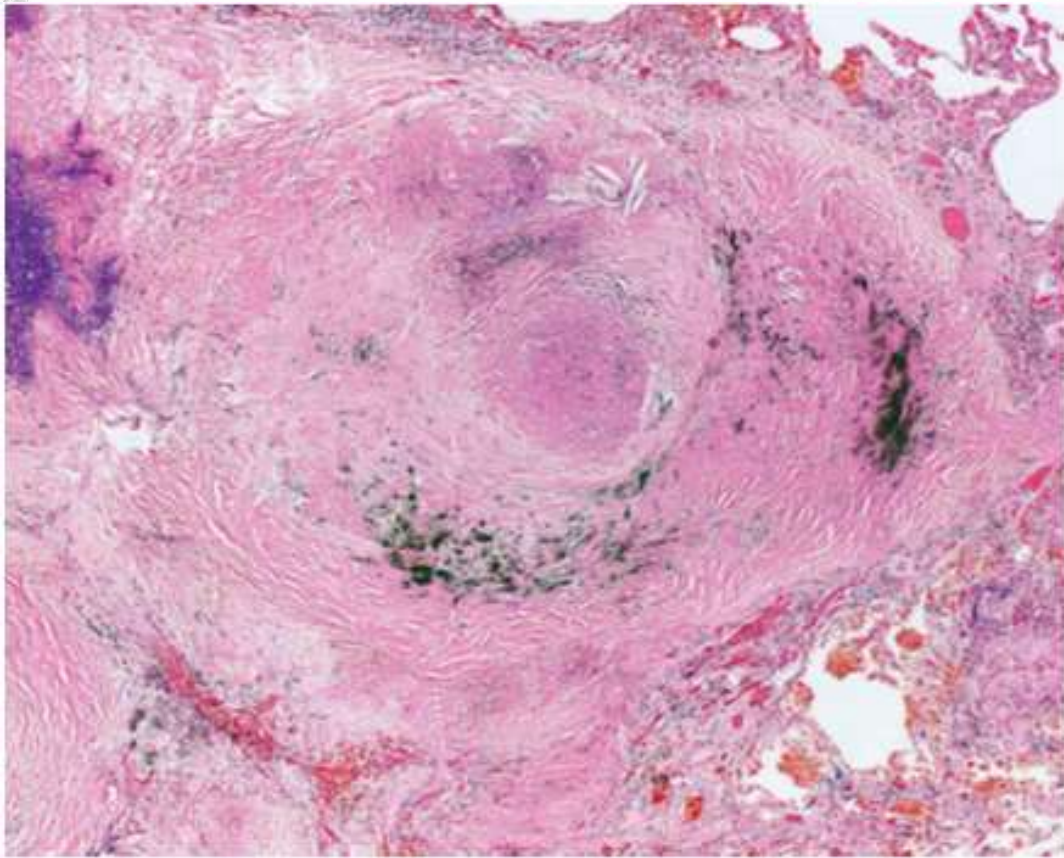


Figure 144.7 Complicated silicosis, also termed *progressive massive fibrosis*, with large confluent advanced silicotic nodules.

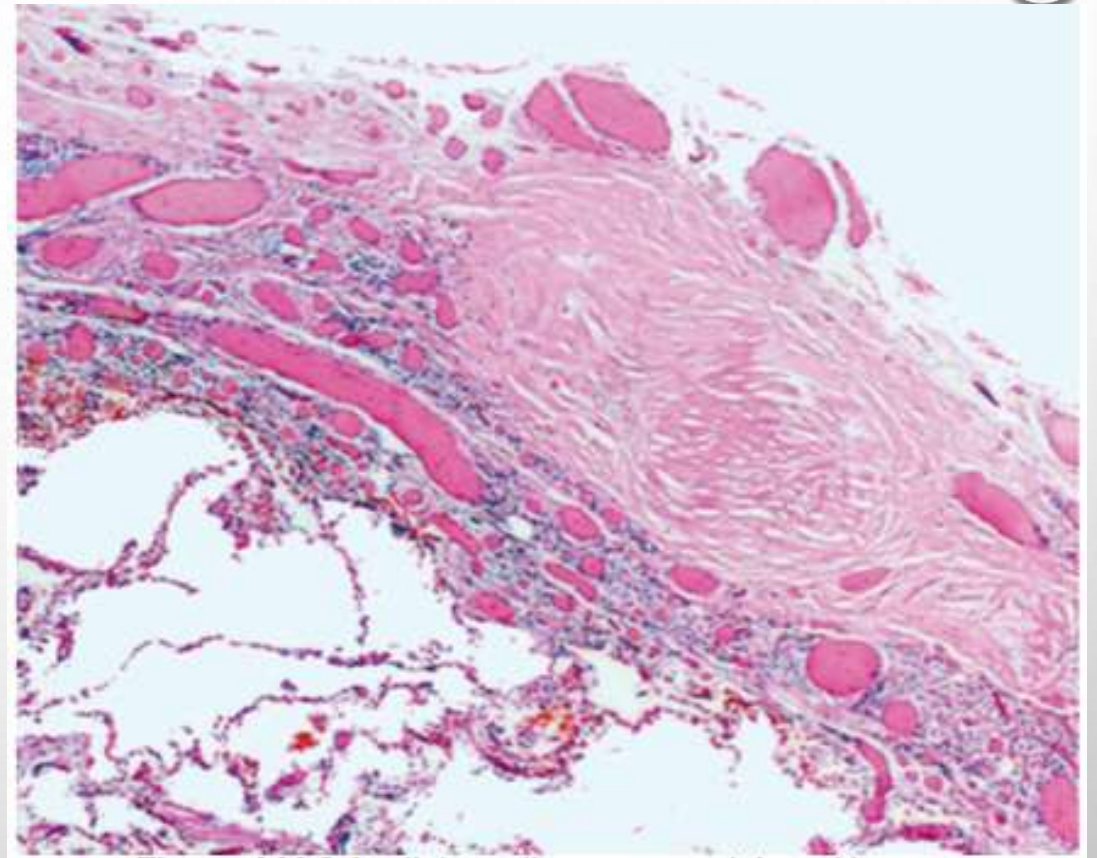


Figure 144.8 Acellular collagenous nodules with "whorled" appearance present in the pleura; these appear externally as "candle wax" lesions.



- KOMPLIKASI

- TB PARU → AKIBAT EFEK TOKSIS SILICA PADA MACROFAG
- ASPERGILLOSIS
- PNEUMOTHORAX → KRN EMFISEMA BULOSA

SILICOSIS BERHUBUNGAN DENGAN PENYAKIT KOLAGEN → PEMBENTUKAN ANTIBODI ANTINUCLEAR TERHADAP SILICOSIS



SILICATOSIS

- INHALASI DARI SILICATE → TALC, KAOLINITE, MICA, VERMICULITE
- MOST PASIEN → ASYMPTOMATIC
- HISTOLOGIS :
 - ADA 6 TIPE → MACULA, NODULE, FIBROSIS, FOREIGN BODY GRANULOMA, INTERSTITIAL FIBROSIS, MASSIVE FIBROSIS
 - MACULA, NODULE, FIBROSIS → DIANTARA DINDING BRONCHIOLUS
 - FIBROTIC NODULE → 2-10 MM, UPPER DAN MIDDLE ZONE

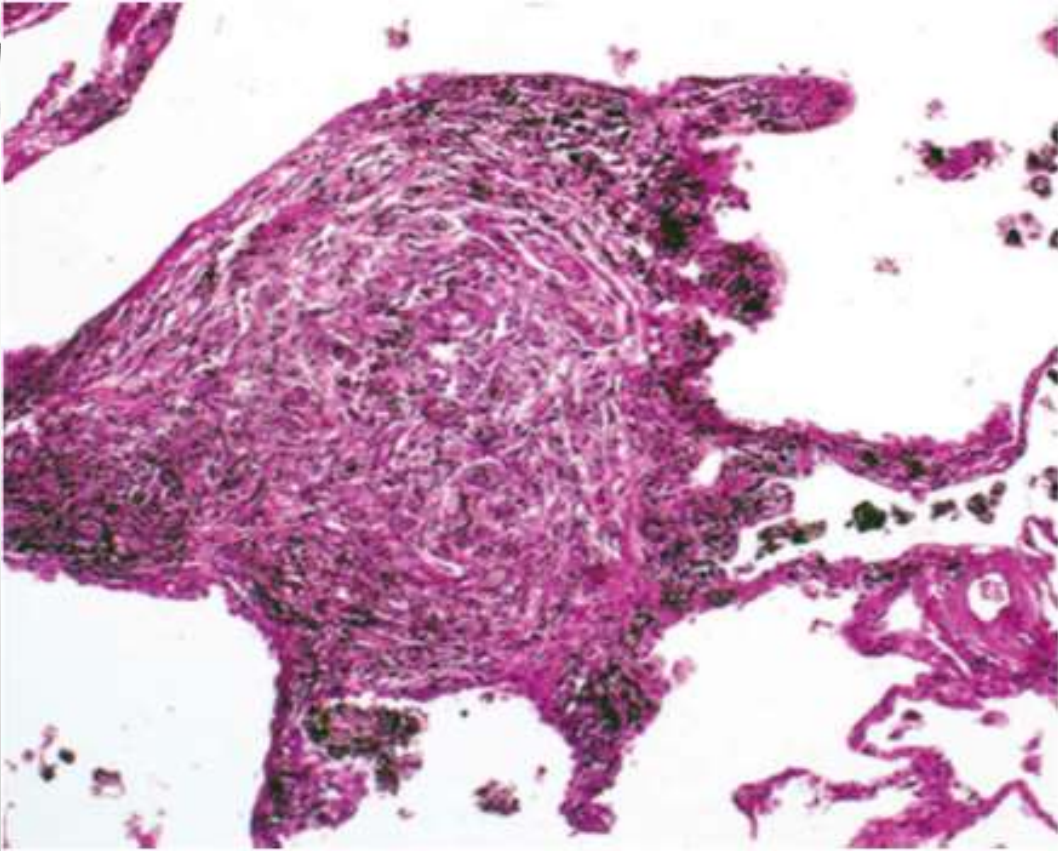


Figure 145.1 Silicate nodule, with collagen bundles and dust-laden macrophages.

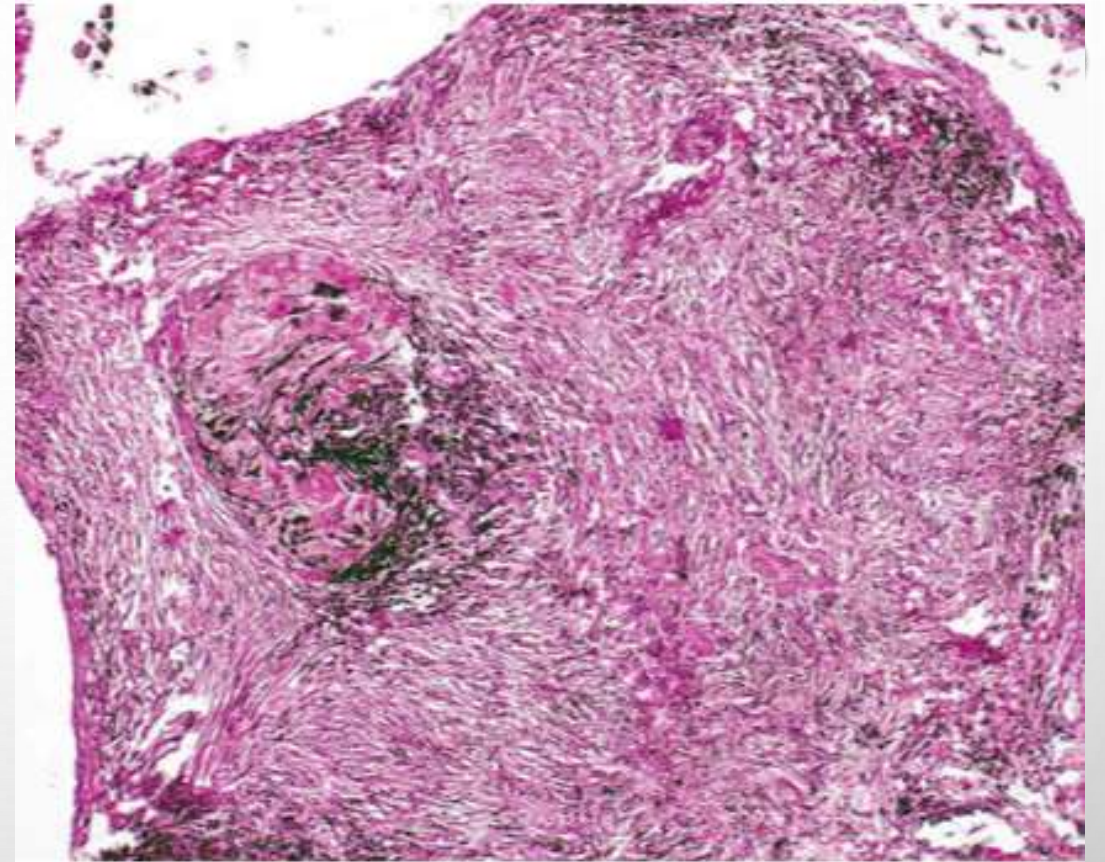


Figure 145.2 Focus of massive fibrosis with diffuse collections of dust-laden macrophages.

ASBESTOSIS

- ASBES → SEKUMPULAN SILICAT FIBROSA
 - 2 KELOMPOK : SERPENTINE (90%) DAN AMFIBOL (CARCINOGENIK)
- BERHUBUNGAN DENGAN PEMBUATAN KAPAL, INDUSTRI KONSTRUKSI, DAN PEMBONGKARAN
- DAPAT MENYEBABKAN KANKER PARU SERTA MESOTHELIOMA
- ASBESTOSIS MENGINDIKASIKAN FIBROSIS PARU AKIBAT ASBES
- BADAN ASBES
 - AMFIBOL
 - INTI FIBROSA SENTRAL YANG DILAPISI OLEH BESI → LONCENG COKLAT KEEMASAN

- ASBESTOSIS → BENTUK FIBROSIS PARU INTERSITIAL YANG TERJADI SETELAH PAJANAN SUBSTANSIAL ASBES DALAM WAKTU LAMA (>20 TAHUN)
- PREVALENSI BERKAITAN DENGAN : USIA, TIPE SERAT ASBES, MEROKOK, DAN PAJANAN KUMULATIF
- KLINIS :
 - BATUK NON PRODUKTIF
 - CRACLE BASAL
 - DISPNEU
 - LANJUT → JARI TABUH DAN COR PULMONALE
- HISTOLOGI :
 - DIAGNOSIS → BADAN ASBES (MINIMAL 2) DAN FIBROSIS PARU
 - FIBROSIS (ASBES) → PERIFER DAN LOWER LOBE

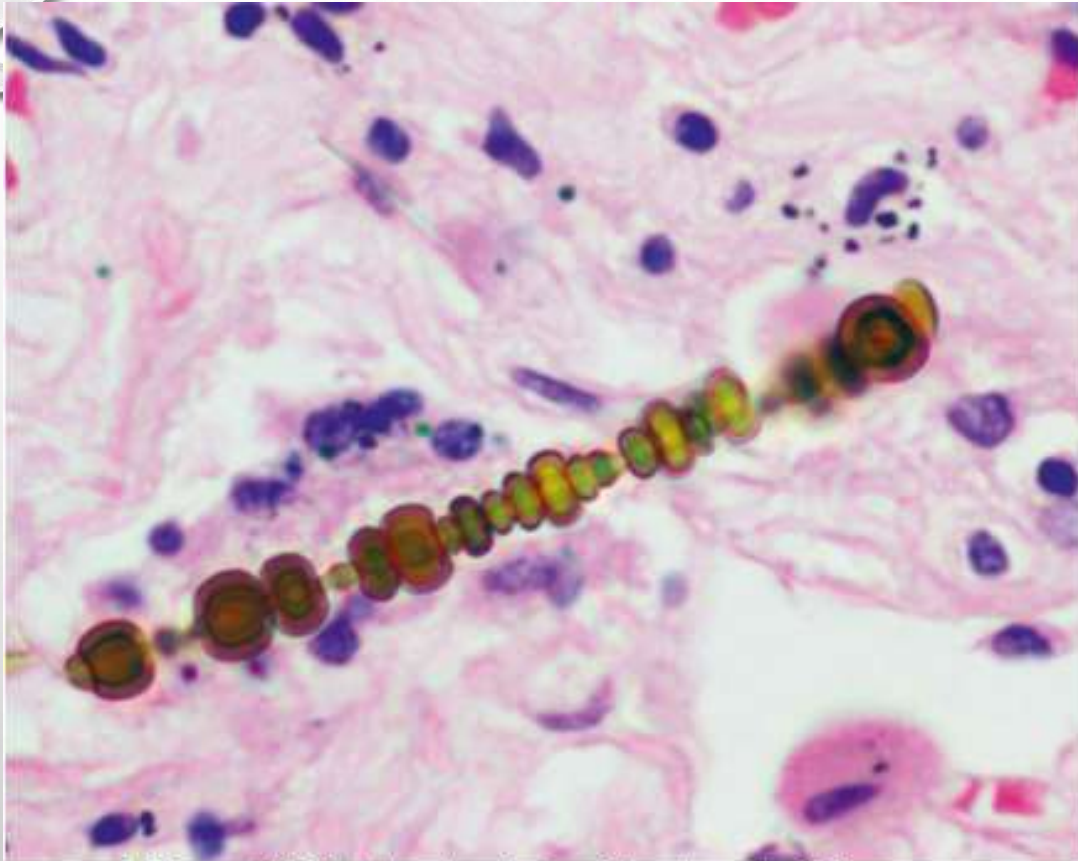


Figure 143.1 Asbestos body with characteristic dumbbell shape and clear central fibrous core.

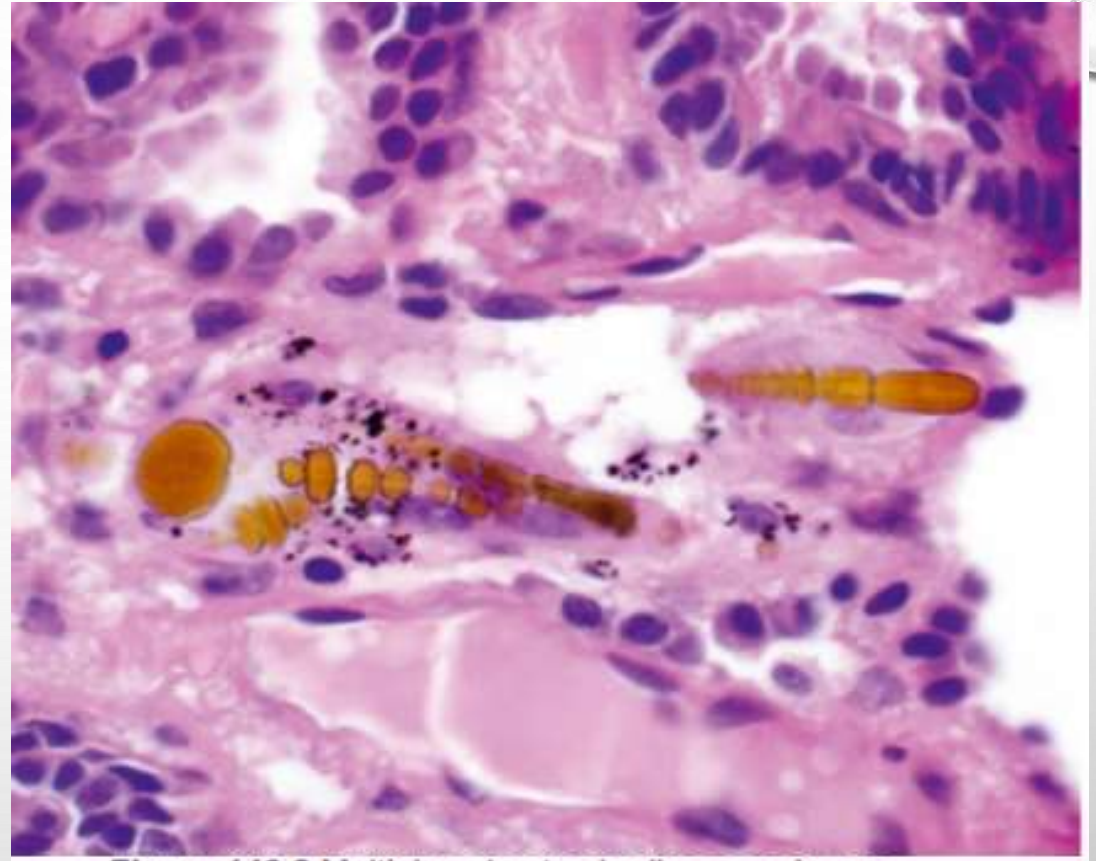


Figure 143.2 Multiple asbestos bodies seen in one field are indicative of very high exposure to asbestos.

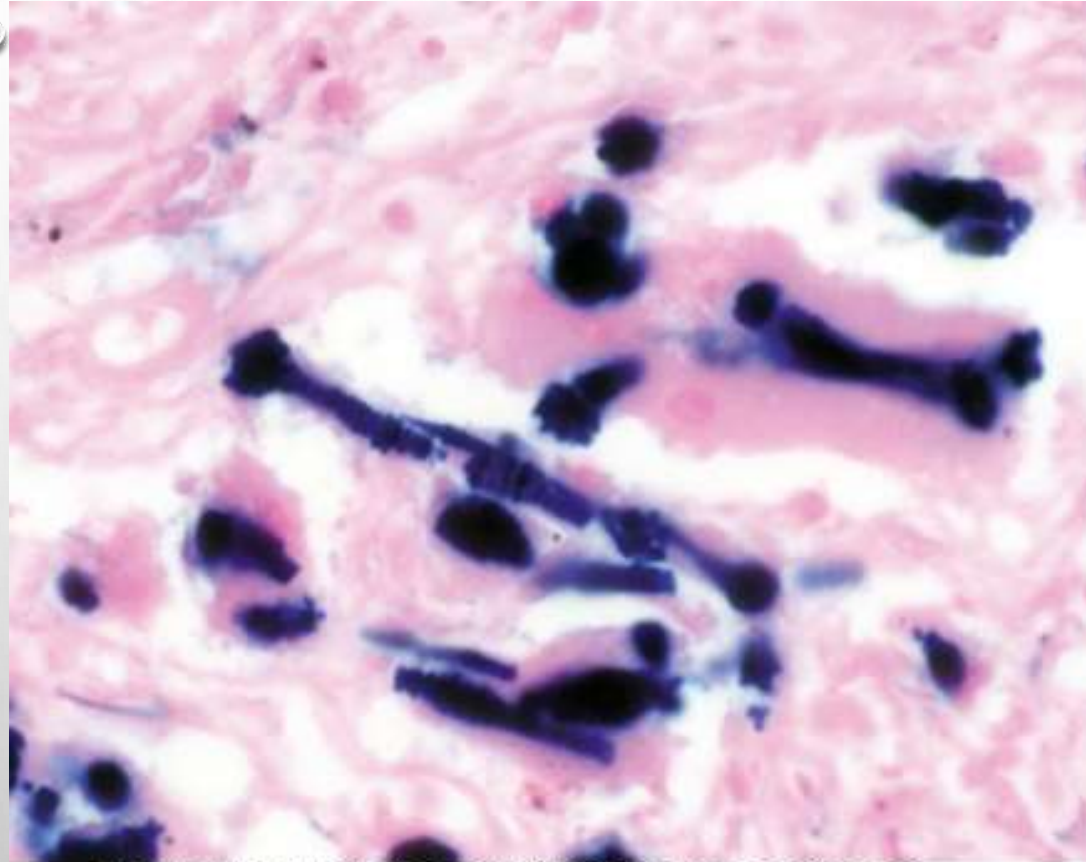


Figure 143.3 Iron stain highlights the iron coatings of asbestos bodies, assisting in their identification.

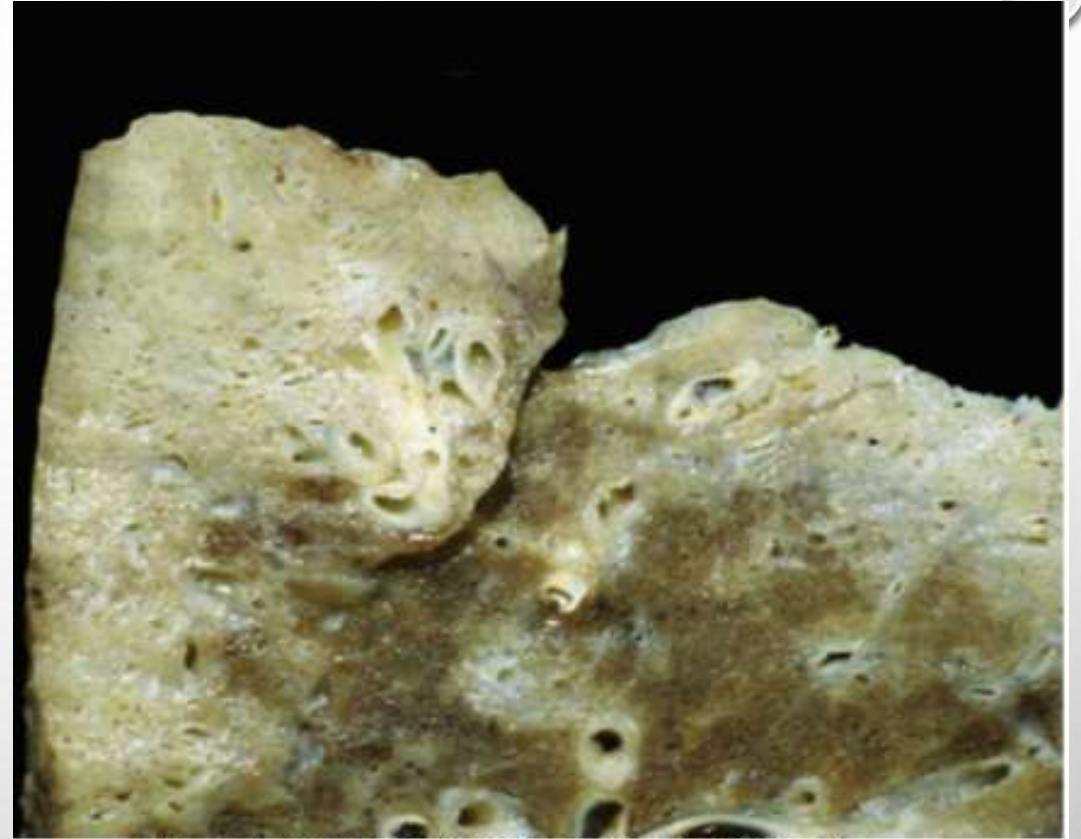

Figure 143.4 Gross image of severe asbestosis showing marked fibrosis.

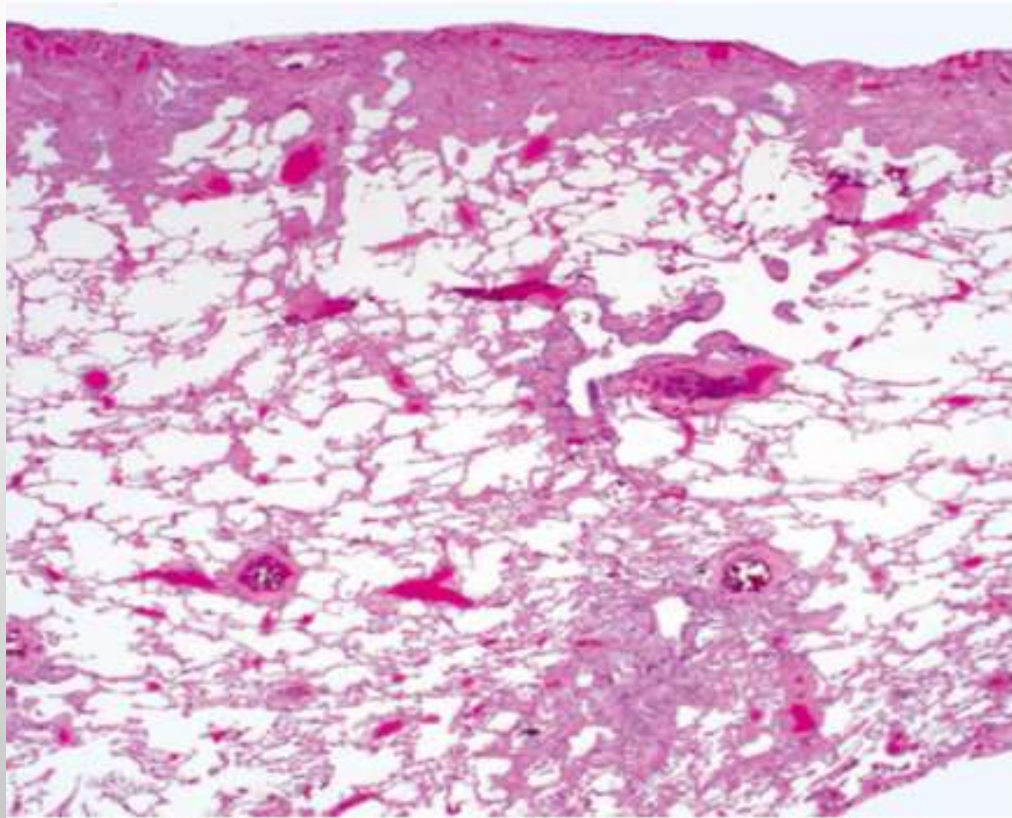


Figure 143.6 Early asbestosis showing predominantly peripheral and peribronchiolar fibrosis.

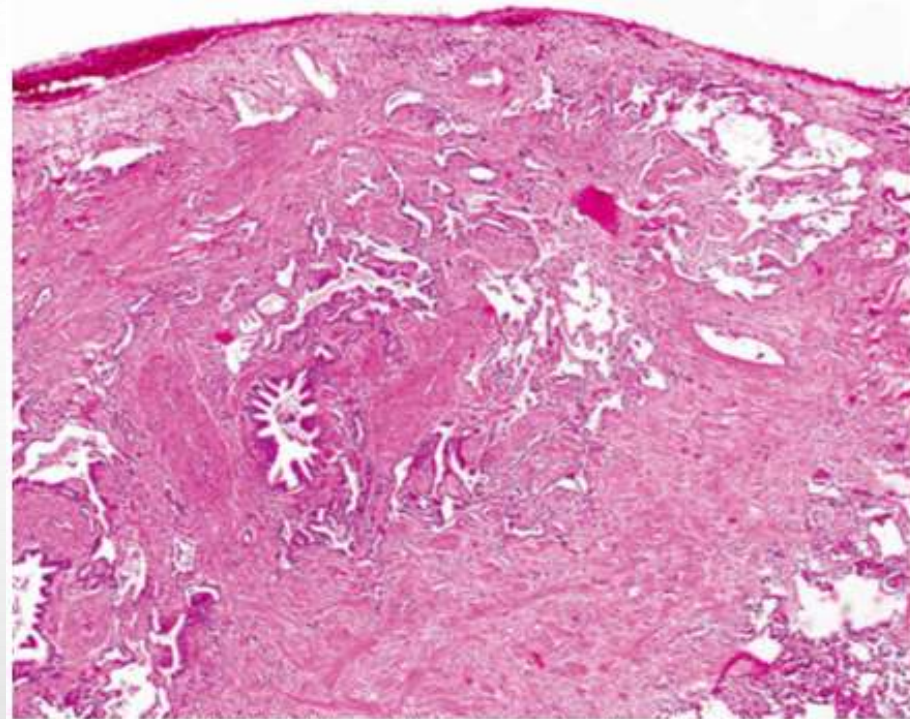


Figure 143.7 Peripheral fibrosis, predominantly in the lower lung lobes, is a characteristic feature of asbestosis; however, it may be seen in other interstitial lung diseases, such as usual interstitial pneumonia.

SIDEROSIS

- BIASA TERJADI PADA PENAMBANG BESI → DITANDAI DENGAN ADANYA MINERAL BESI DI PARENCHYM PARU
- HISTOLOGIS :
 - DEPOSIT BESI PADA PERIBRONCHIAL DAN PERIVASCULER
 - IRON OXIDE → BULAT-OVAL, COKLAT KEMERAHAN – HITAM KEMERAHAN
 - DIANTARA DEPOSIT BESI → GOLDEN HALO

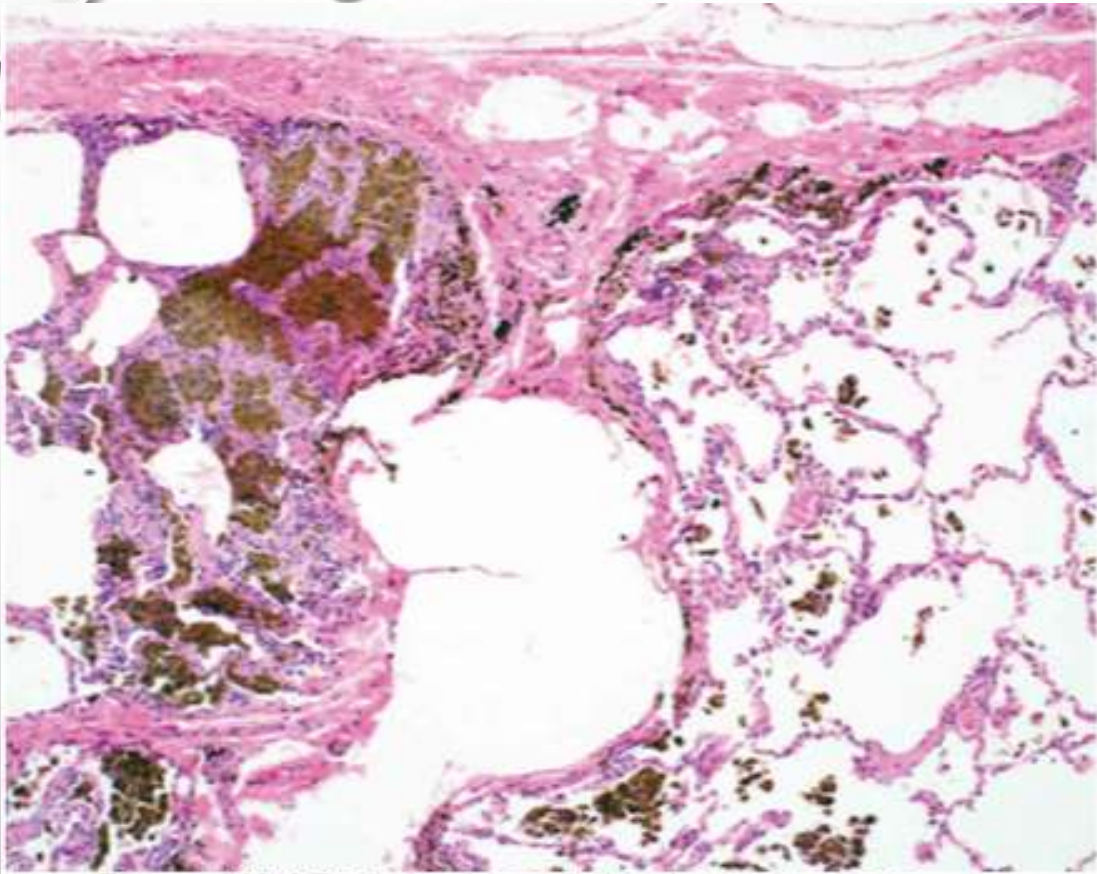


Figure 149.1 Perivascular and alveolar macrophage deposition of iron.

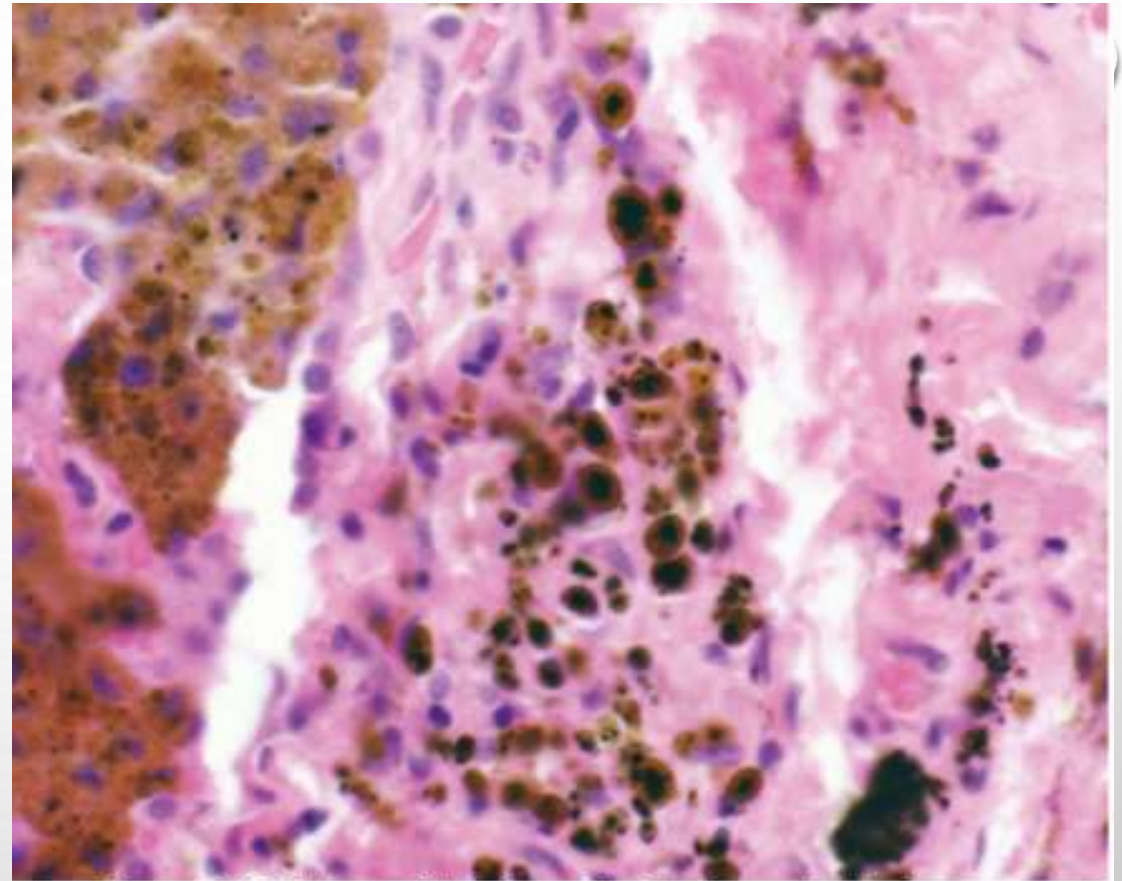


Figure 149.5 Iron oxide pigment, with brown to black cores and surrounding golden halo.

ALUMINOSIS

- DISEBUT JUGA ALUMINIUM PNEUMOCONIASIS → INDUSTRI YANG MELIBATKAN ALUMINIUM HYDROXIDE
- MAKROSKOPIS :
 - MENUNJUKKAN AREA FIBROSIS YANG TERKADANG DIDAPATKAN GAMBARAN ABU-ABU METALIC
- DD :
 - PNEUMOCONIASIS
 - SARCOIDOSIS

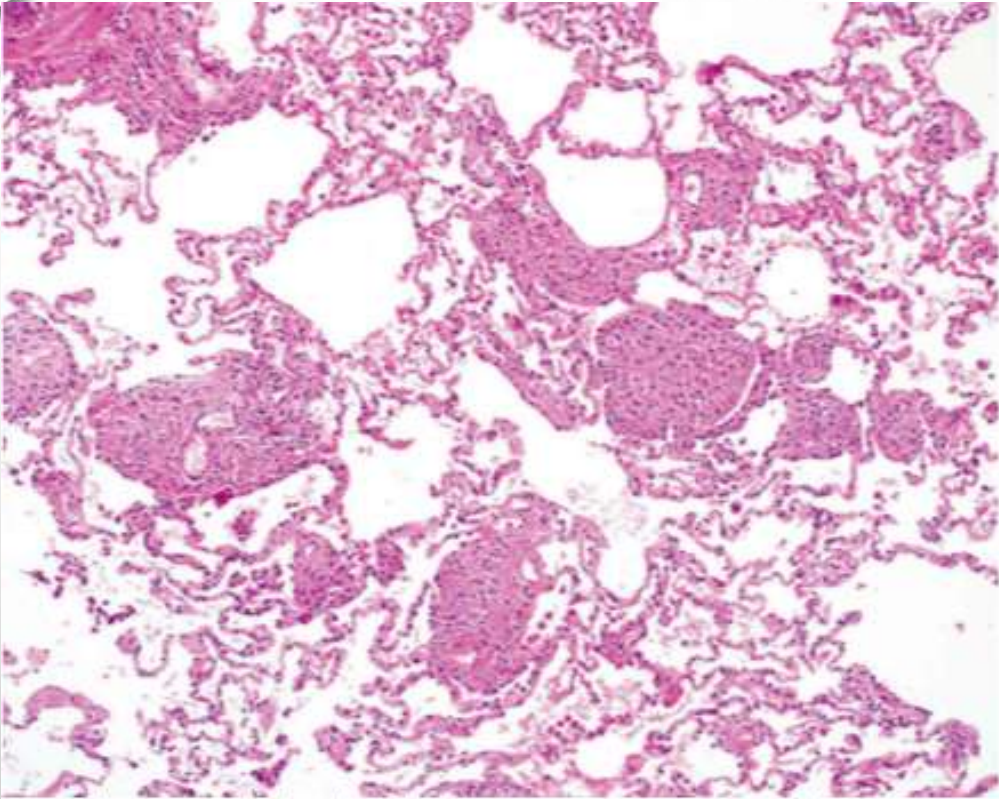


Figure 150.1 Nests of dust-laden macrophages within lung parenchyma.

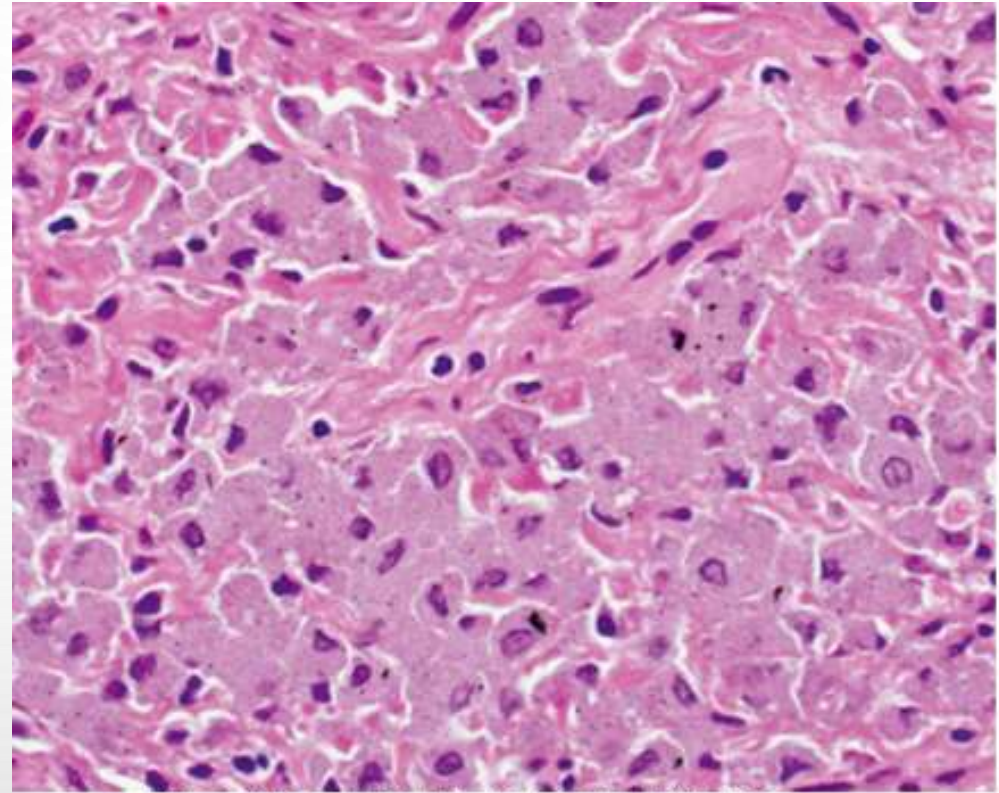


Figure 150.2 Brownish-gray pigment fills the macrophages.

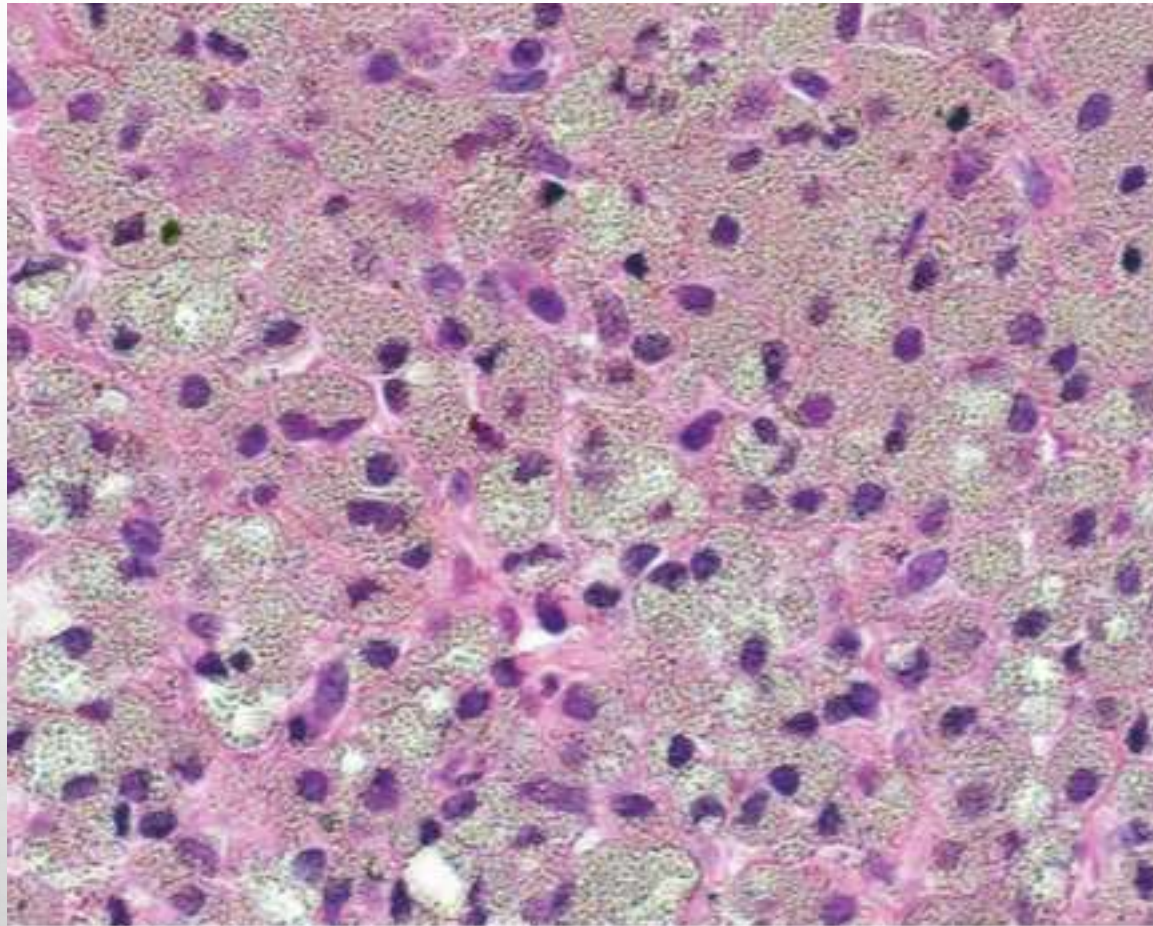


Figure 150.3 The pigment within the macrophages is refractile; however, it does not birefringent by polarized light.

PNEUMONITIS HIPERSENTISITIVAS (ALVEOLITIS ALERGIK EKSTRINSIK)

- FARMER'S LUNG → INFILTRAT PARU INTERSITIAL DIFFUSE YANG MELIBATKAN SALURAN NAFAS KECIL
- AKUT :
 - BATUK, DISPNEU, SESAK, DEMAM 4-8 JAM SETELAH PAPANAN
 - BERKURANG DALAM 12-16 JAM JIKA TIDAK ADA PAJANGAN YANG BERULANG
 - RO : NODUL HALUS BILATERAL
- KRONIS :
 - DISPNEU, BATUK KRONIS, PENURUNAN BERAT BADAN
 - LANJUT → GAGAL NAPAS DAN JARI TABUH
 - RO : HONEY COMB APP

Tabel 7.3 Beberapa faktor yang berhubungan dengan alveolitis alergi ekstrinsik

Pelembap	Antigen bakteri yang berhubungan dengan kondisi lembap
Paru petani (farmer's lung)	Debu dari jerami, termofilik <i>Actinomyces</i> spp.
Paru peternak merpati (pigeon fancier's lung)	Antigen bulu, ekskret/kotoran
Pengrajin kayu	
Pemanen jamur	

- **IMUNOPATOGENESIS**

- HASIL BAL → 70% LIMFOSIT T
- RASIO CD4:CD 8 → NORMAL/RENDAH

- **PATOLOGI:**

- INFLAMASI KRONIS BRONCHOSENTRIK → ORGANIZING PNEUMONIA
- FOAMY MACROFAG DI ALVEOLUS
- SEL DATIA (GIANT CELL)
- GRANULOMA KECIL NON NECROSIS

QUESTION?