

PENCERNAKAN

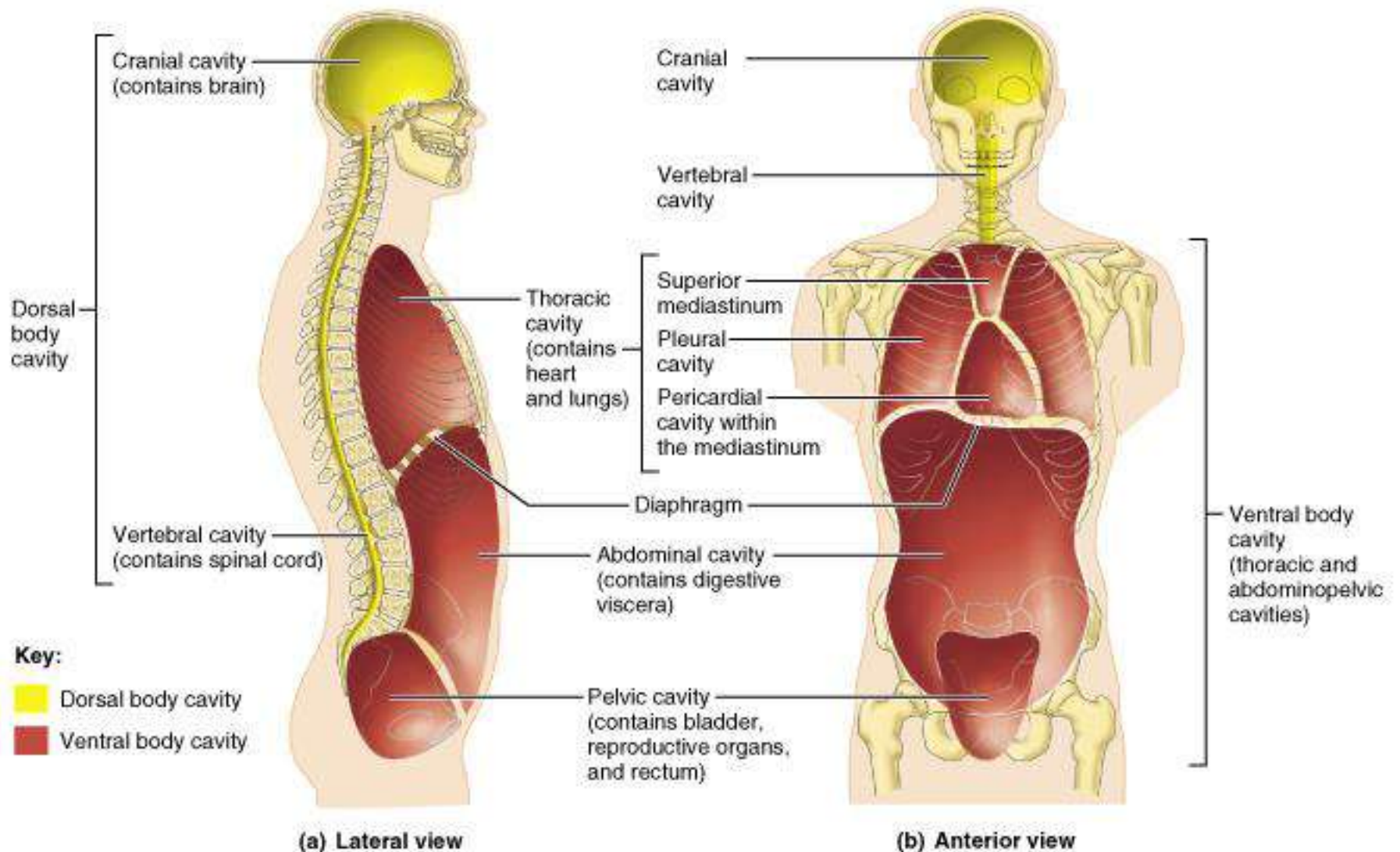
dr. Thontowi Djauhari NS M.Kes
Laboratorium Anatomi
Fakultas Kedokteran
Univ. Muhammadiyah Malang



Sine Anatomi Nihil Medicine

Tidak Ada Ilmu Kedokteran Tanpa Anatomi

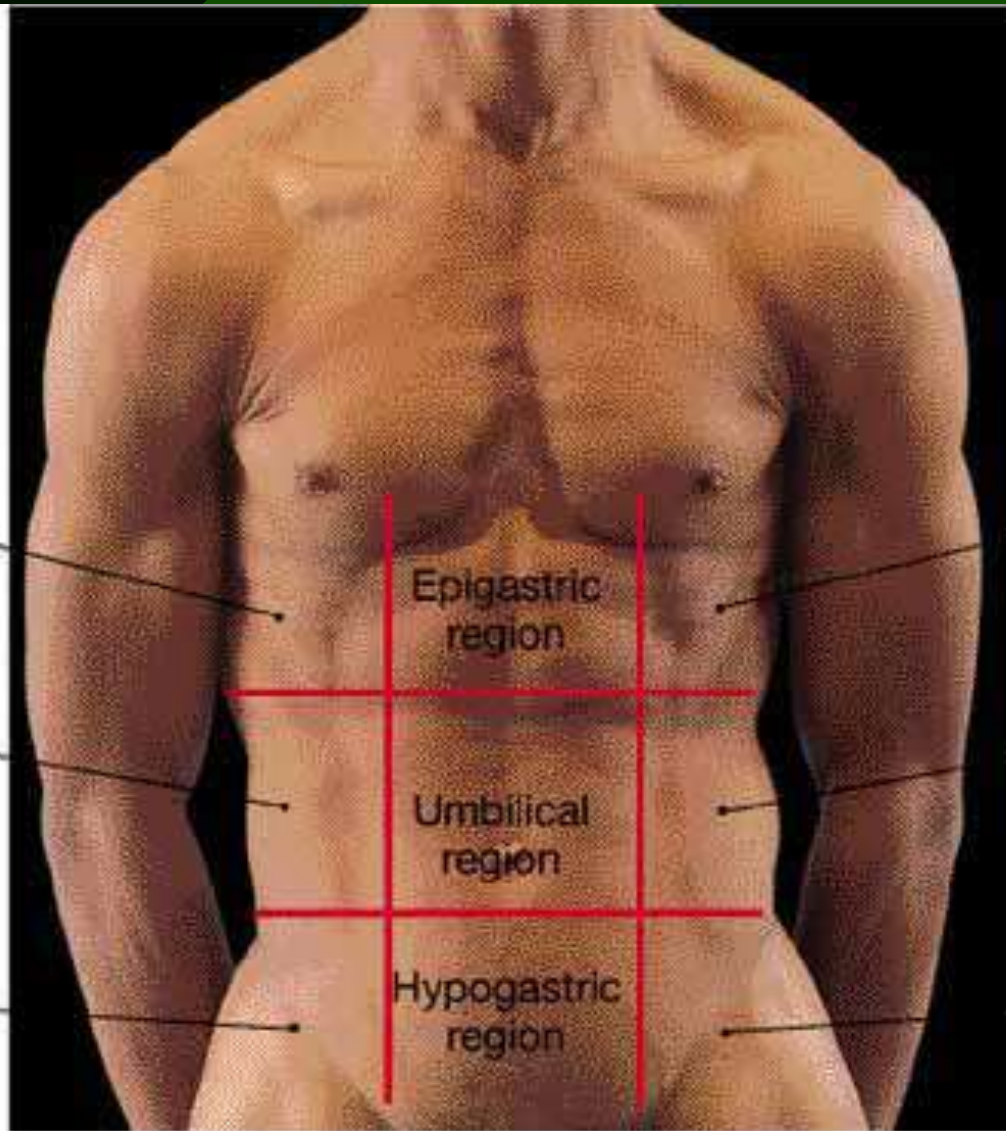




Right
hypochoondriac
region

Right
lumbar
region

Right
inguinal
region

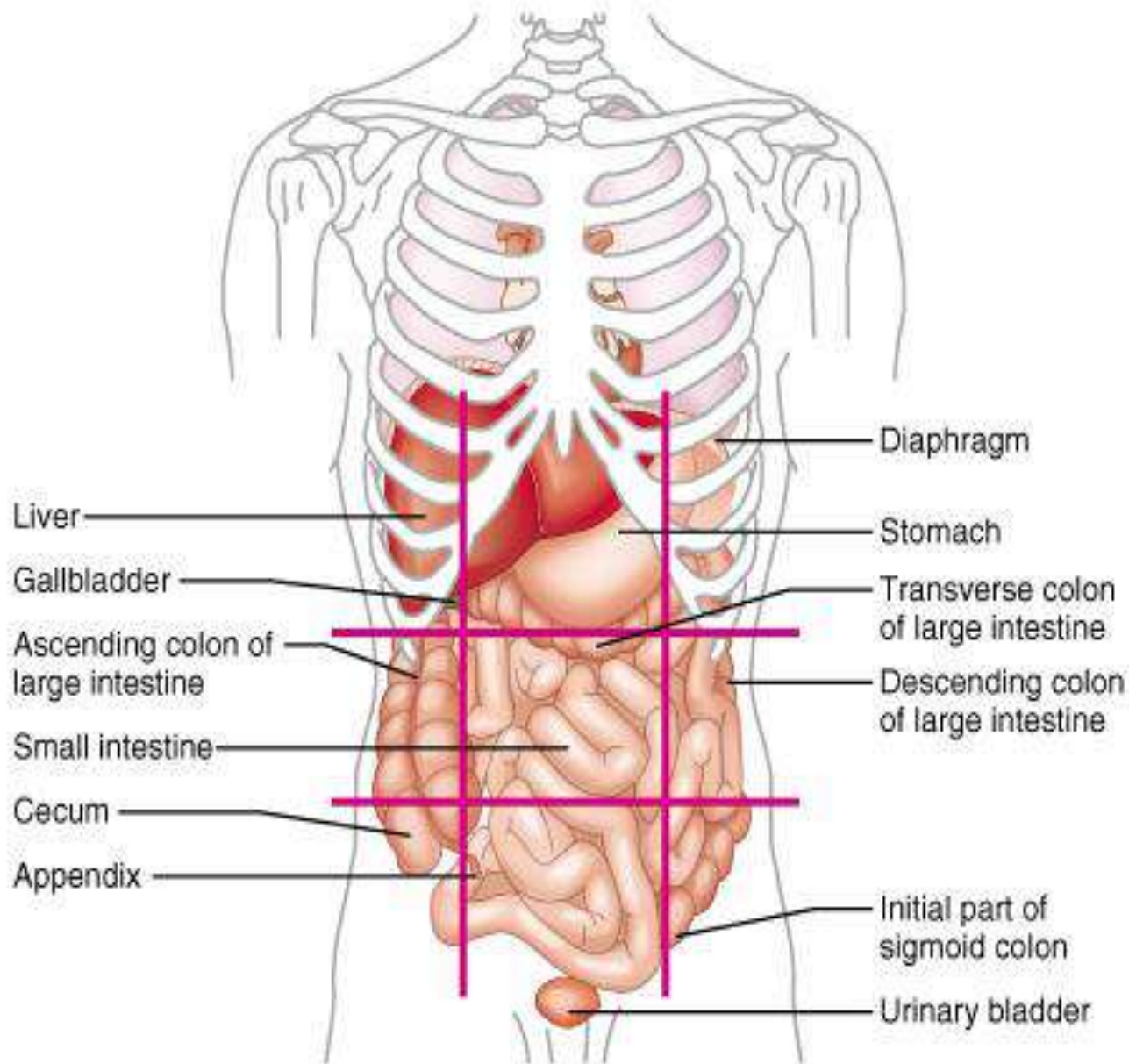


Left
hypochoondriac
region

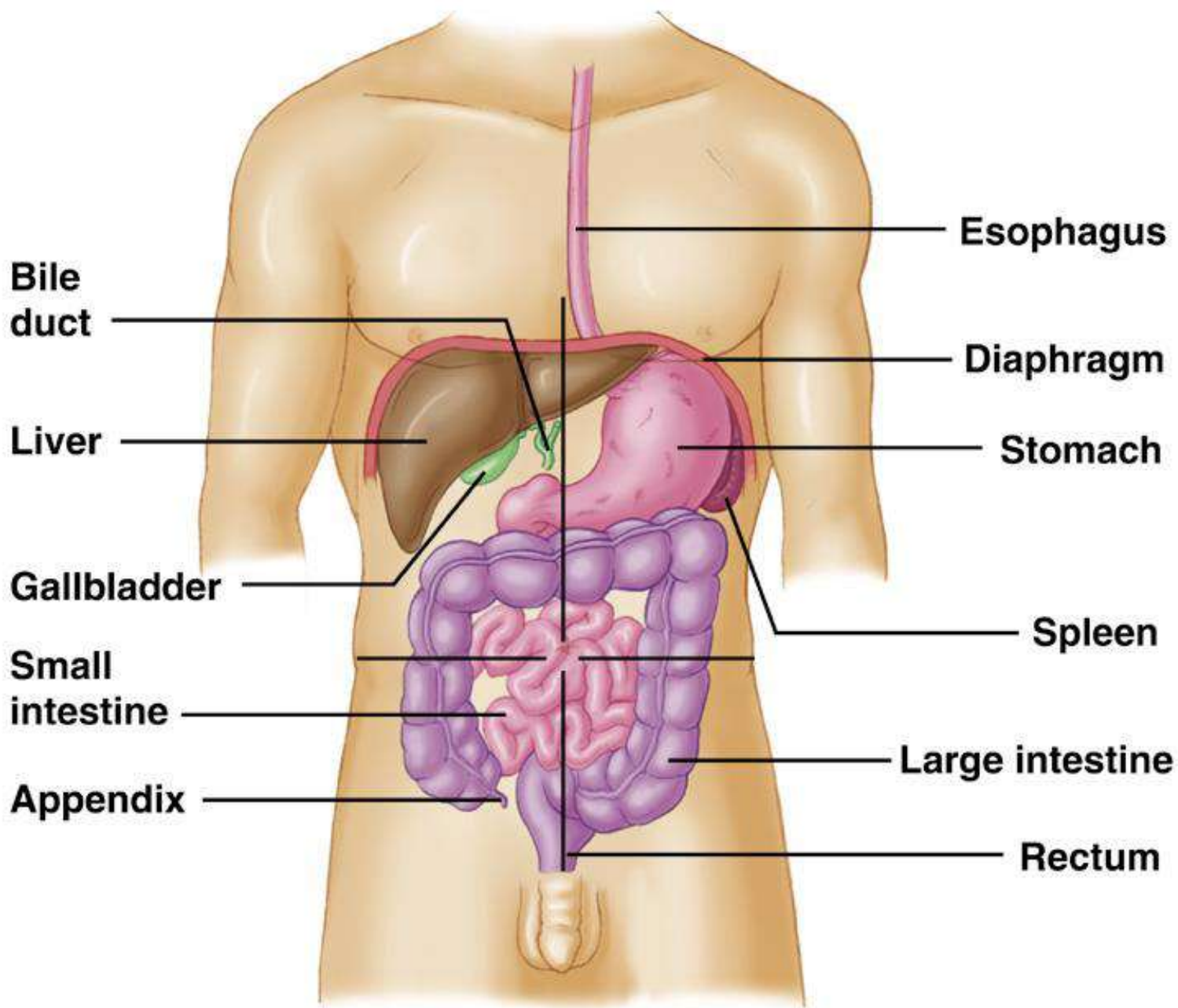
Left
lumbar
region

Left
inguinal
region

(b)



(b)



Bile duct

Liver

Gallbladder

Small intestine

Appendix

Esophagus

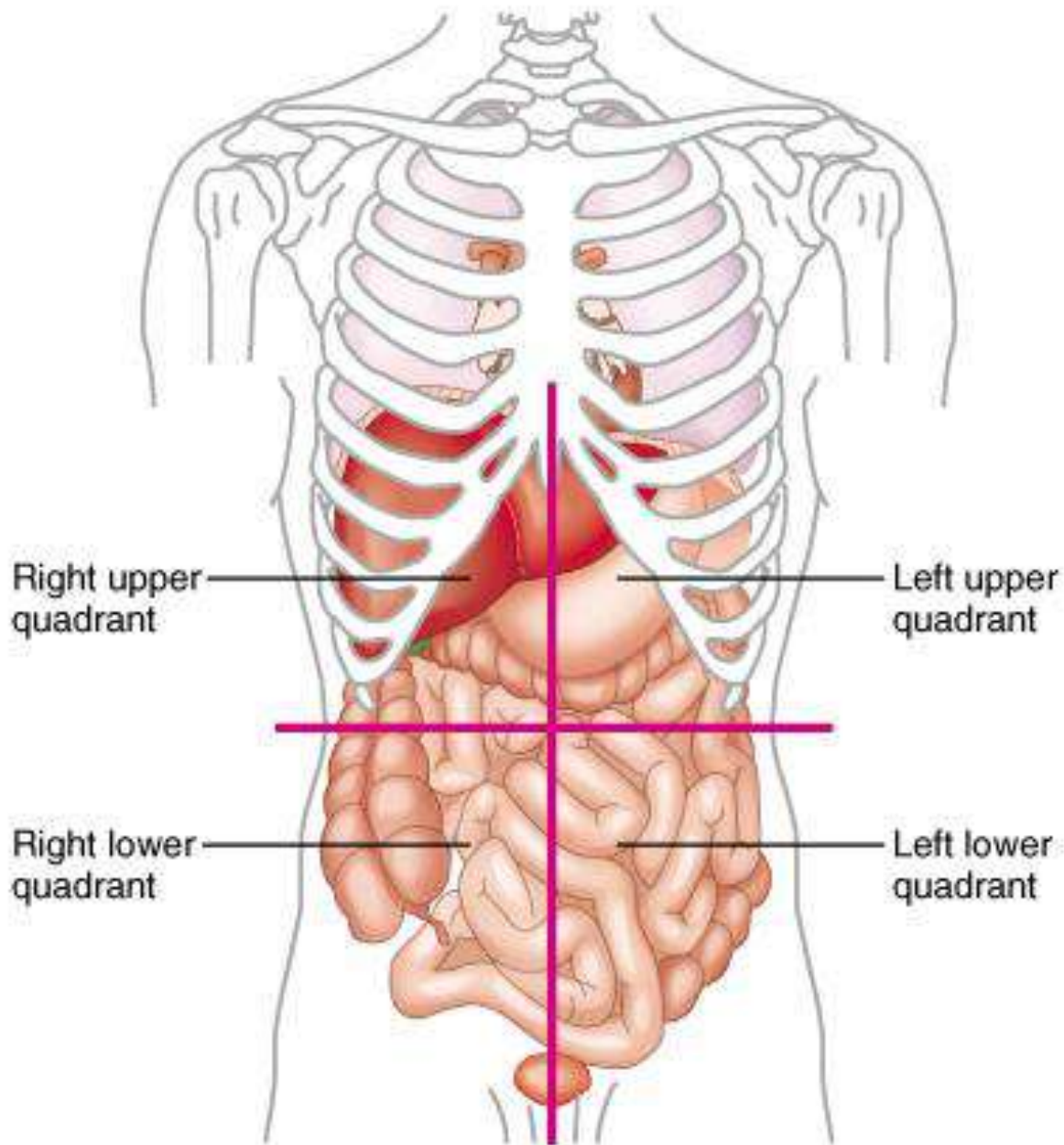
Diaphragm

Stomach

Spleen

Large intestine

Rectum

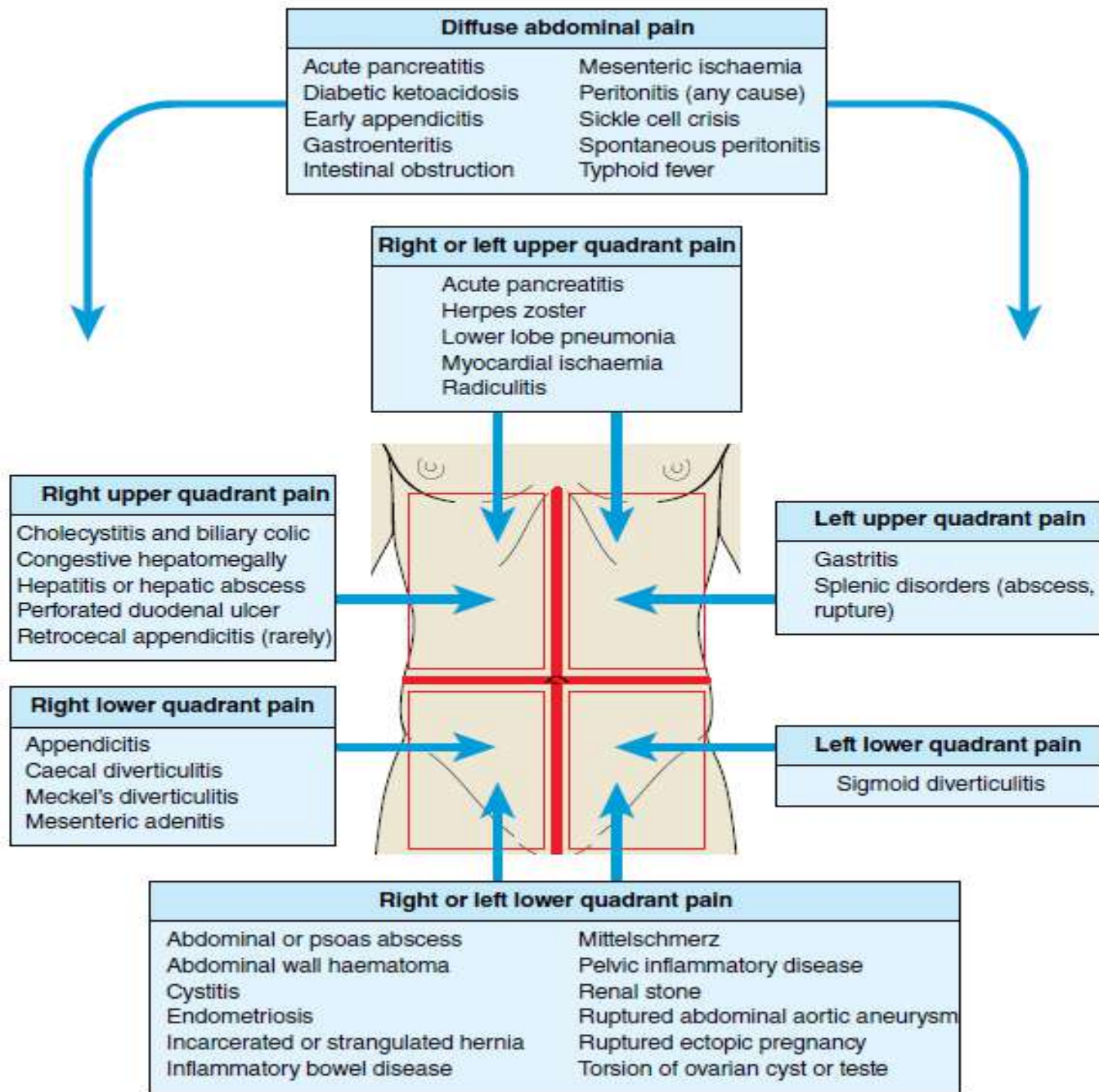


Right upper quadrant

Left upper quadrant

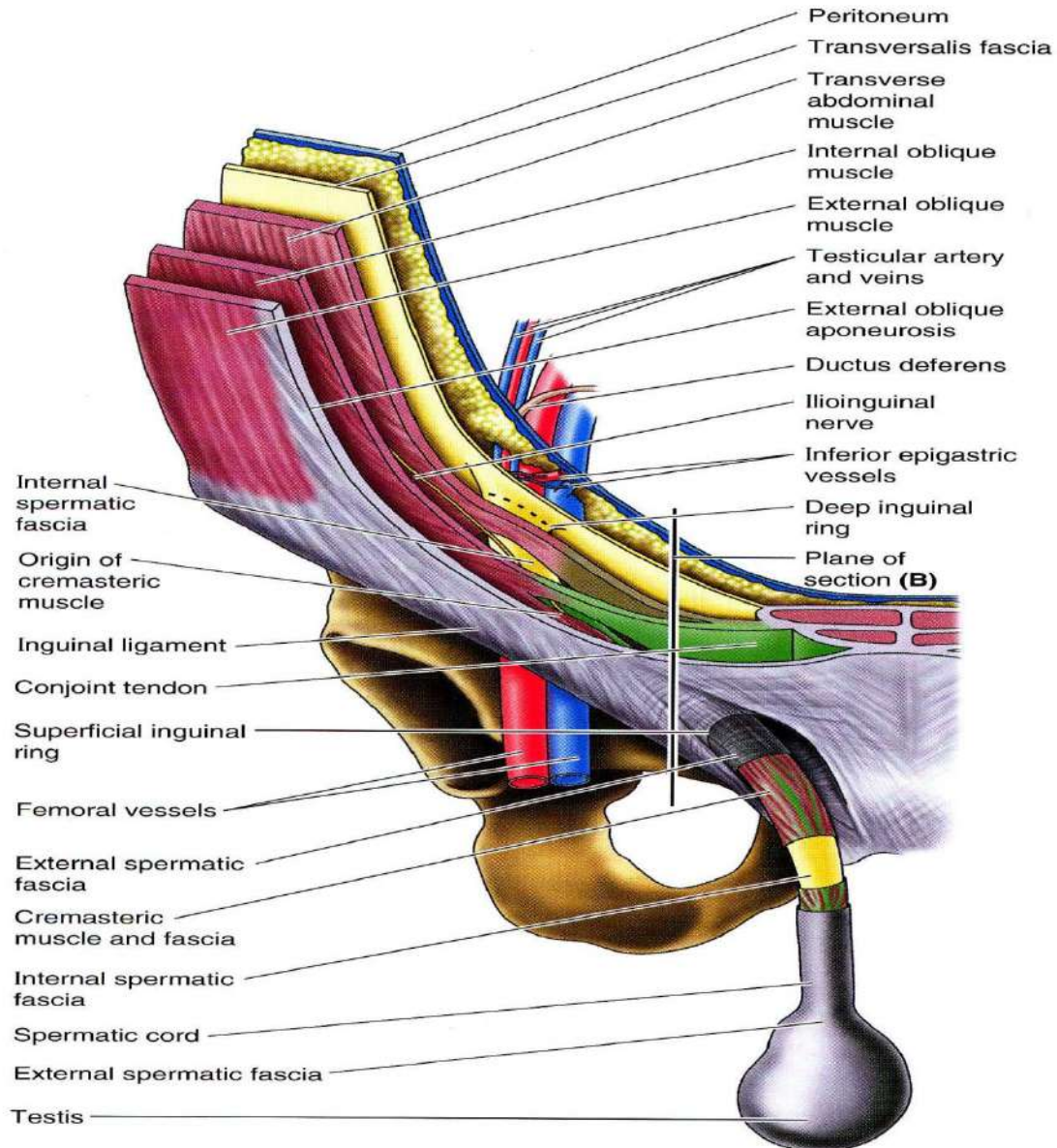
Right lower quadrant

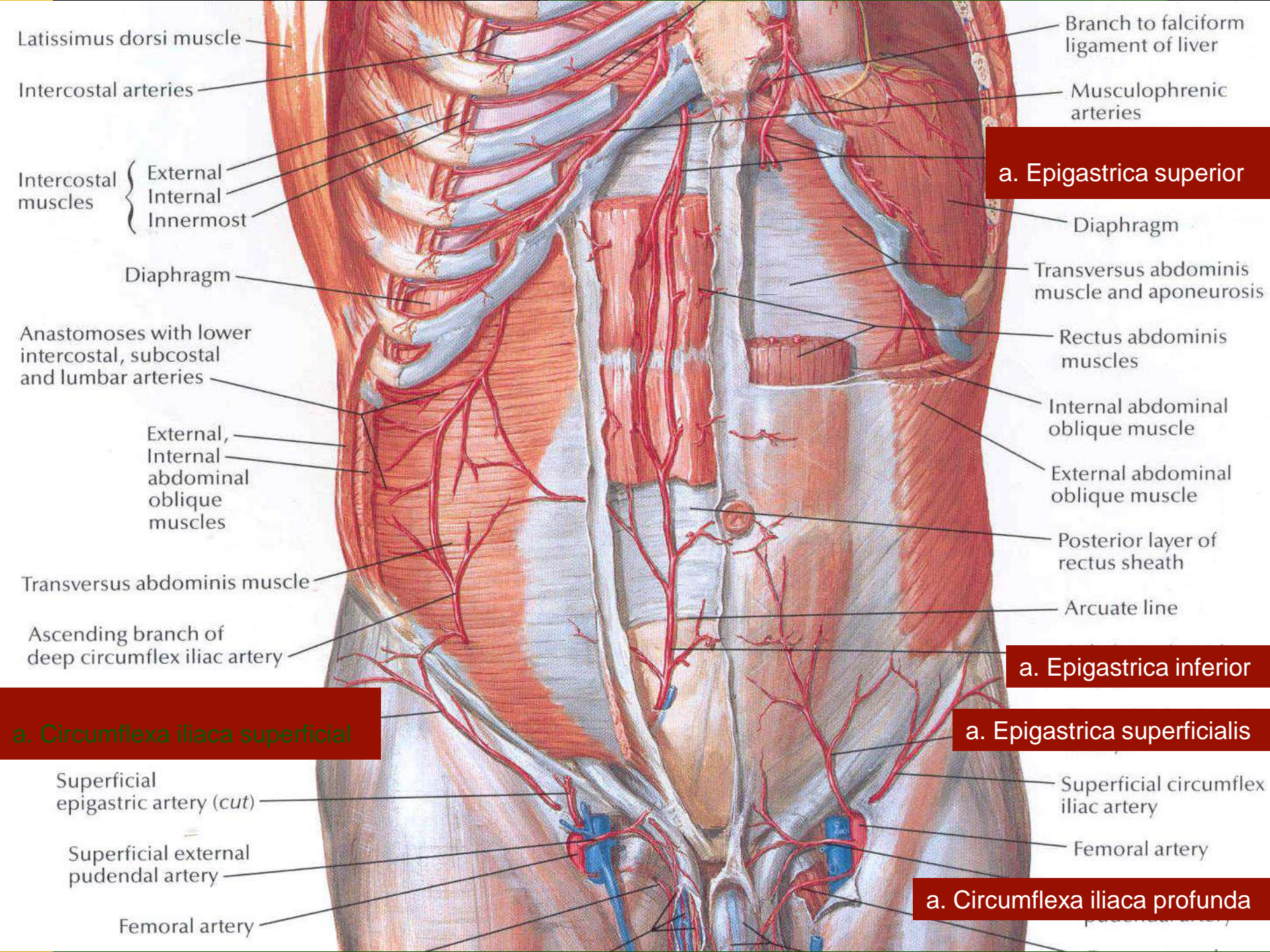
Left lower quadrant



Dinding Ventral Abdomen

- Kutan
- Subkutan → **Fascia abdominis superficialis**
- Otot & fascianya :
 - M. obliquus abdominis externus**
 - M. obliquus abdominis internus**
 - M. Transversus abdominis**
 - M. Rectus abdominis**
- Fascia Transversalis
- Peritoneum Parietalis





Latissimus dorsi muscle

Intercostal arteries

Intercostal muscles {
External
Internal
Innermost

Diaphragm

Anastomoses with lower
intercostal, subcostal
and lumbar arteries

External,
Internal
abdominal
oblique
muscles

Transversus abdominis muscle

Ascending branch of
deep circumflex iliac artery

a. Circumflexa iliaca superficialis

Superficial
epigastric artery (*cut*)

Superficial external
pudendal artery

Femoral artery

Branch to falciform
ligament of liver

Musculophrenic
arteries

a. Epigastrica superior

Diaphragm

Transversus abdominis
muscle and aponeurosis

Rectus abdominis
muscles

Internal abdominal
oblique muscle

External abdominal
oblique muscle

Posterior layer of
rectus sheath

Arcuate line

a. Epigastrica inferior

a. Epigastrica superficialis

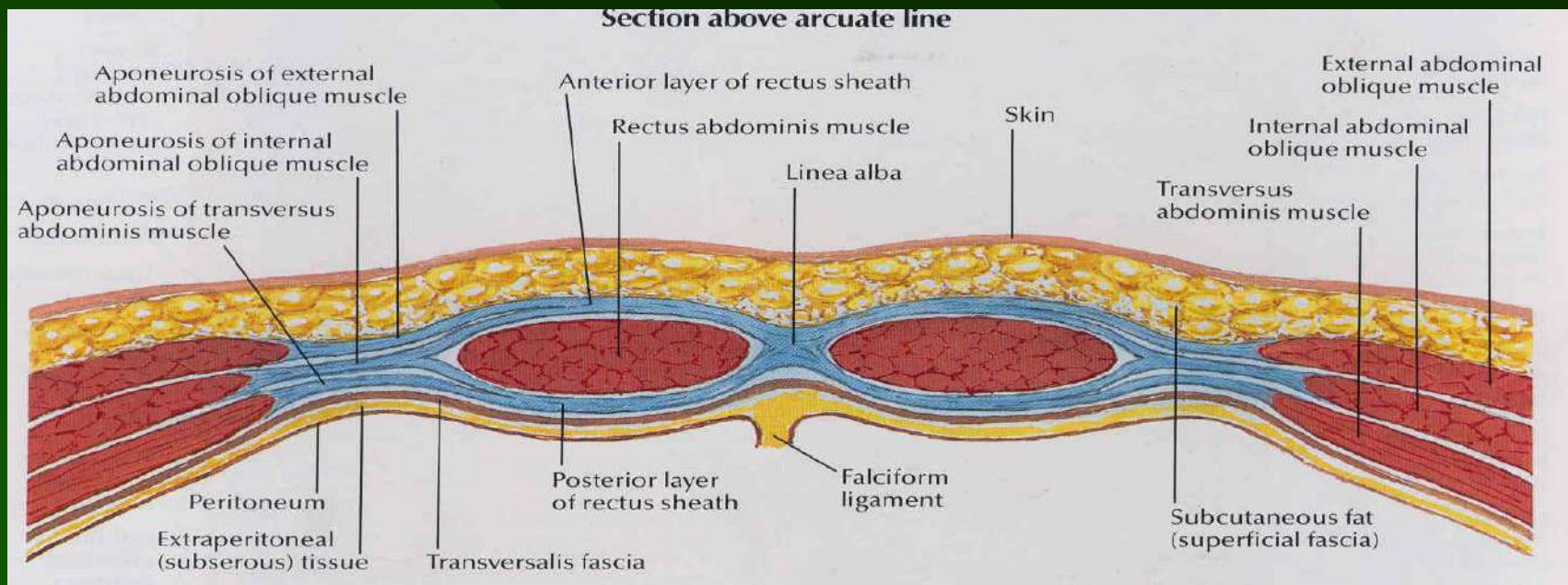
Superficial circumflex
iliac artery

Femoral artery

a. Circumflexa iliaca profunda

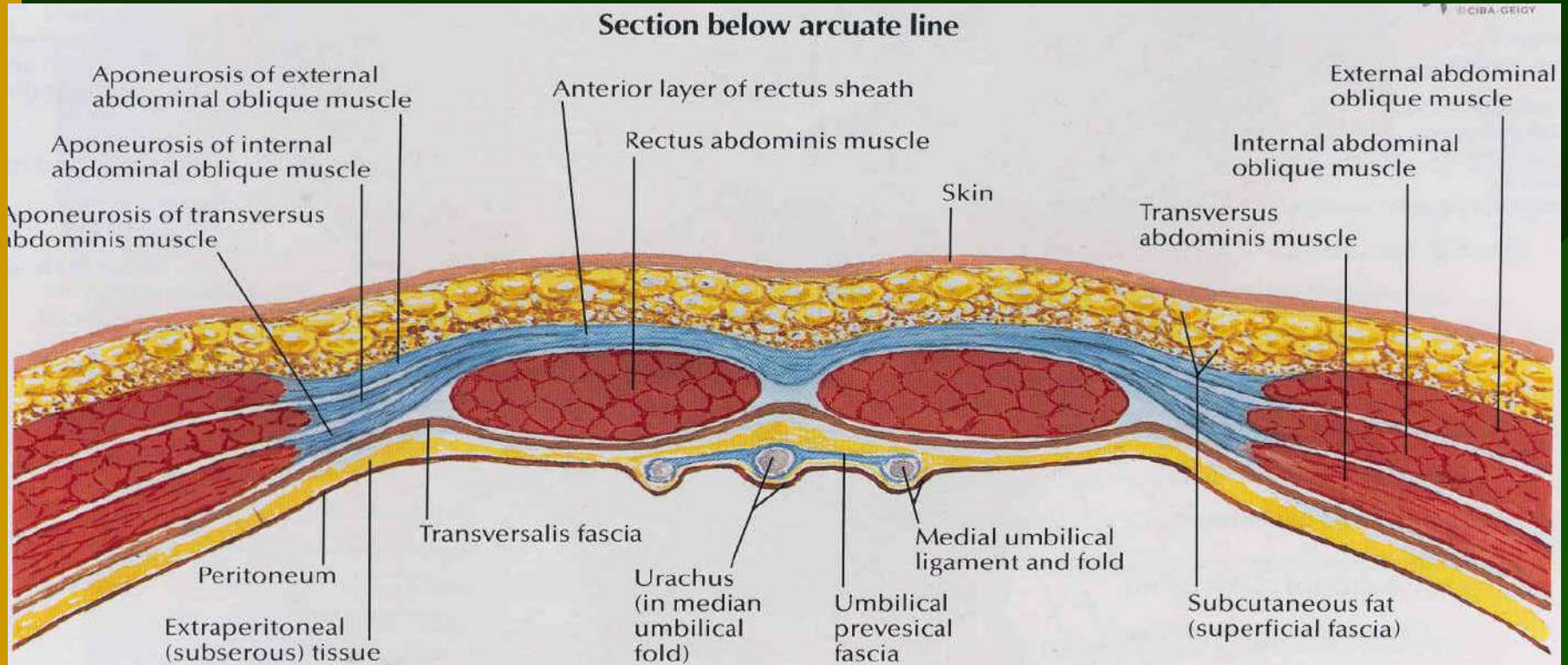
Struktur Khusus Dinding Abdomen

- **Linea alba** → garis o.k. pertemuan aponeurosis otot-2 dinding abdomen
- **Sarung Rectus (Vagina m.recti abdominis)** → Kumpulan aponeurosis yang membungkus M. rectus abdominis :
 - **diatas umbilicus :**
 - diatas m. rectus : lamina anterior : Fascia m.o.a.e & Fascia m.o.a.i
 - dibawah m. rectus : lamina posterior : Fascia m.o.a.l & Fascia m.transversus abdominis

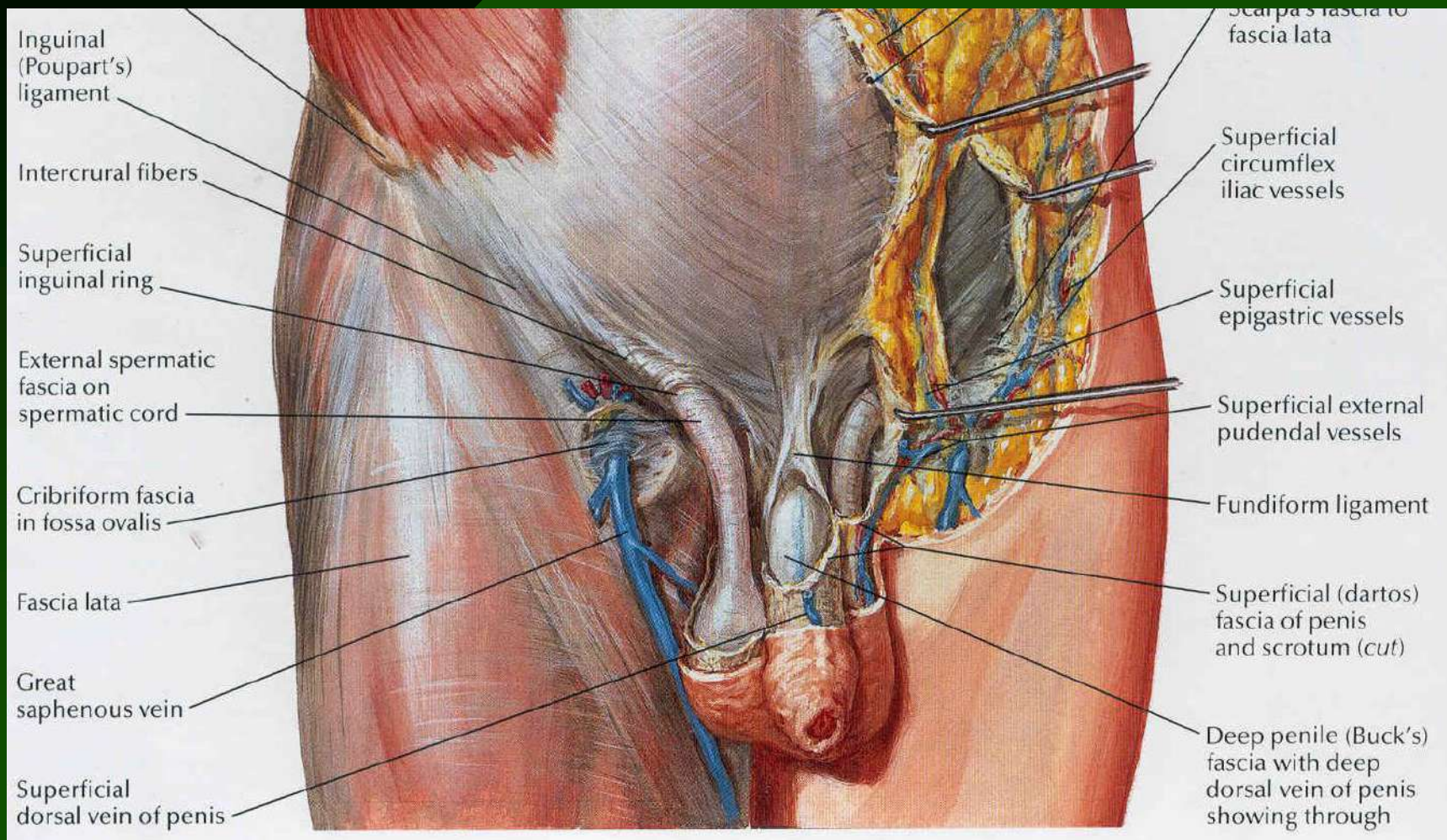


Struktur Khusus Dinding Abdomen

- **dibawah umbilicus :**
 - diatas m. rectus : lamina anterior & posterior
 - dibawah m. rectus : Fascia transversalis

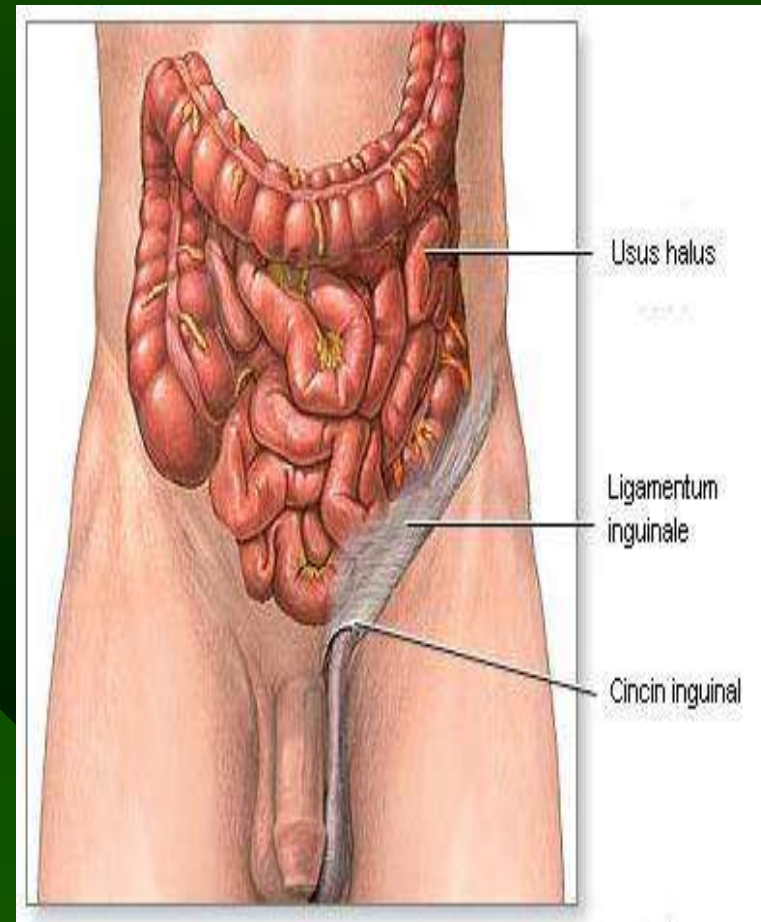
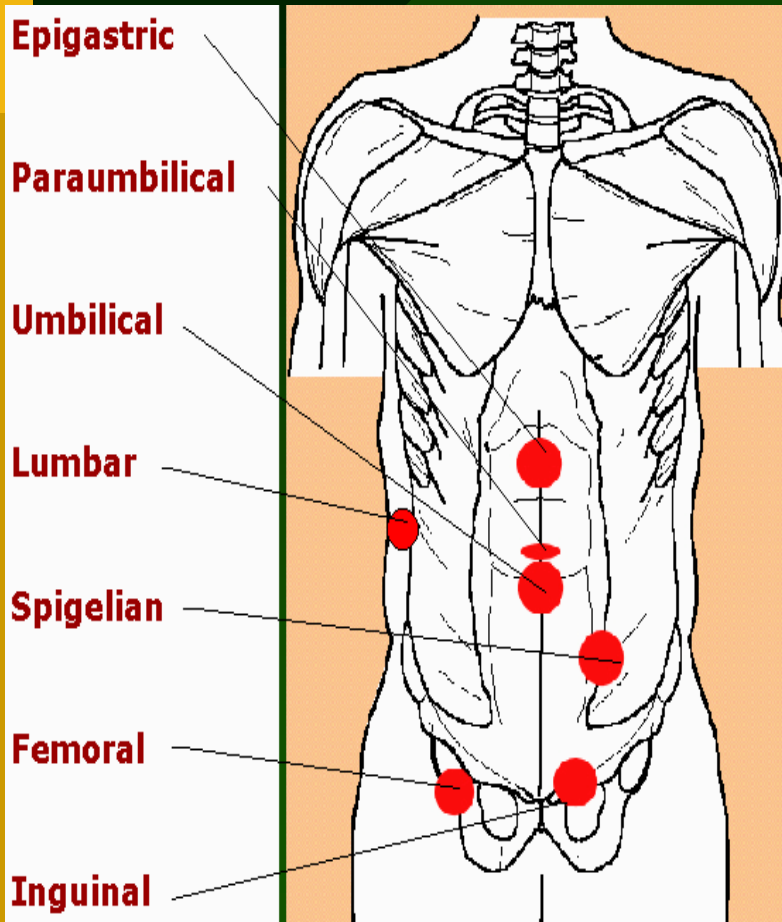


● Canalis inguinalis

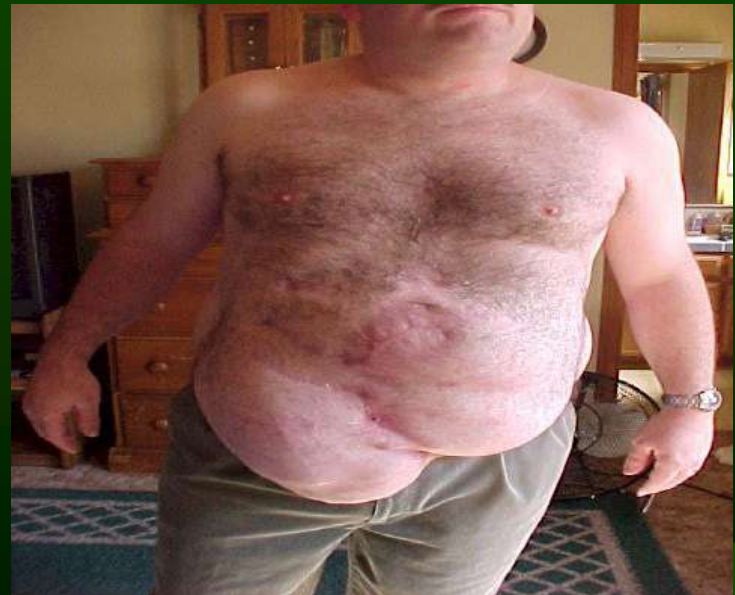
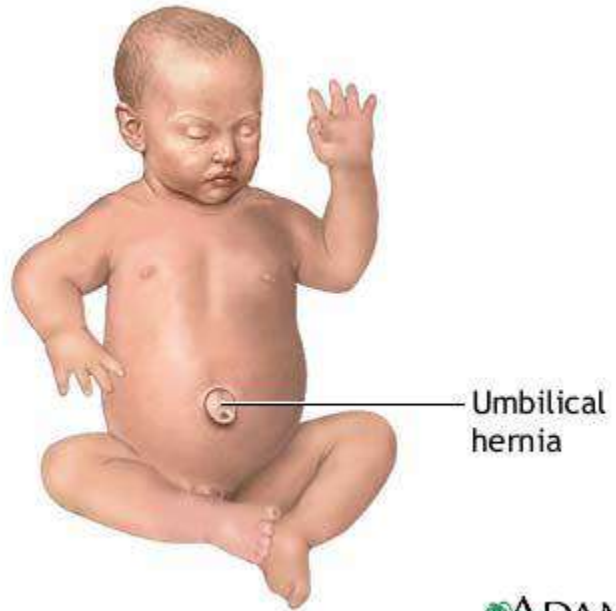
Merupakan saluran yang berjalan melalui dinding abdomen anterolateral bagian bawah. Pada laki-laki dilalui oleh funiculus spermaticus dan N. ilioinguinalis. selanjutnya sebagai funiculus spermaticus. berjalan serong ke arah anterior, medial dan inferior. Lalu keluar melalui anulus inguinalis subcutaneus (external) yang berbentuk seperti segitiga pada aponeurosis. M. obliquus externus abdominis.

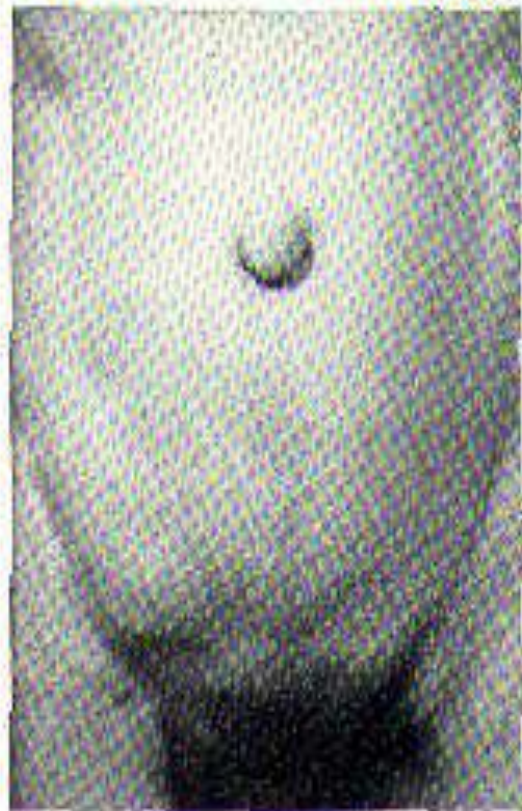
REGIO HERNIA



HERNIA UMBILICALIS



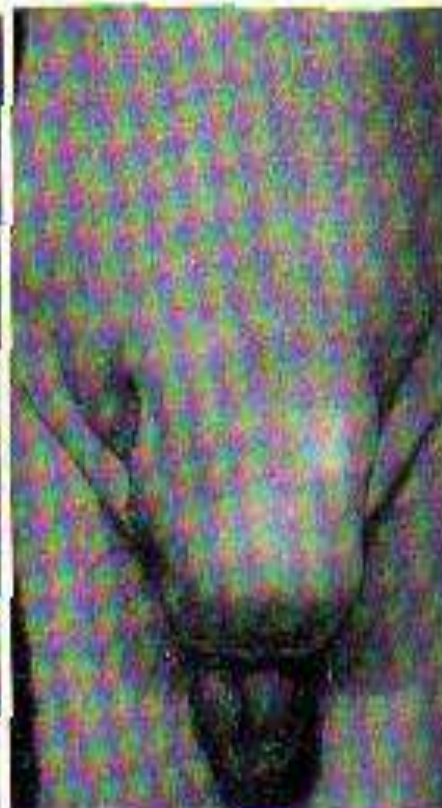Para umbilical hernia



Small.

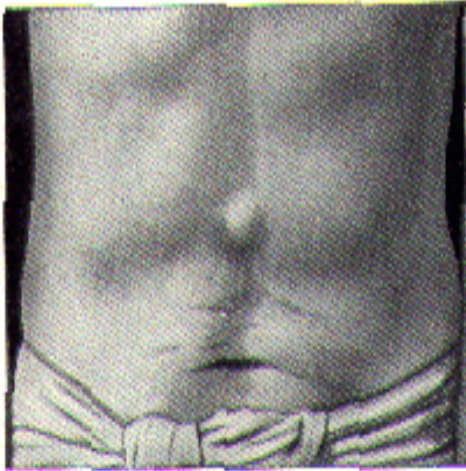


Large.

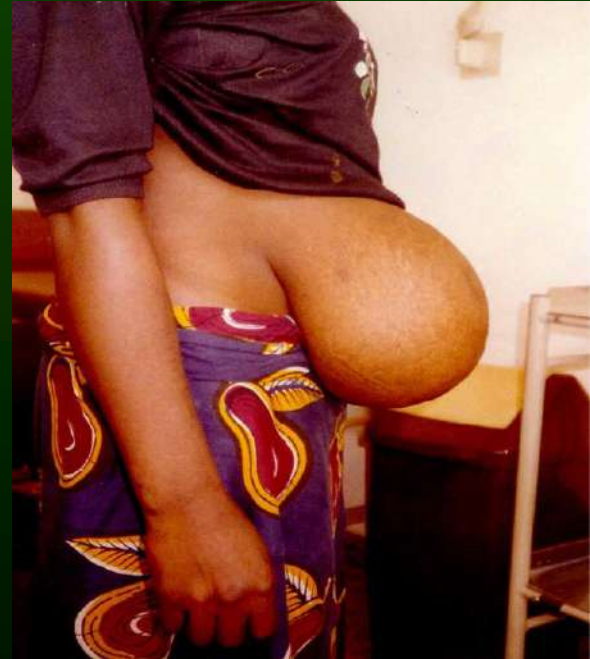

Very large.

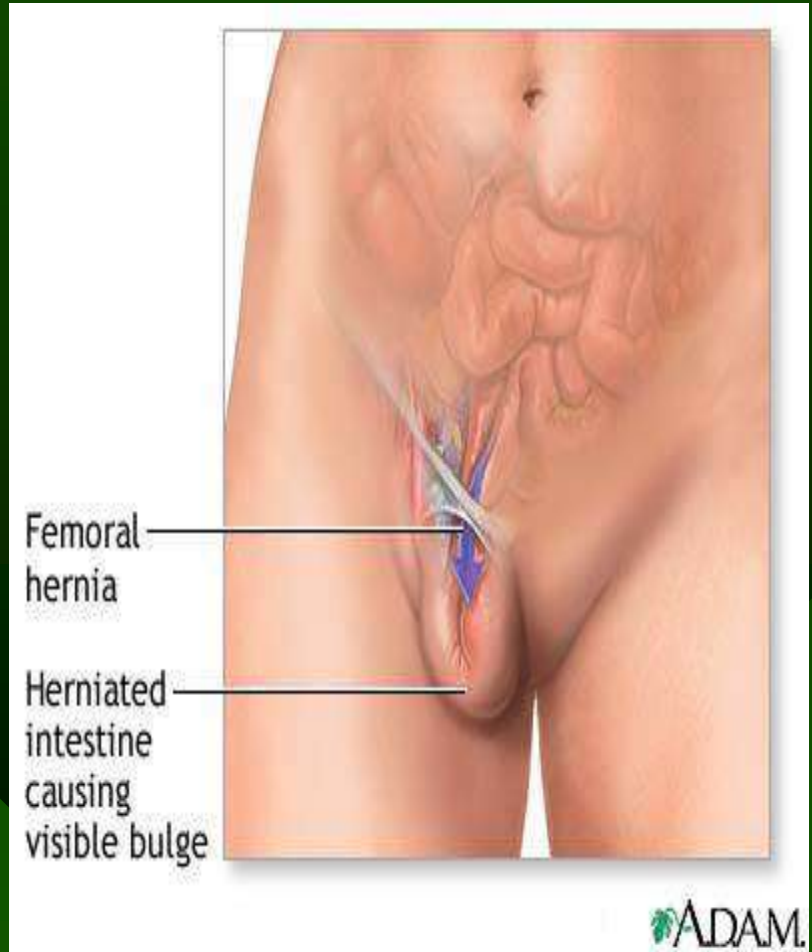
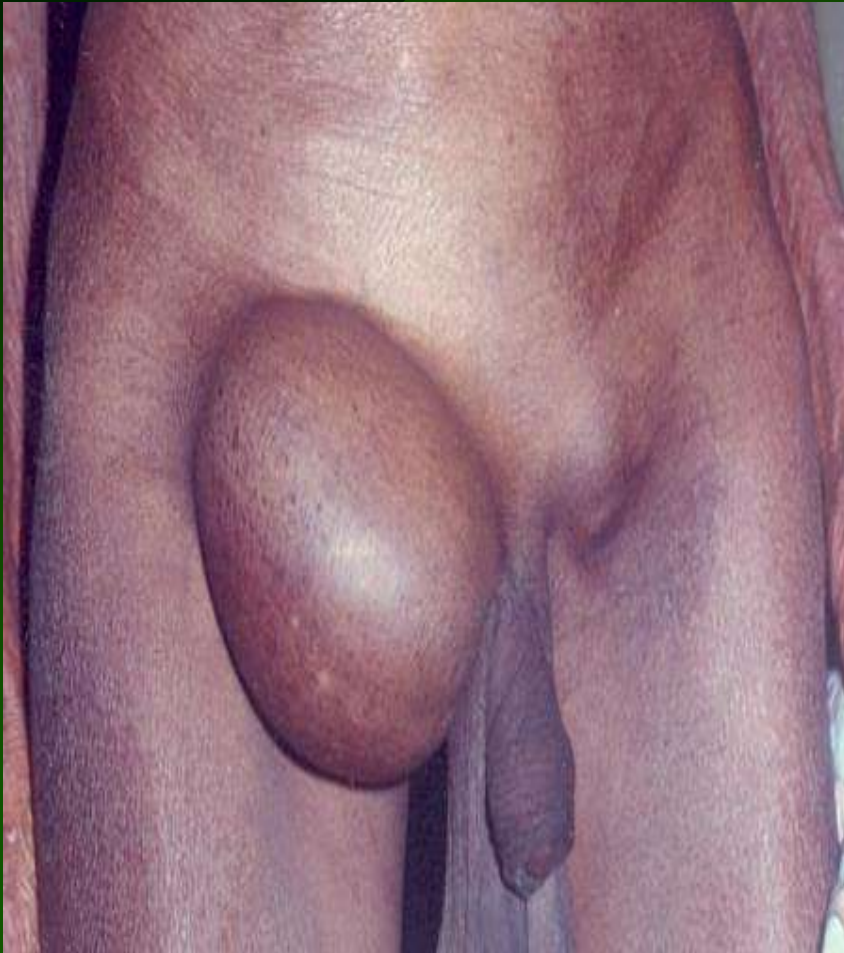HERNIA EPIGASTRIKA



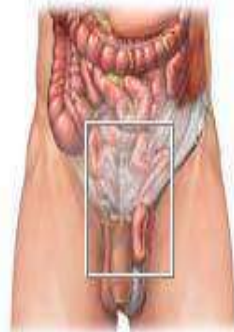
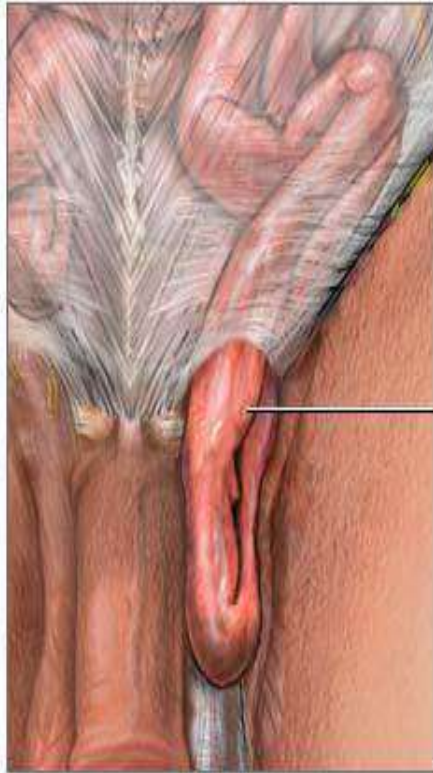
Epigastric hernia



HERNIA FEMORALIS

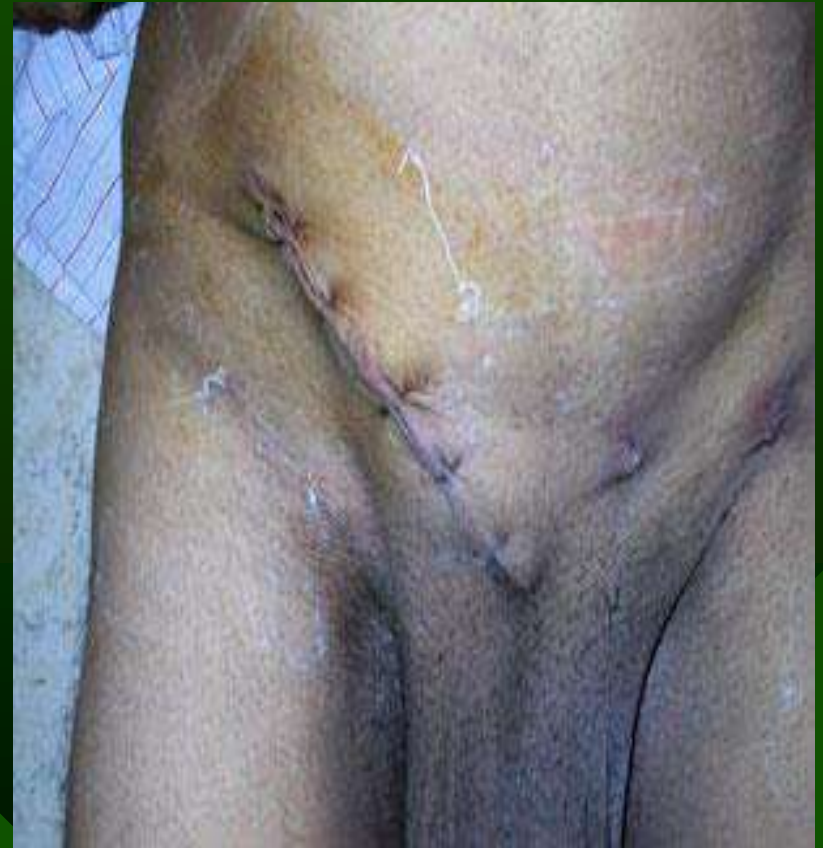

HERNIA INGUINAL



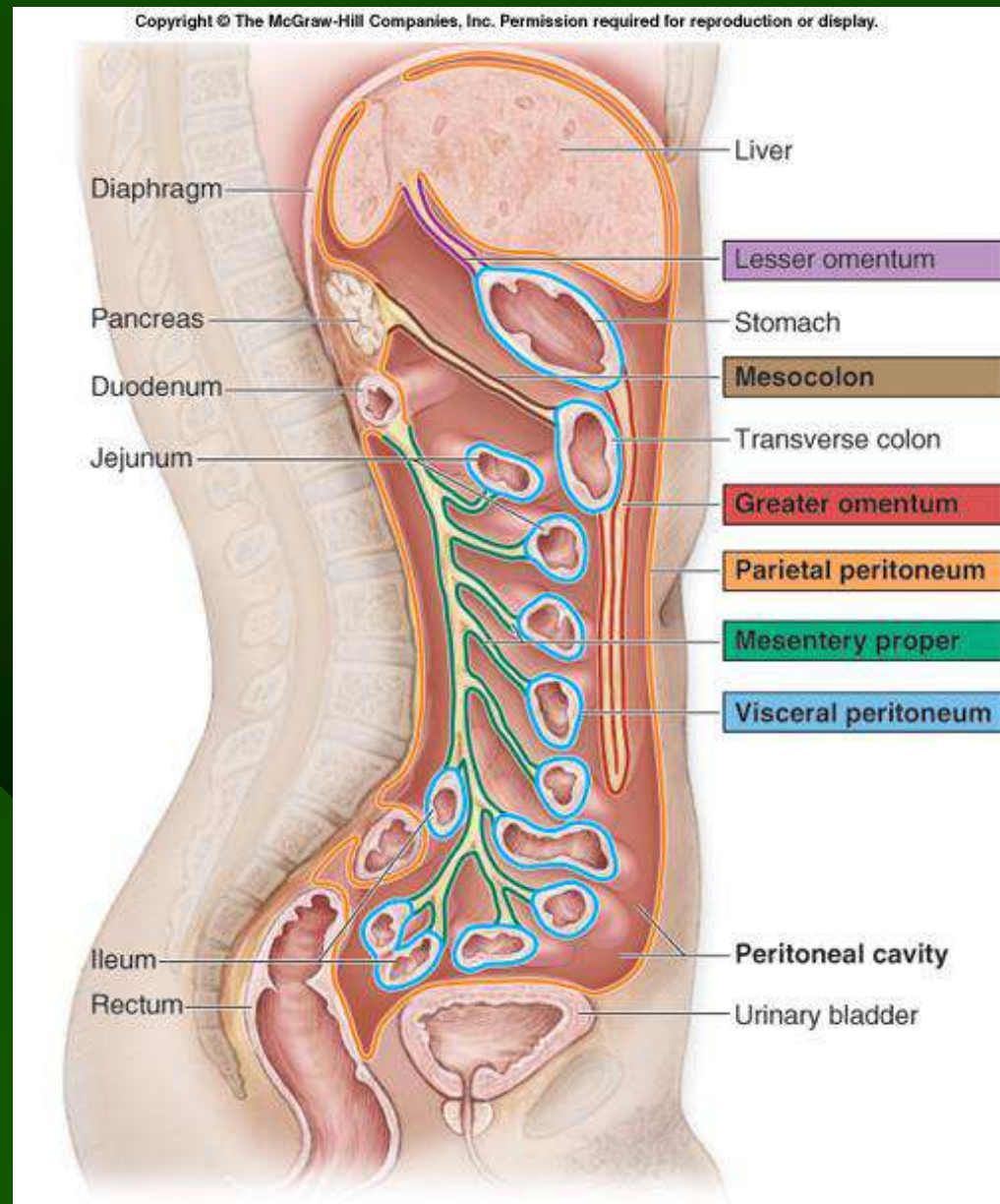
Hernia inguinalis

Hernia inguinalis terjadi jika sebagian dari usus kecil masuk ke dalam kanalis inguinalis



PERITONEUM DAN CAVITAS PERITONEAL

- Peritoneum :
suatu selaput serosa yang melapisi dinding cavum abdomen dari sebelah dalam terdiri dari dua lembar yaitu peritoneum parietal dan viscerale.
- Peritoneum yang langsung melekat pada dinding abdomen disebut peritoneum parietale
- peritoneum yang menutupi organ-organ disebut peritoneum viscerale



Organ intra dan extra peritoneal

- bila organ tersebut hanya sebagian saja (kurang dari setengah) yang dilekati oleh peritoneum maka organ ini disebut organ retro/extraperitoneal
- Sebaliknya organ yang keseluruhannya atau hampir seluruhnya (lebih dari setengah bagian) dibungkus oleh peritoneum disebut organ intra peritoneal.

intra peritoneal	extra peritoneal
Gaster Trias porta Lien	Ren, Pancreas, Colon ascendens, Colon descendens, Vena cava inferior, aorta

Omentum : lipatan dari peritoneum

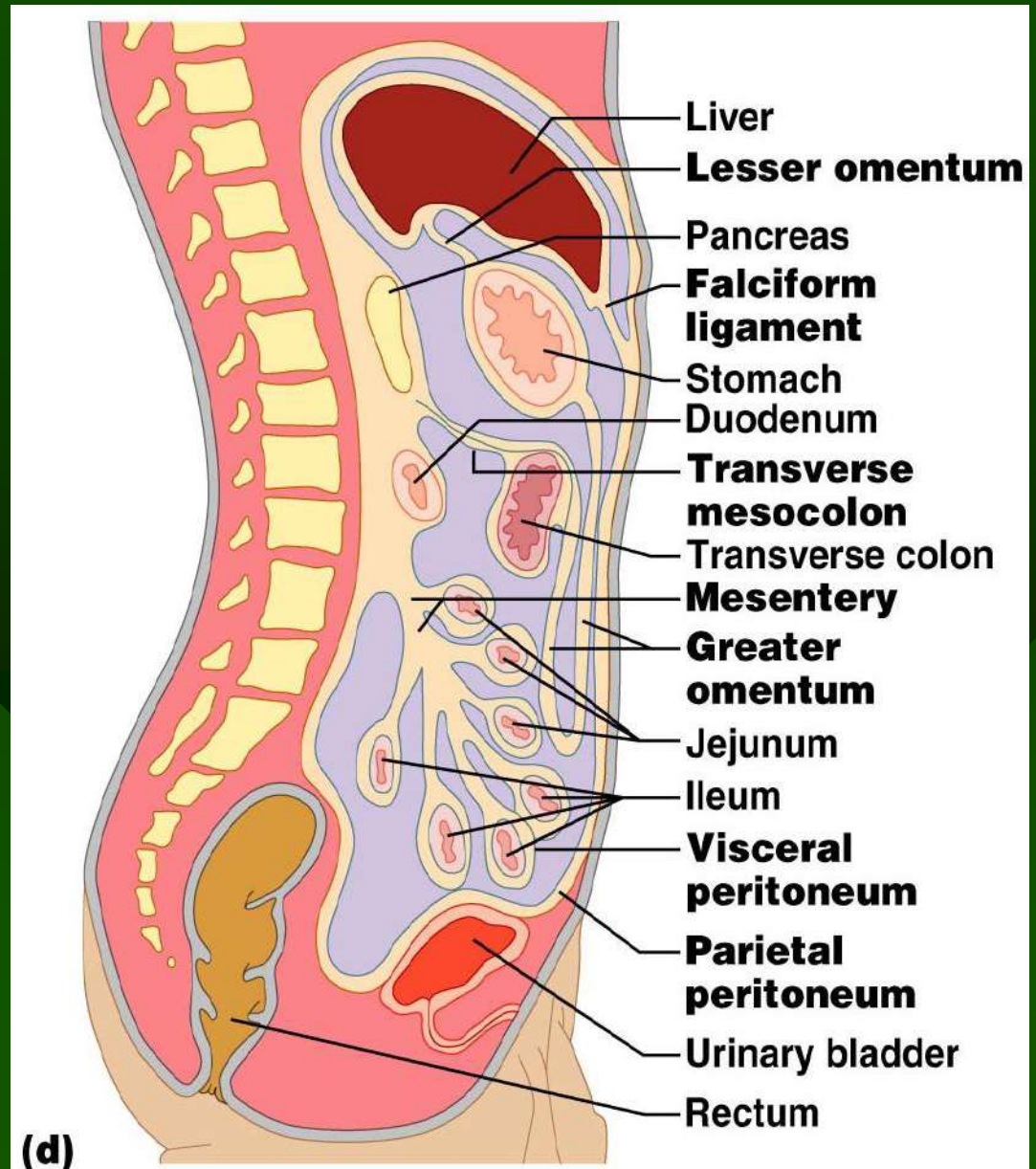
Omentum minus

2 lapis peritoneum visceralis antara curvatura minor gaster & hepar

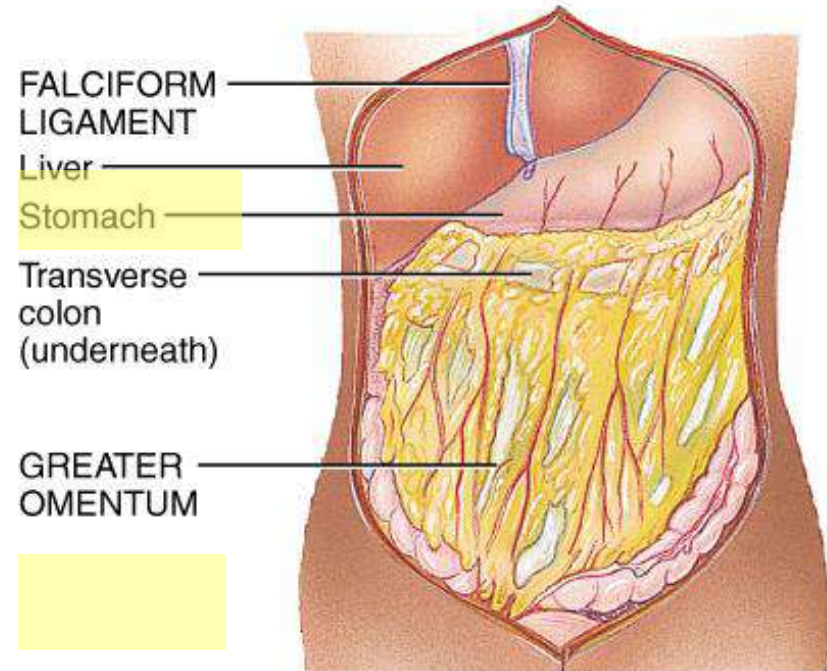
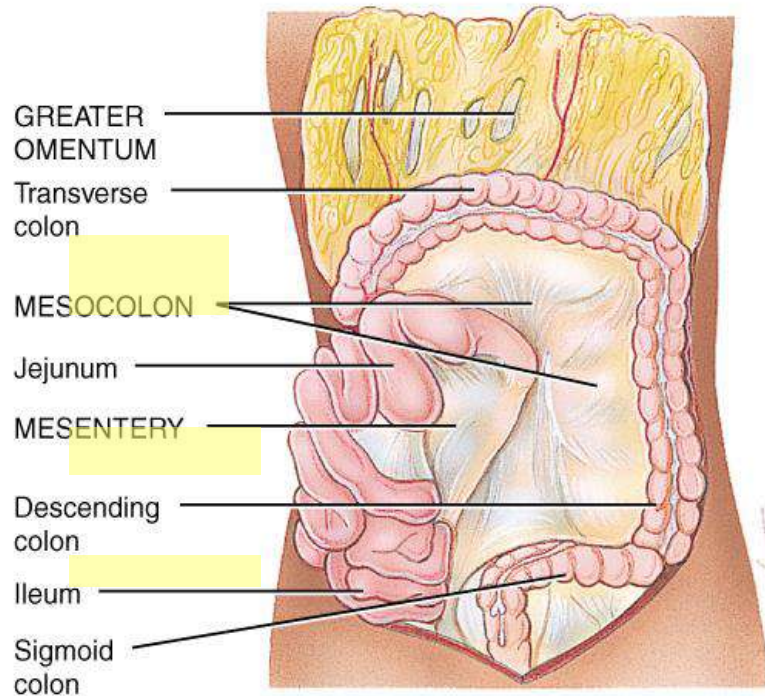
Omentum majus

4 lapis peritoneum visceralis dari curvatura major ke distal

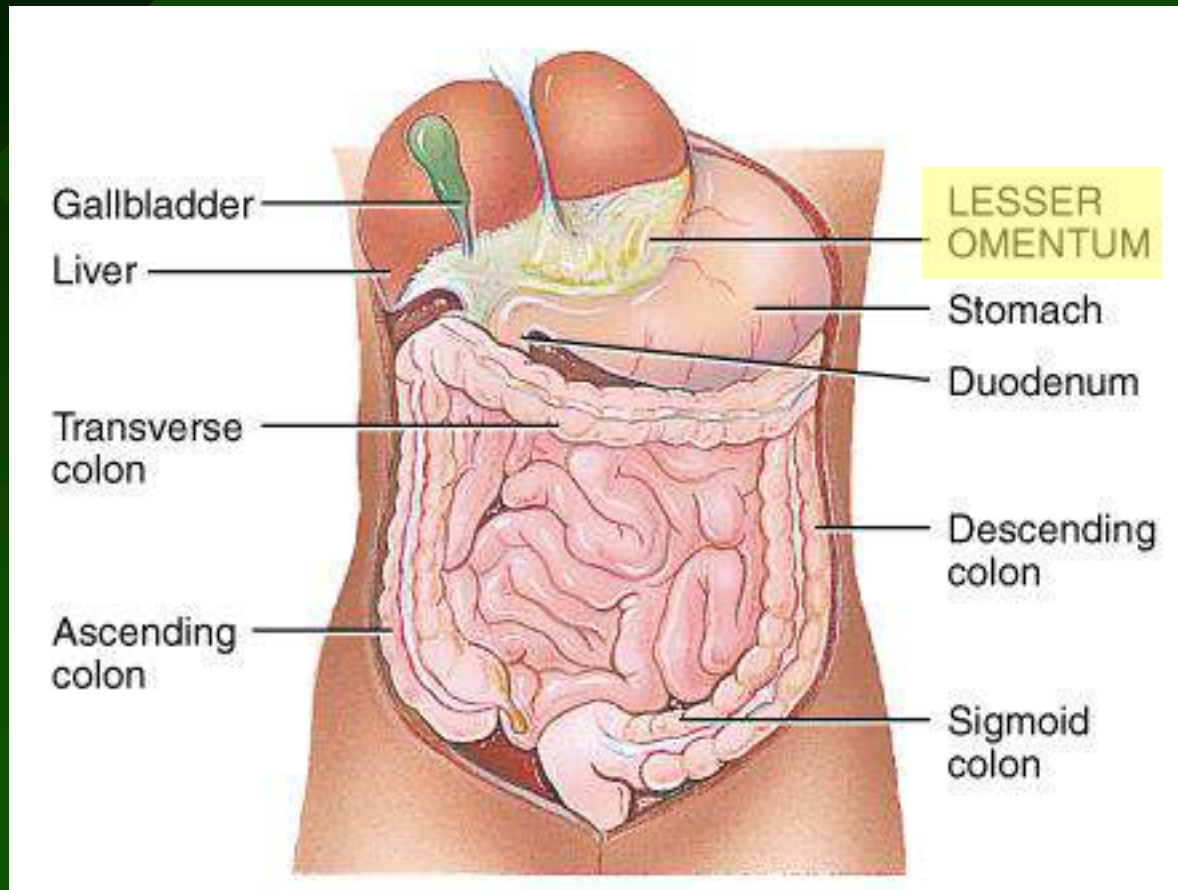
Biasa berisi jaringan lemak untk melokalisir infeksi



Omentum Mayus



Omentum Minus



Abdomen dan Alat-alat Dalam

Accessory Digestive Organs

**Gastrointestinal Tract
(Digestive Organs)**

- Parotid salivary gland
- Teeth
- Tongue
- Sublingual salivary gland
- Submandibular salivary gland

- Oral cavity
- Pharynx

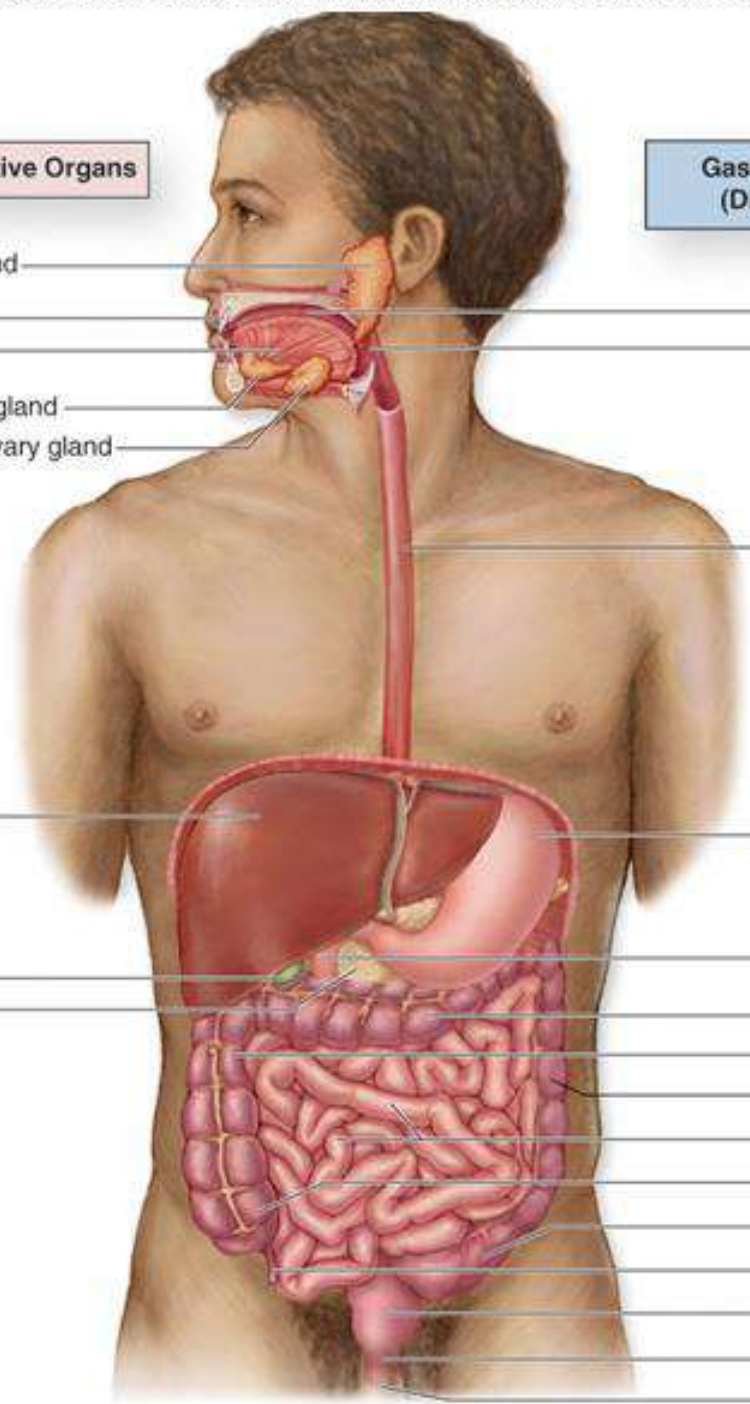
- Esophagus

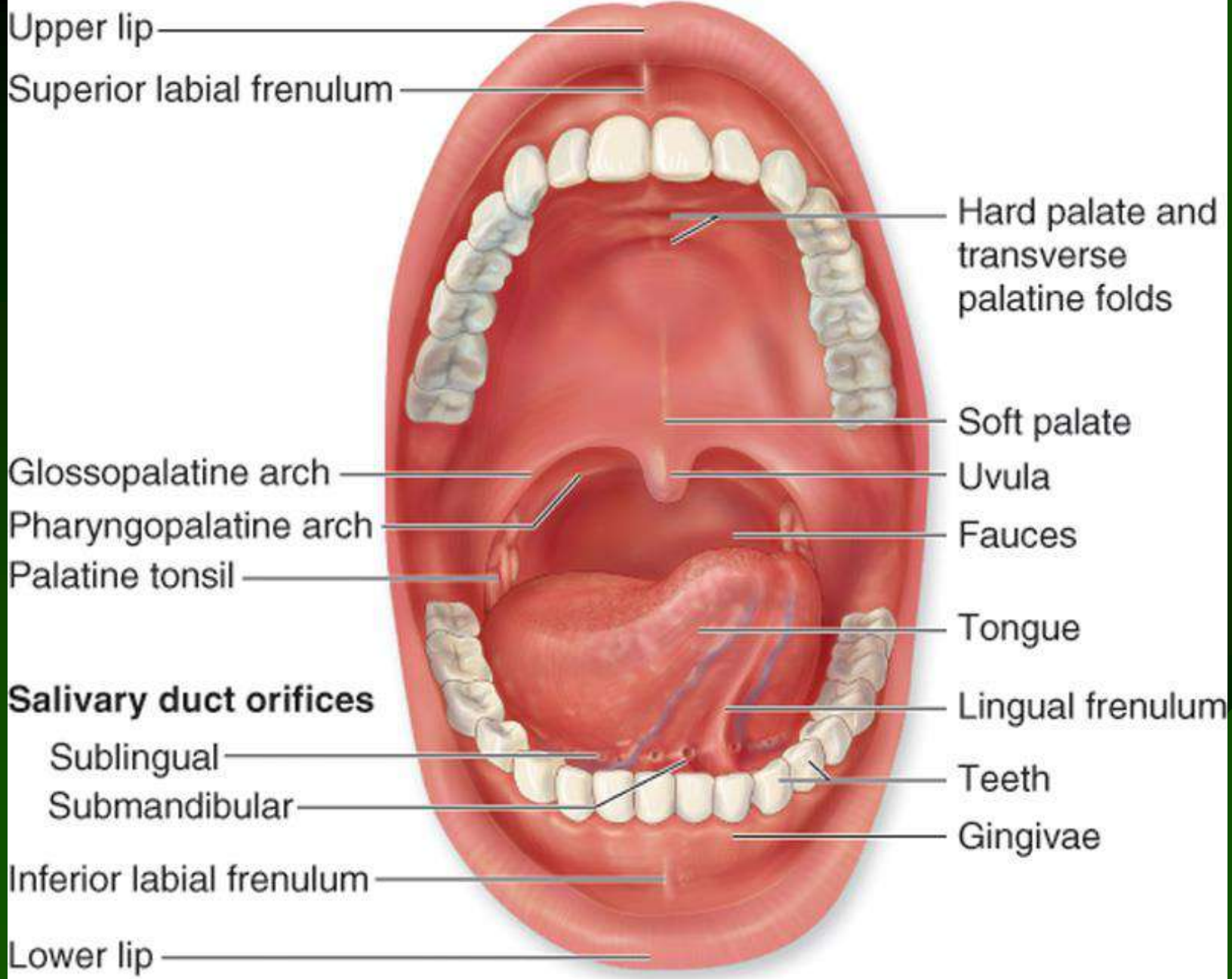
- Liver

- Stomach

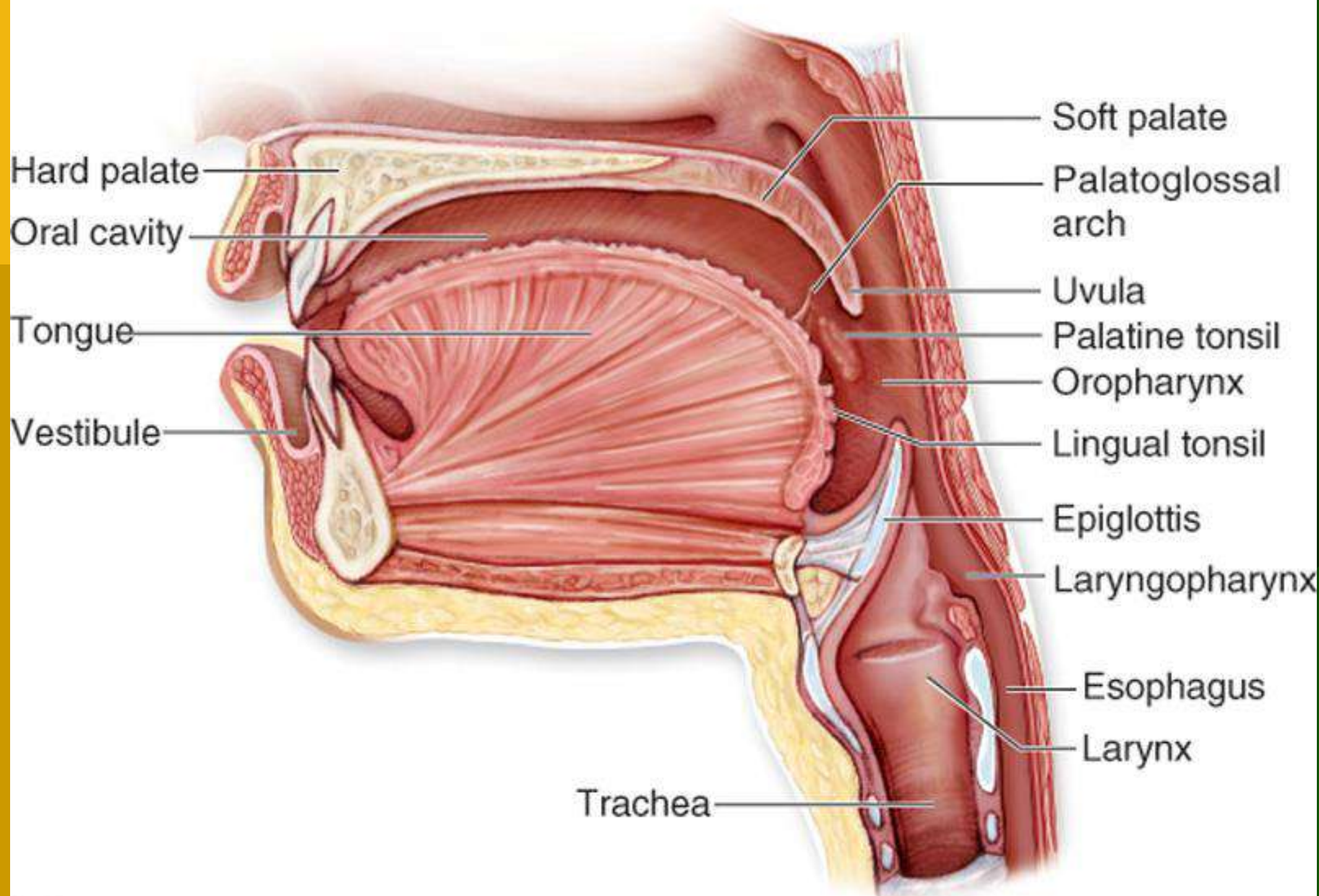
- Gallbladder
- Pancreas

- Duodenum
- Transverse colon
- Ascending colon
- Descending colon
- Small intestine
- Cecum
- Sigmoid colon
- Appendix
- Rectum
- Anal canal
- Anus

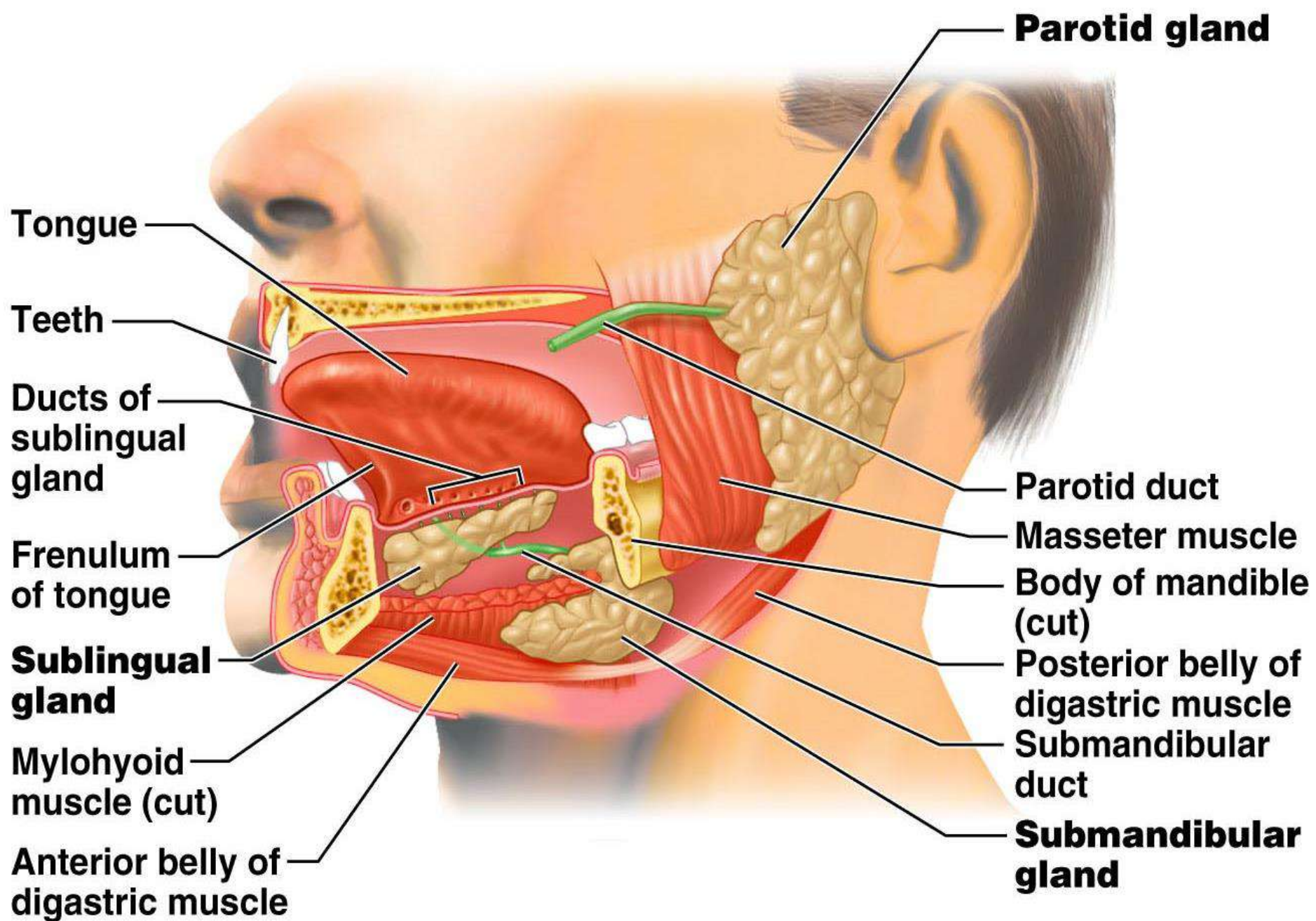




(a)

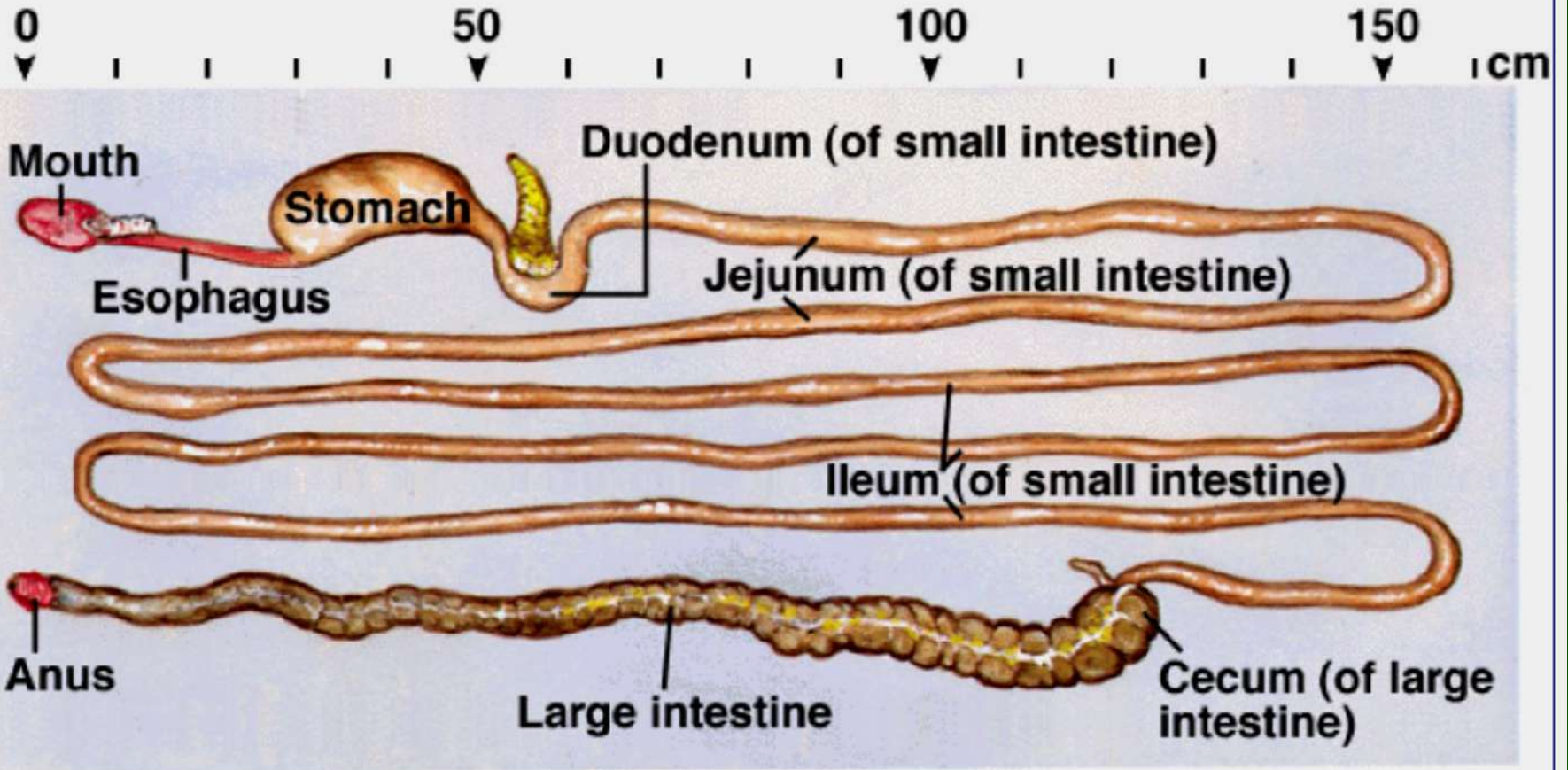


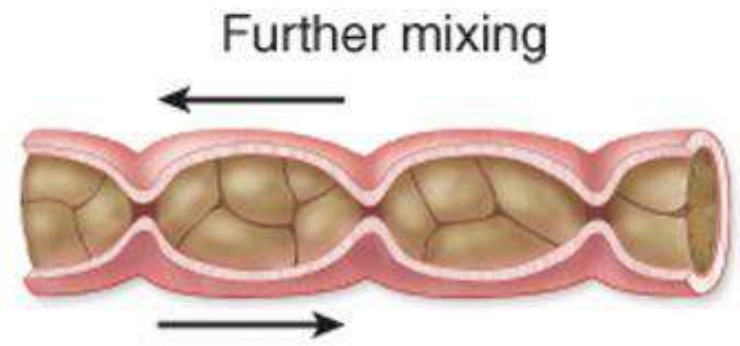
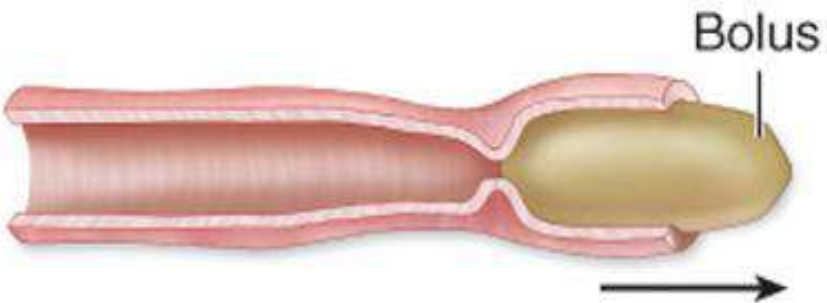
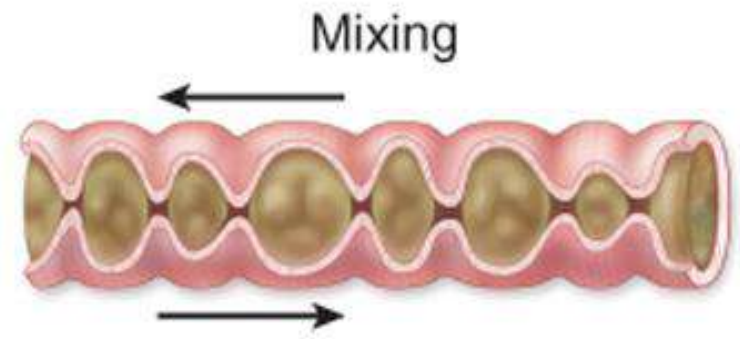
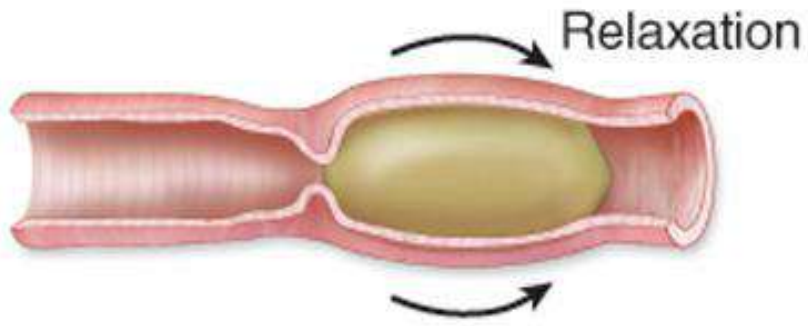
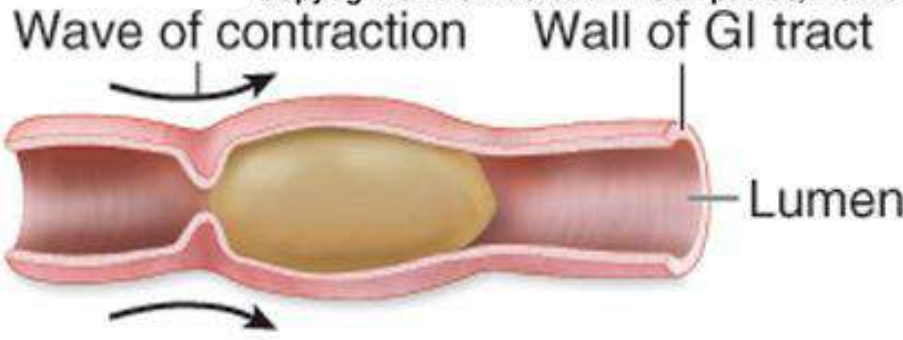
(b)



(a)

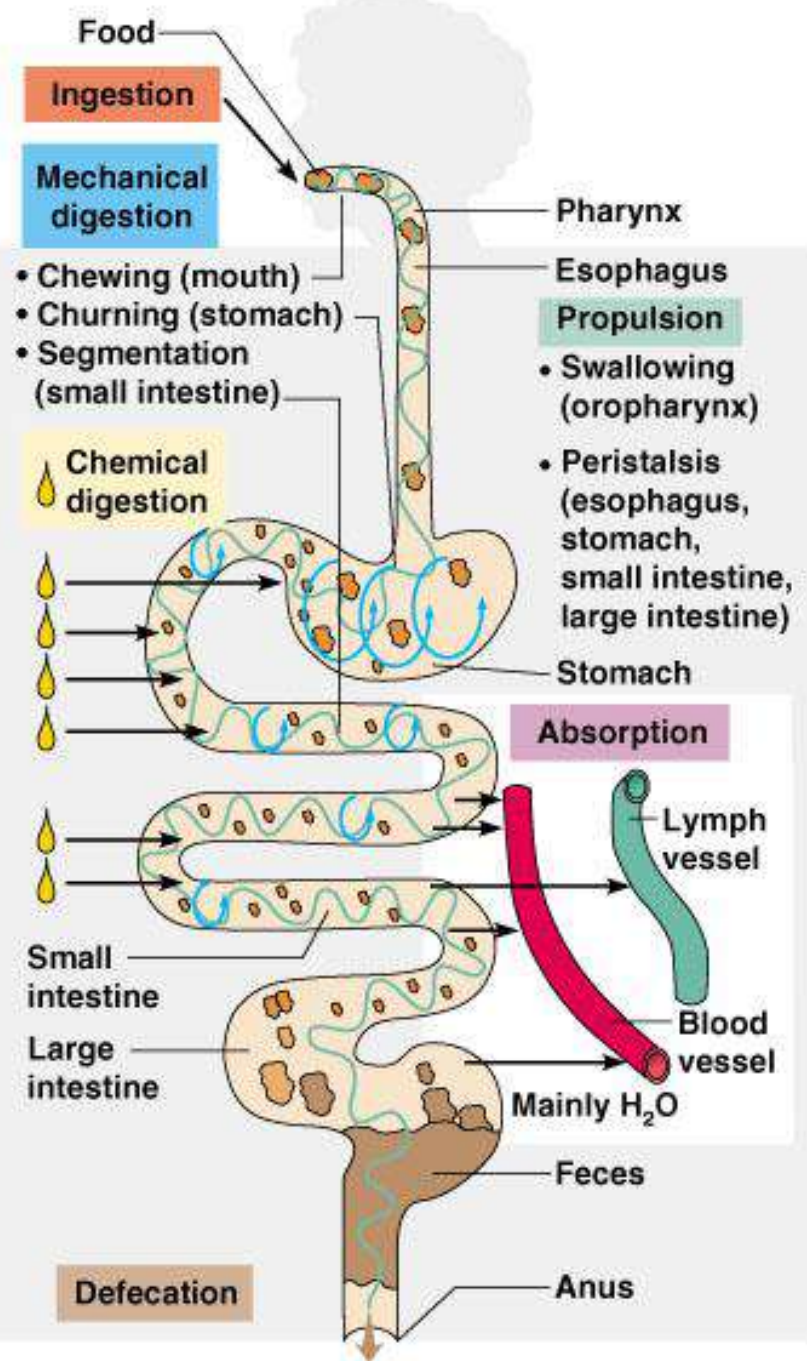
Alimentary Canal



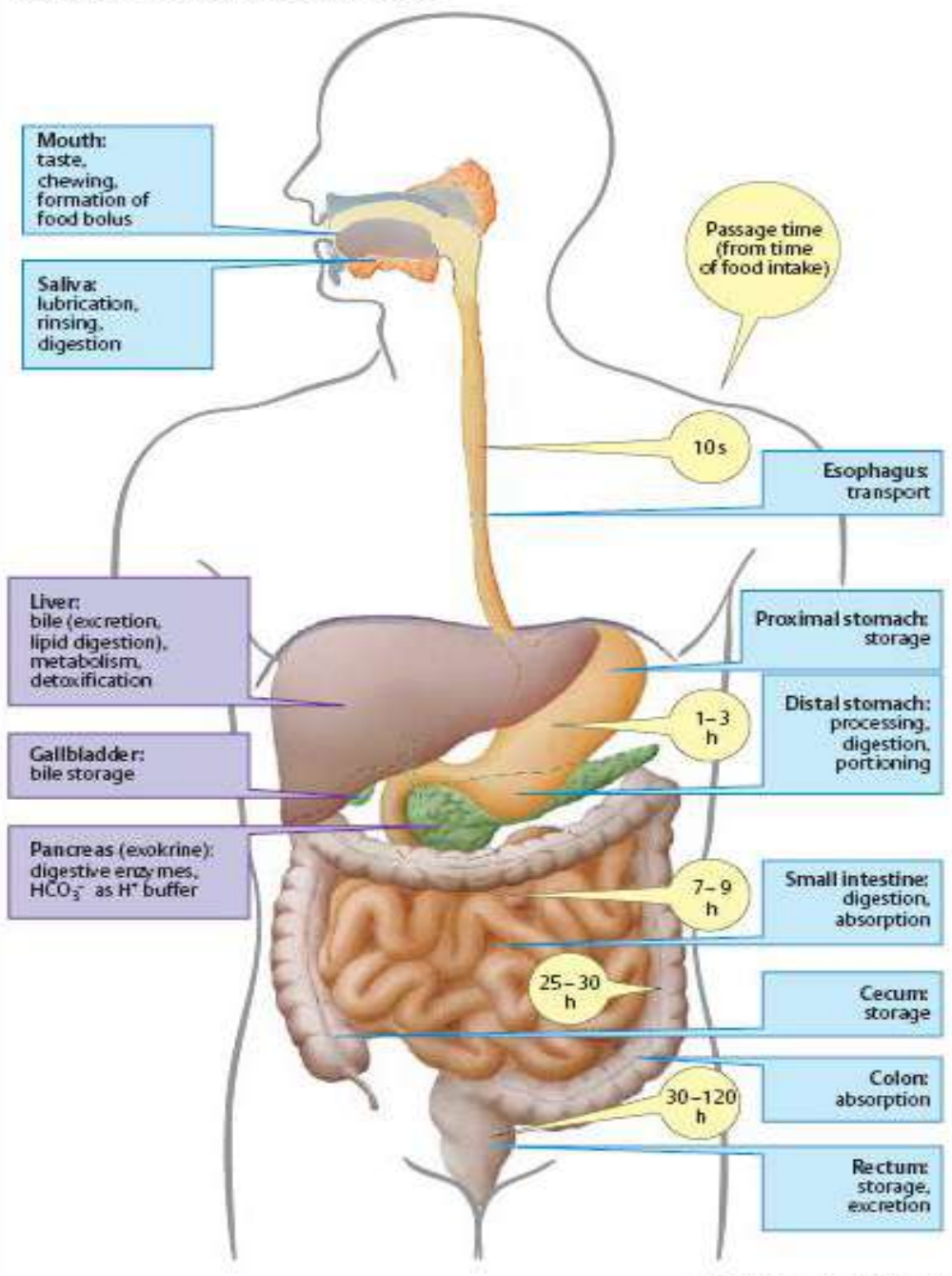


(a) Peristalsis

(b) Segmentation

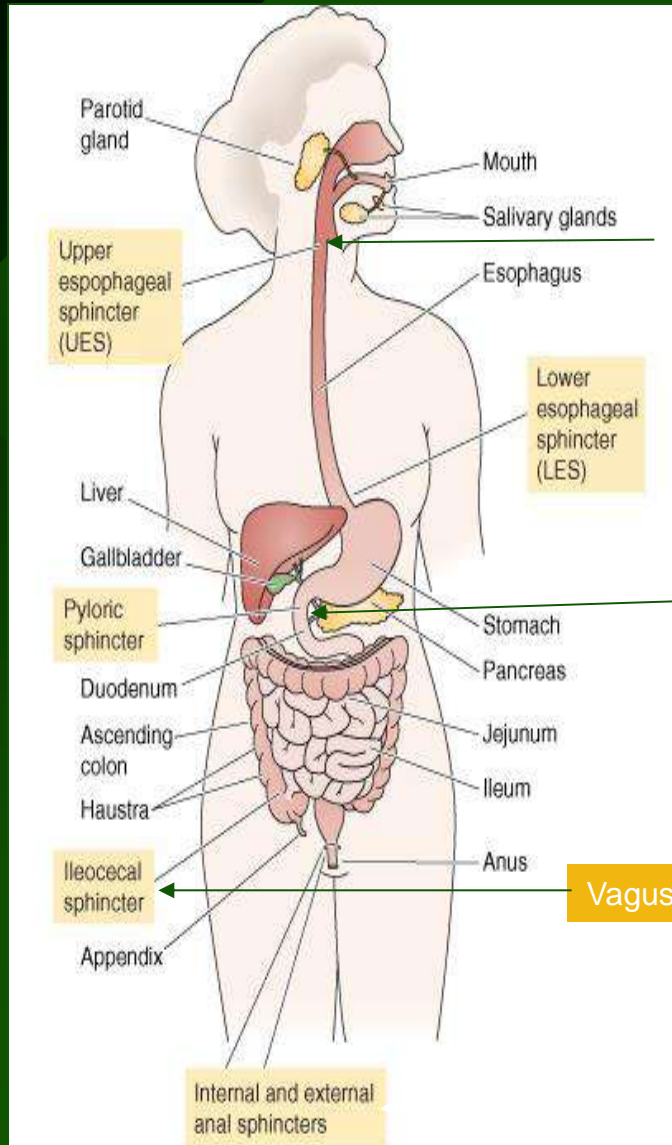


A. Function of gastrointestinal organs



(After Kahle, Leonhardt & Platzer)

Six Sphincters

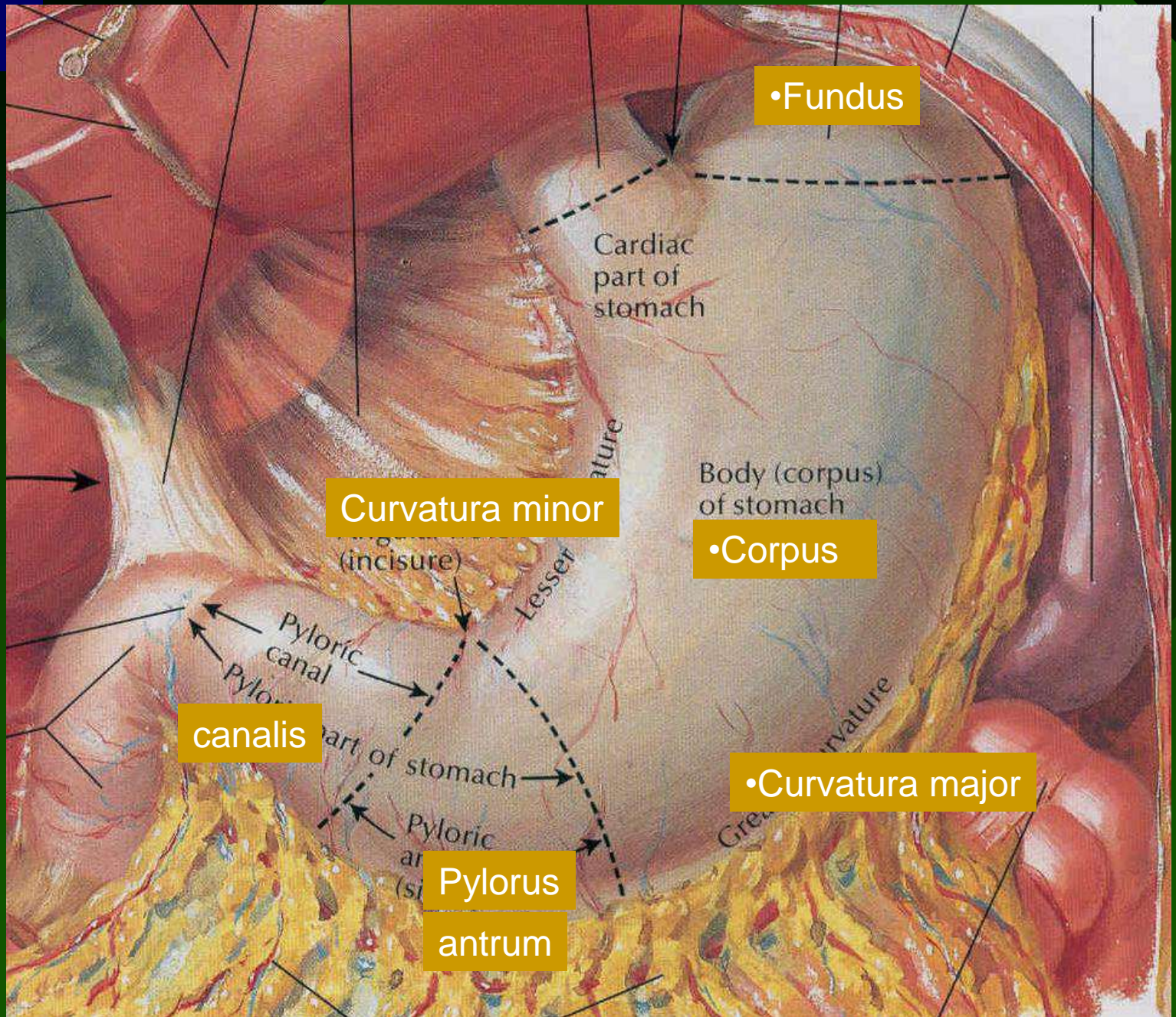


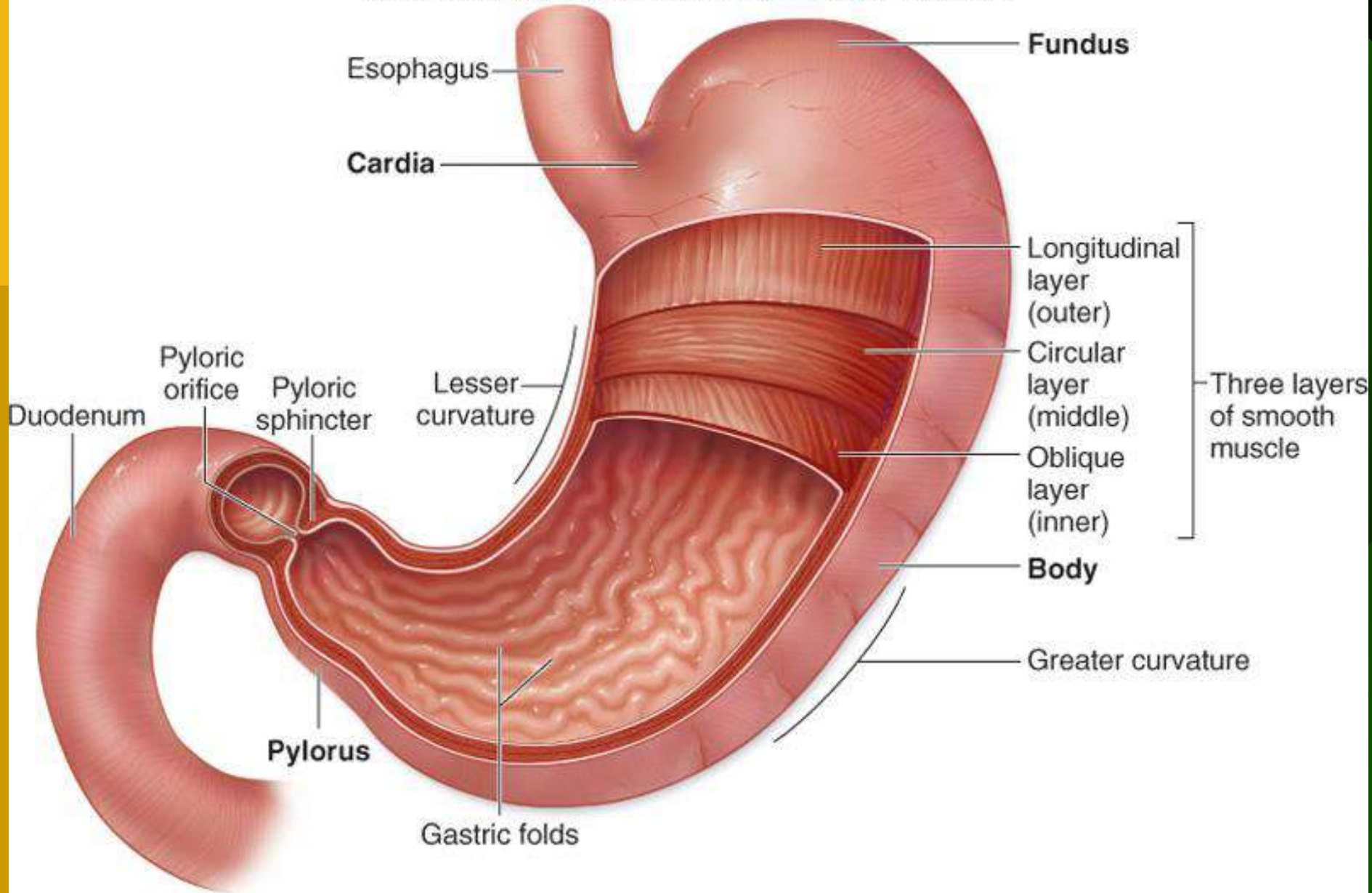
Sphincter of Oddi

Gallbladder/duodenum

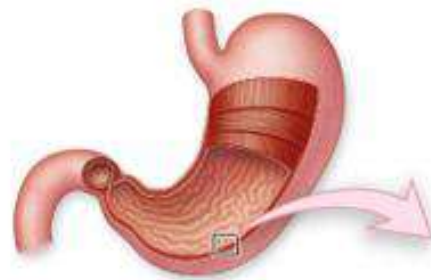
Vagus nerve, sympathetic nerves

gaster



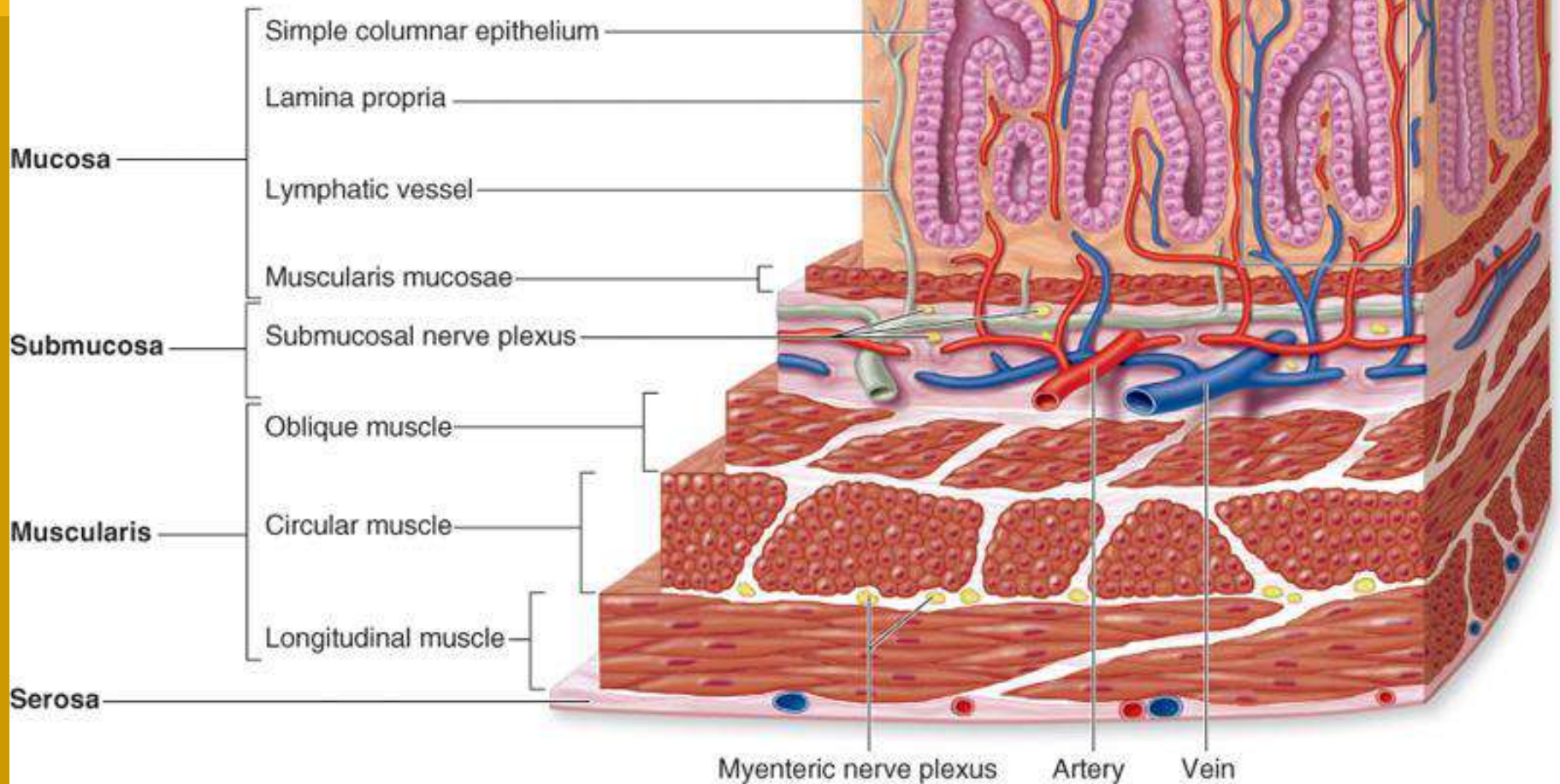


(a)



Opening to gastric pit

Gastric pit

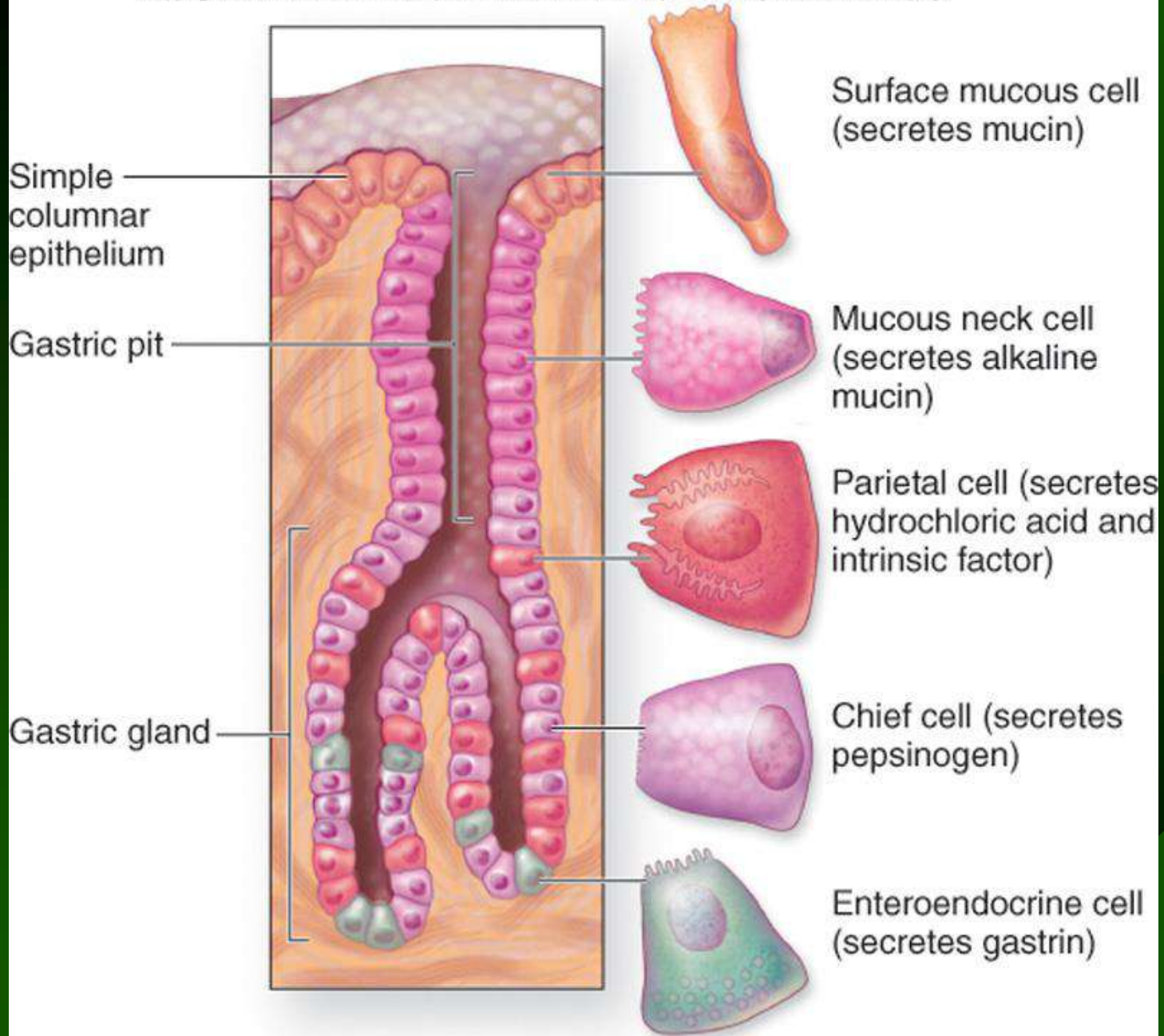


(a) Sectional view

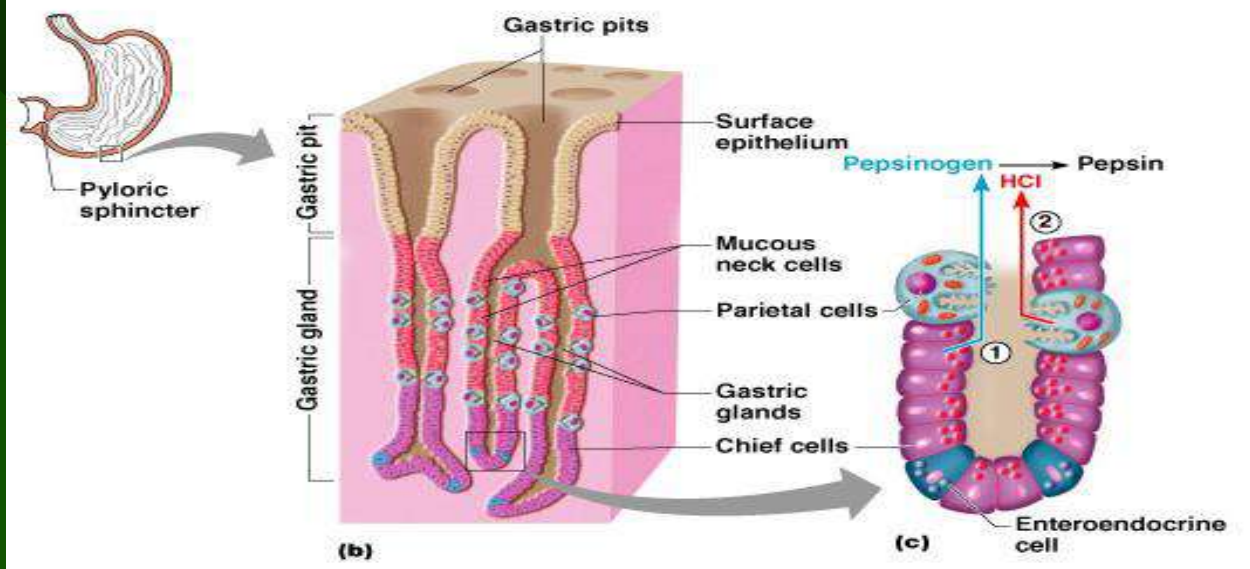
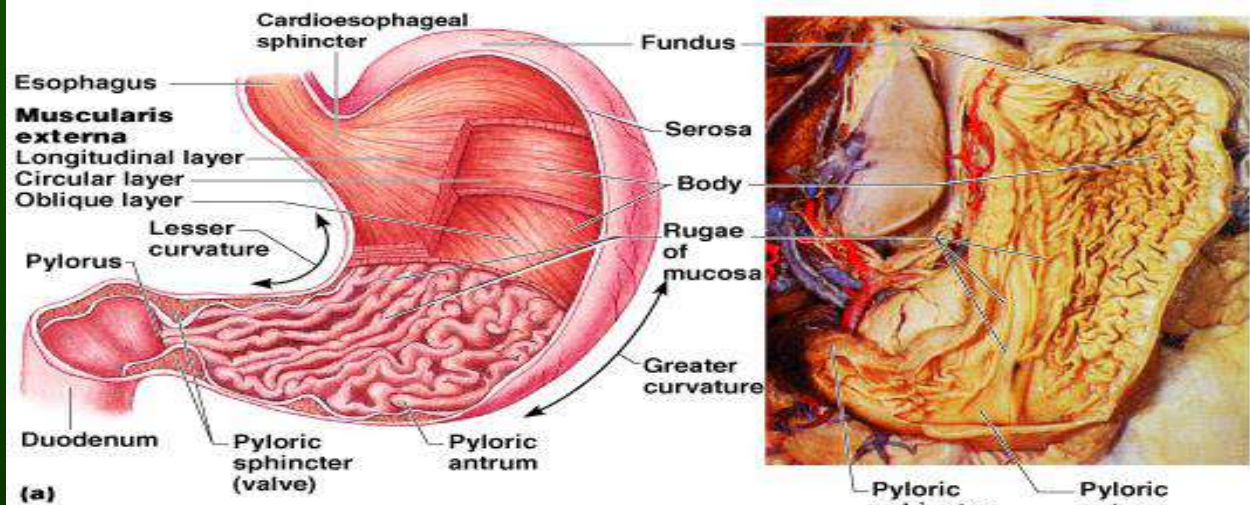
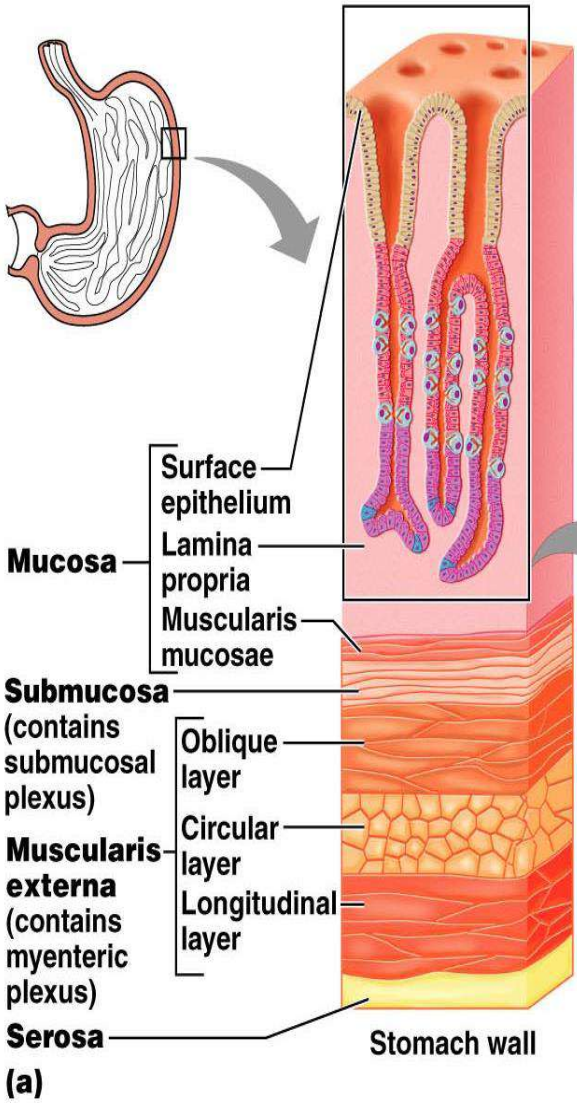
Sekresi lambung

- Terdapat 5 tipe sel yang mensekresi kelenjar:
 - Sel Goblet mensekresi mukus
 - Sel Parietal mensekresi asam hidroklorida, faktor intrinsik
 - Sel prinsipal (chief cell) mensekresi pepsinogen
 - Sel argentaffin mensekresi serotonin dan histamin
 - Sel endokrin (G cell) mensekresi hormon gastrin

- Asetilkolin membangkitkan sekresi semua sel-sel sekretoris, yaitu sekresi pepsinogen oleh chief sel, asam hidroklorida oleh sel parietal, mukus oleh sel mukus
- Gastrin dan histamin merangsang dengan kuat sekresi asam hidroklorida oleh sel parietal

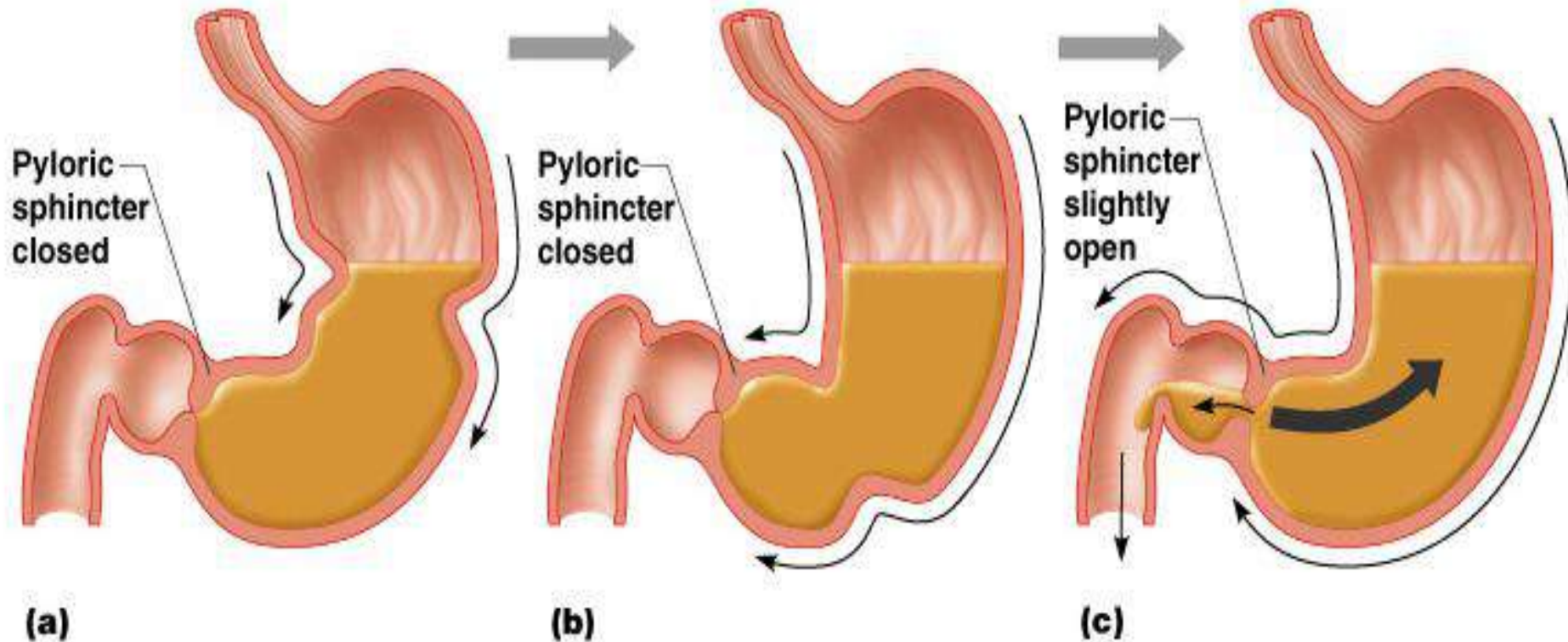


(c) Gastric pit and gland



- 3 fase sekresi lambung:
 - **Fase sefalik:** berlangsung sebelum makanan masuk lambung (melihat, membau, membayangkan makanan) atau waktu makanan masih dimakan
 - **Fase gastrik:** begitu makanan masuk lambung dan selama masih tetap di lambung
 - **Fase intestinal:** makanan dalam duodenum, akibat sejumlah kecil gastrin yang dihasilkan mukosa duodenum


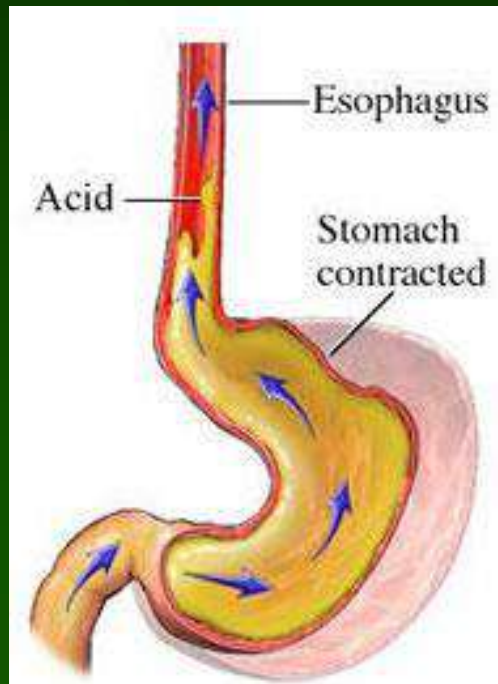
Stomach Movements



- Cephalic : secreti gastric distimulasi oleh masuknya makanan
- Gastric : makanan masuk ke lambung dan diolah
- Intestinal : makanan yang sudah diolah masuk ke intestinal

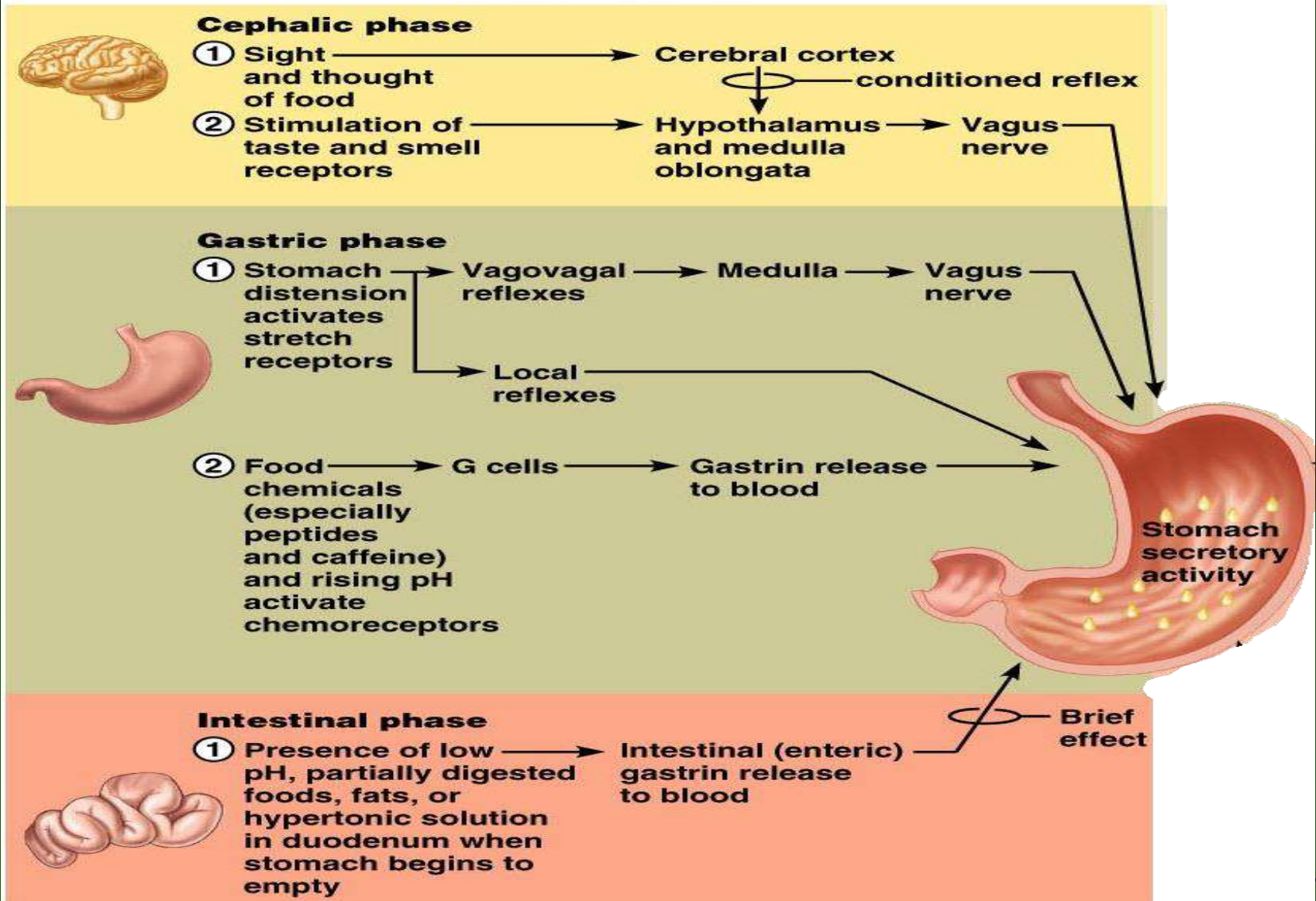
Digestive Homeostasis Disorders

- HEART BURN – ACID from the stomach backs up into the esophagus.



Ringkasan : Fase sekresi lambung

Stimulatory Events



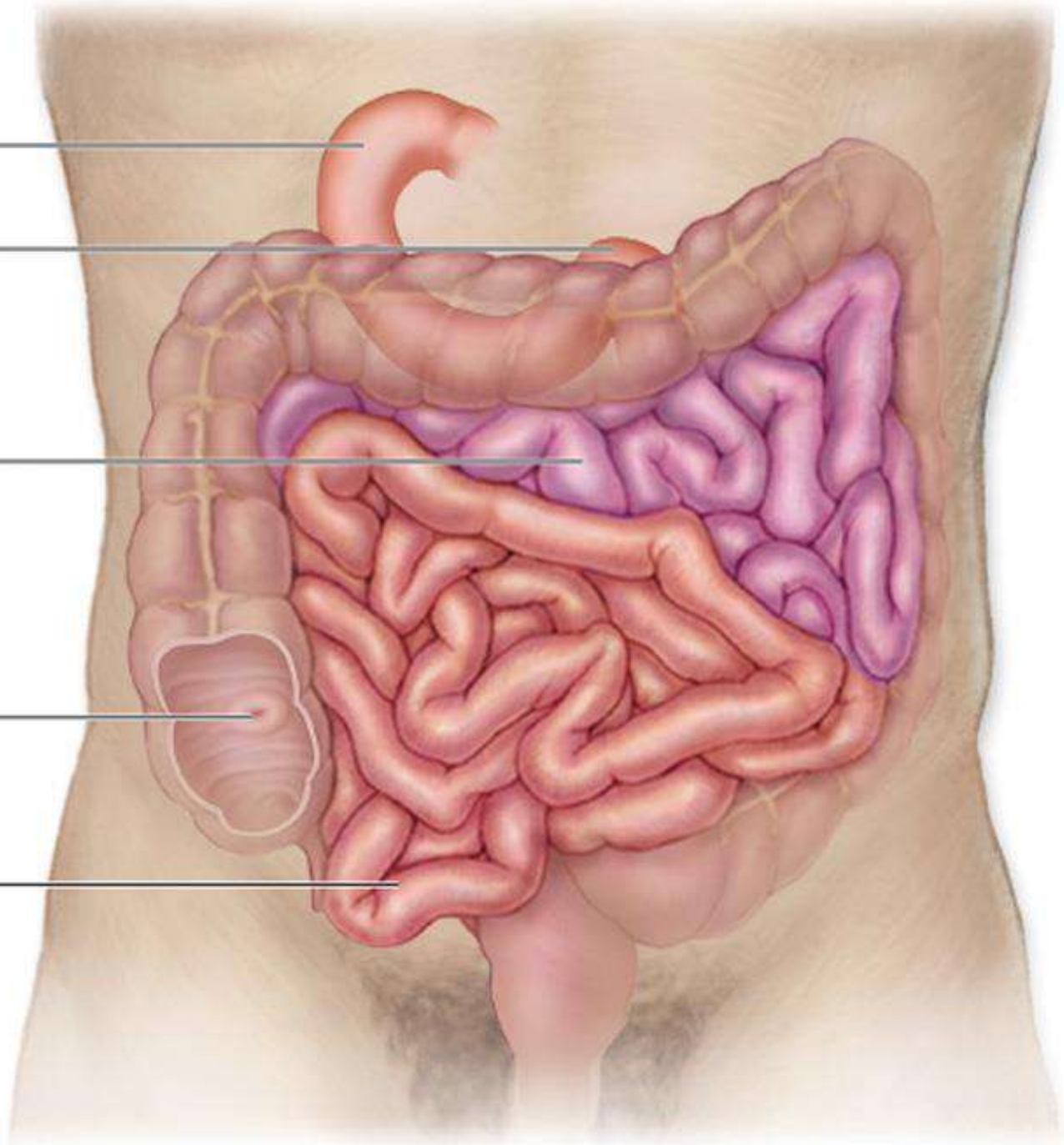
Duodenum

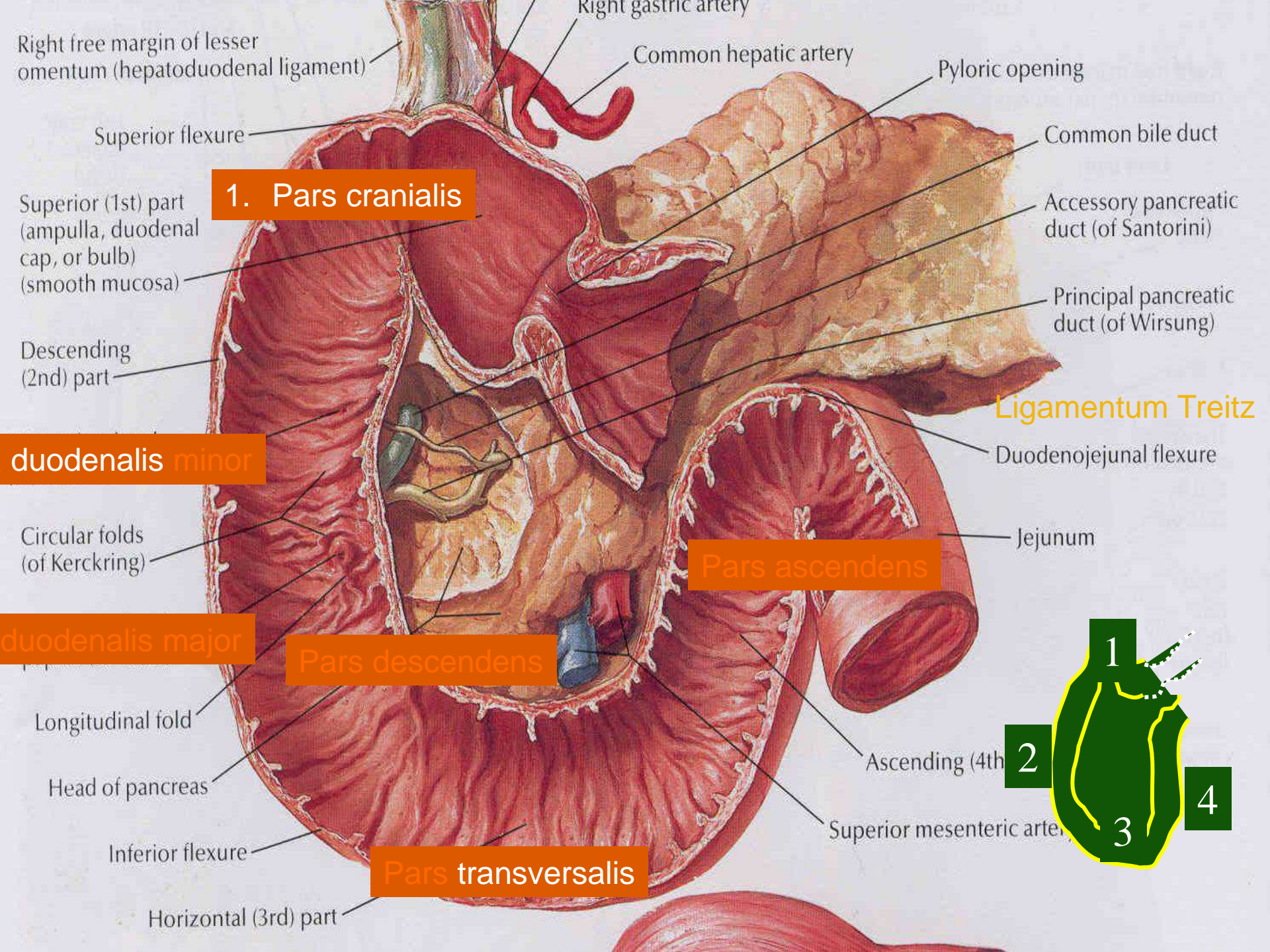
**Duodenojejunal
flexure**

Jejunum

Ileocecal valve

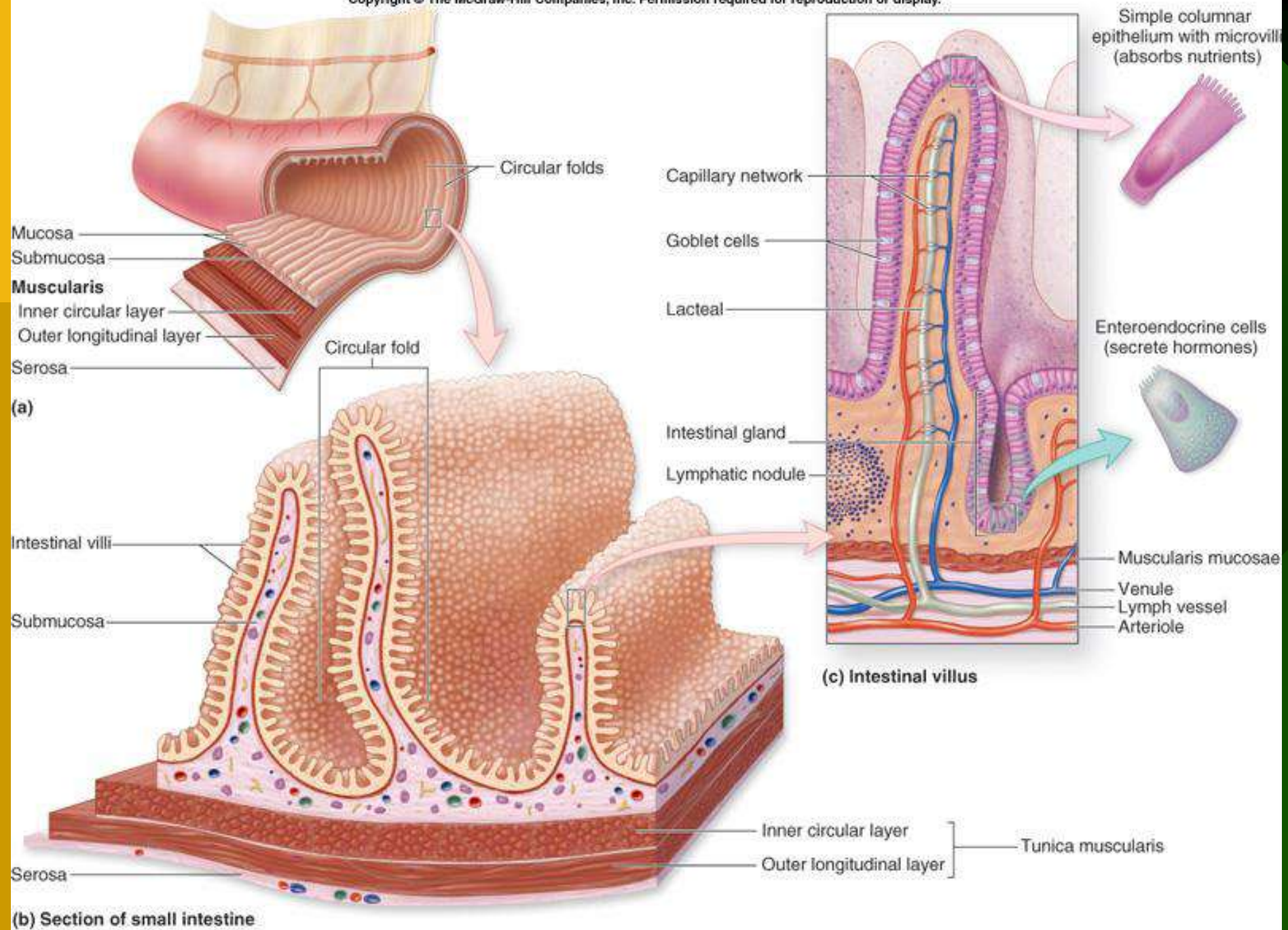
Ileum





Ligamentum Treitz

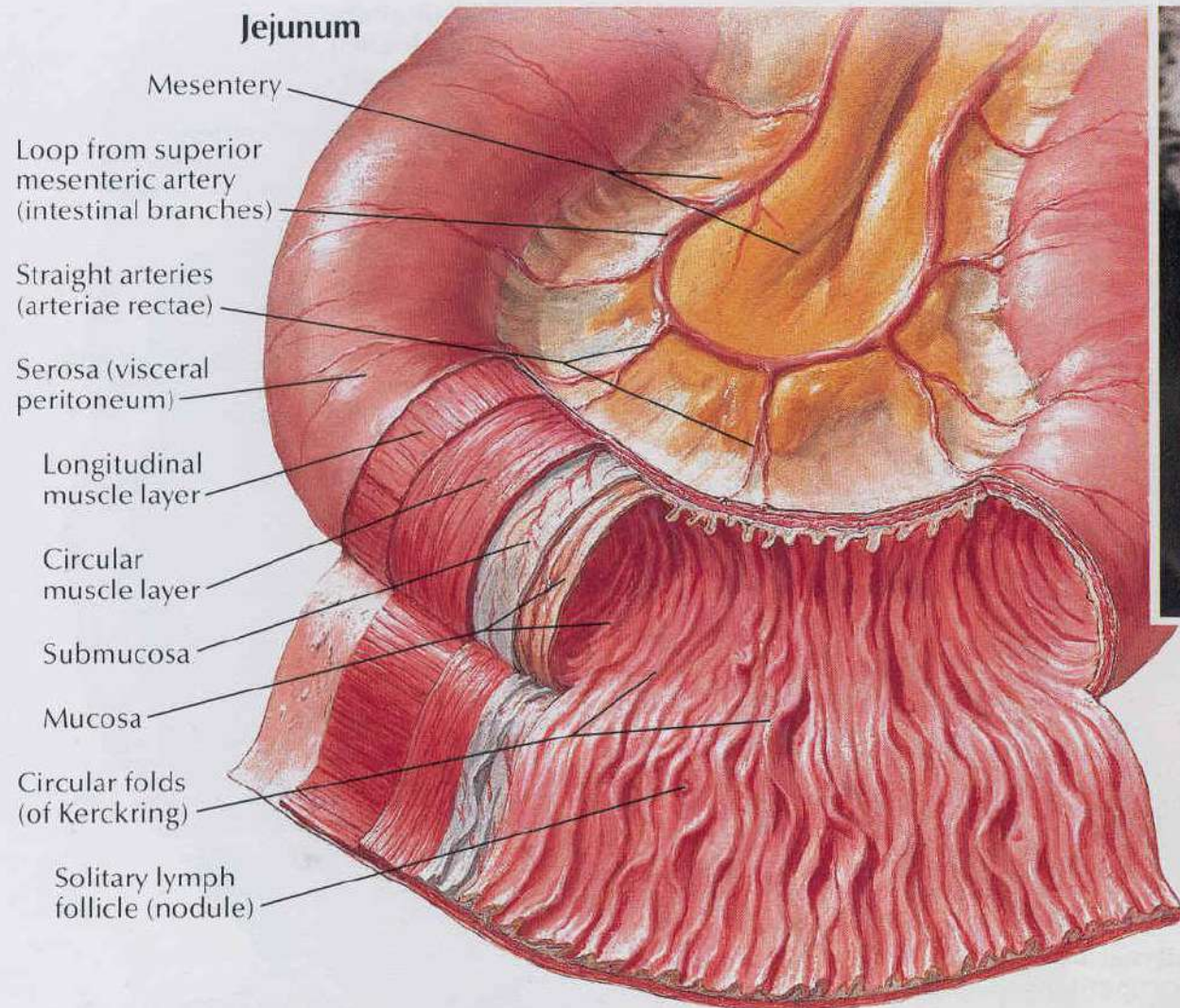
- Penggantung duodenum
- Letak : bagian terminal dari flexura duodeno jejunalis
- Terdiri atas :
 - Otot skeletal dari diaphragma sekitar Hiatus Oesophagicus ke jaringan ikat sekitar A. coeliaca
 - Otot polos (mendapat inervasi saraf otonom)



(b) Section of small intestine

(c) Intestinal villus

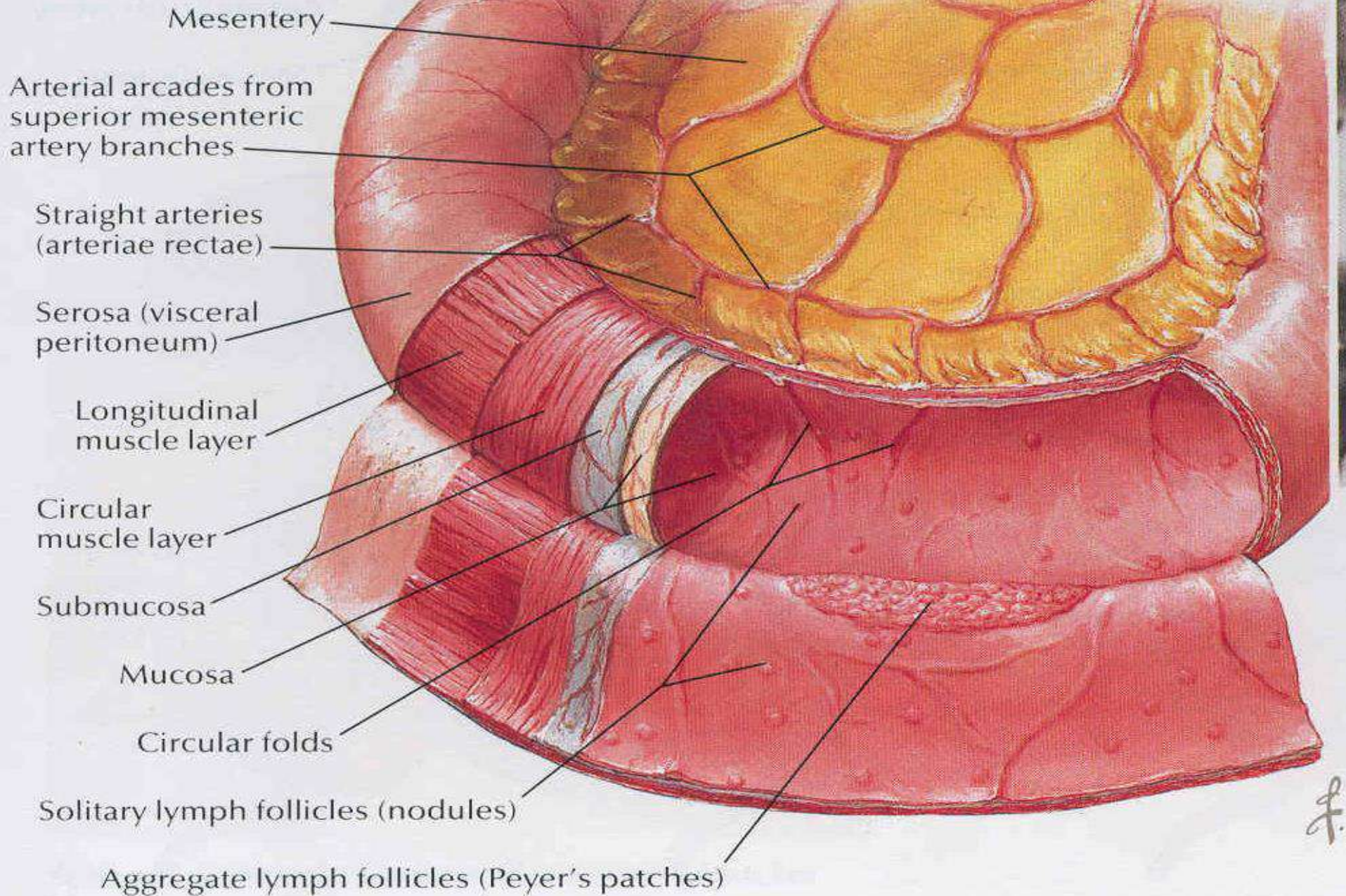
Jejunum

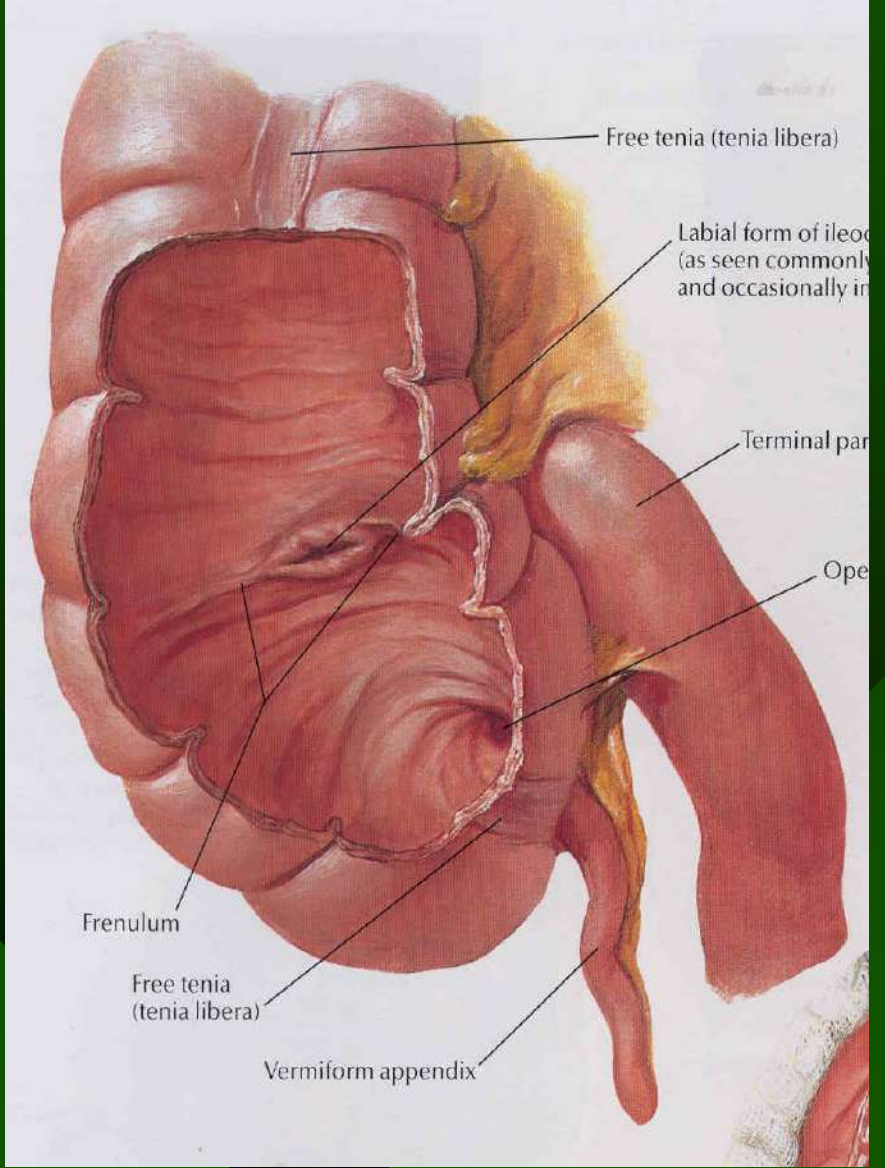
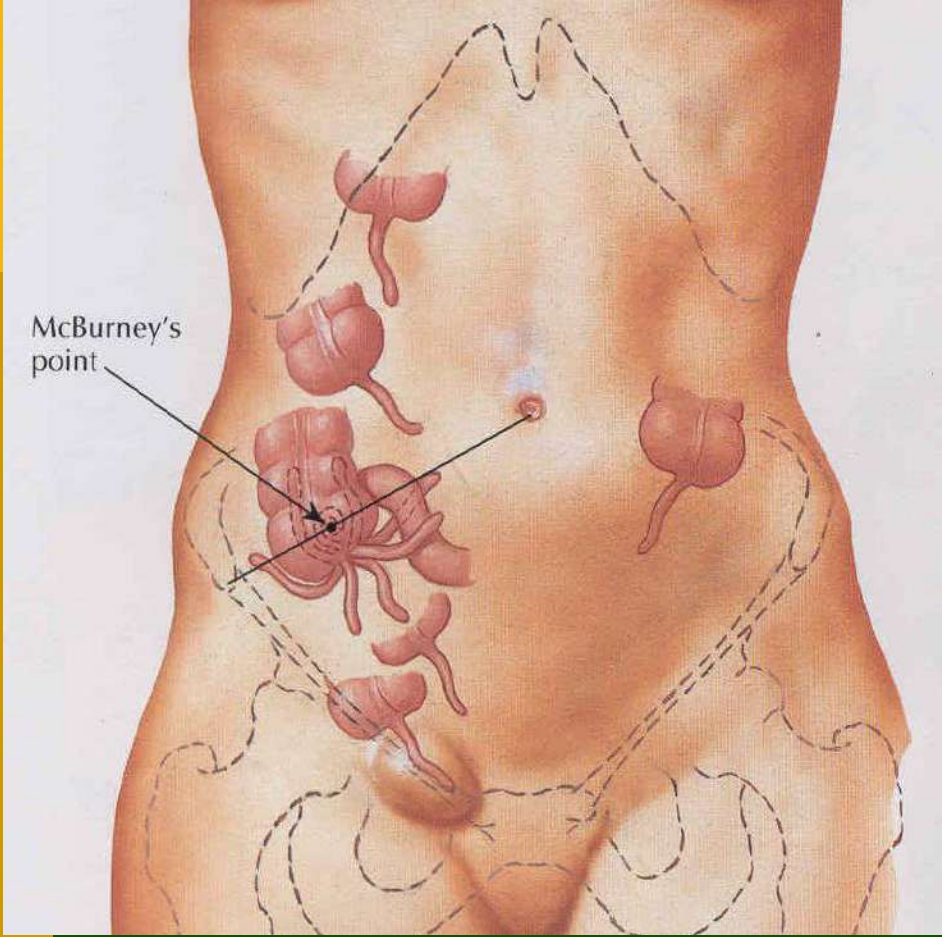


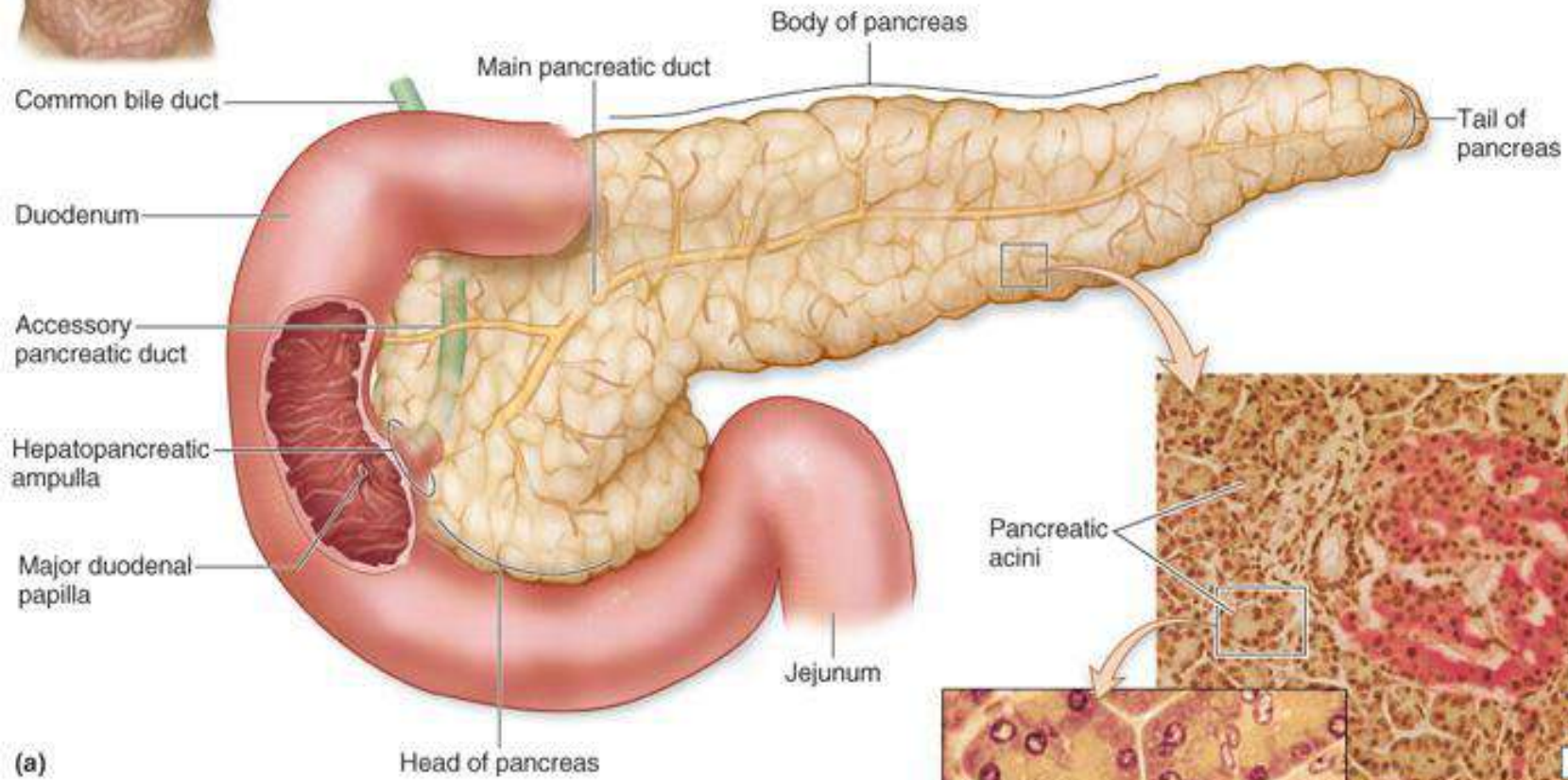
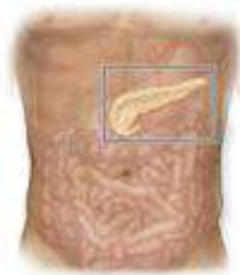Intestinum tenue :

- **Terdiri dari:**
 - Duodenum, Jejunum , Ileum
- **Mucosa :**
 - Pilica circularis Kerkringi
- **Submucosa**
 - Glandula Brunner
 - Patches of Peyer (ileum)
- **Muscularis**
- **Serosa**
 - Peritoneum visceralis

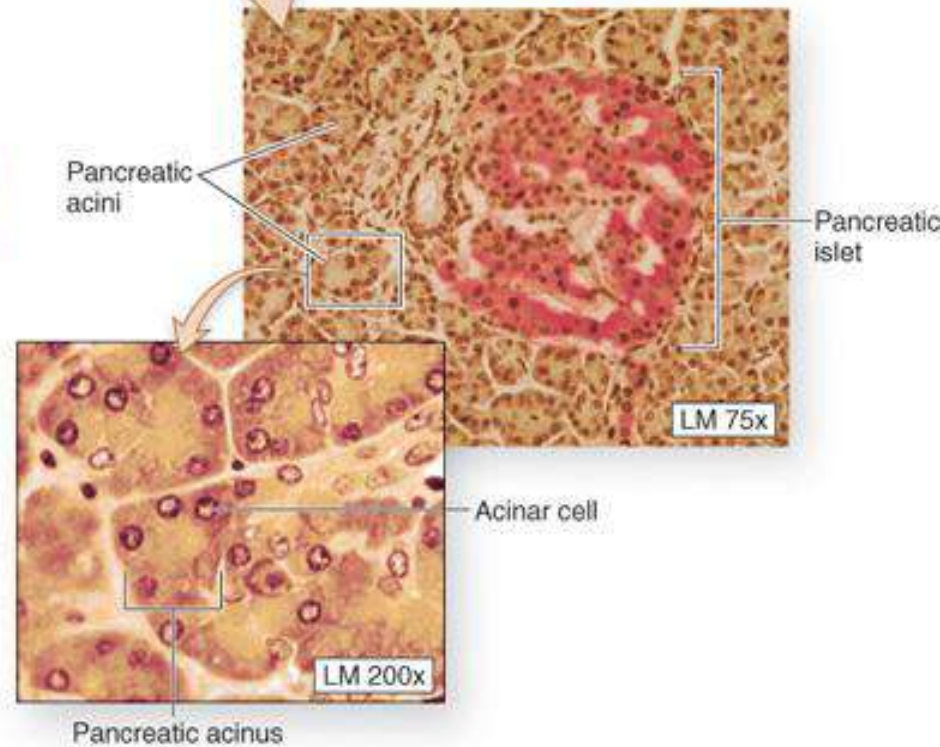
Ileum







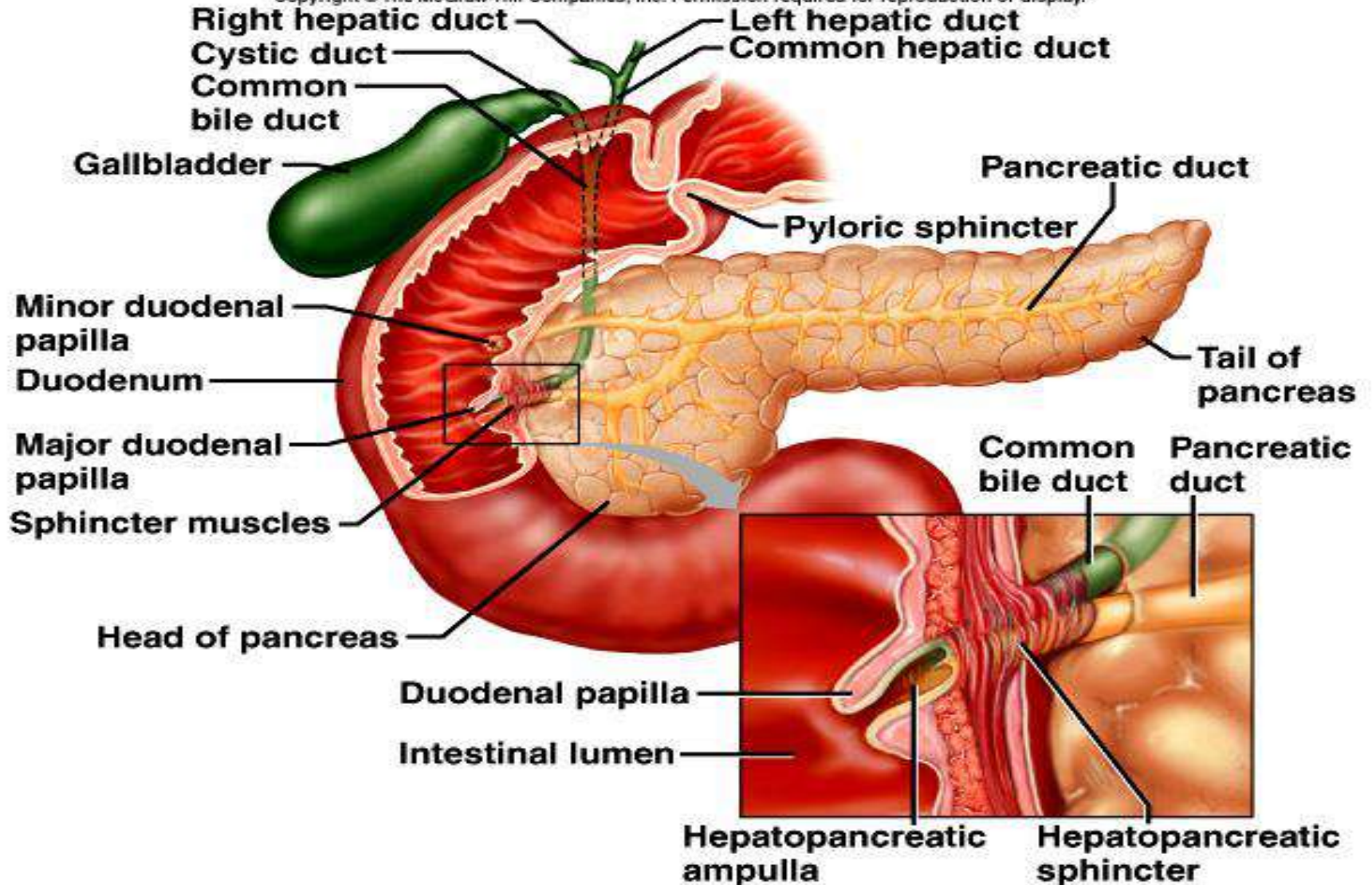
(a)



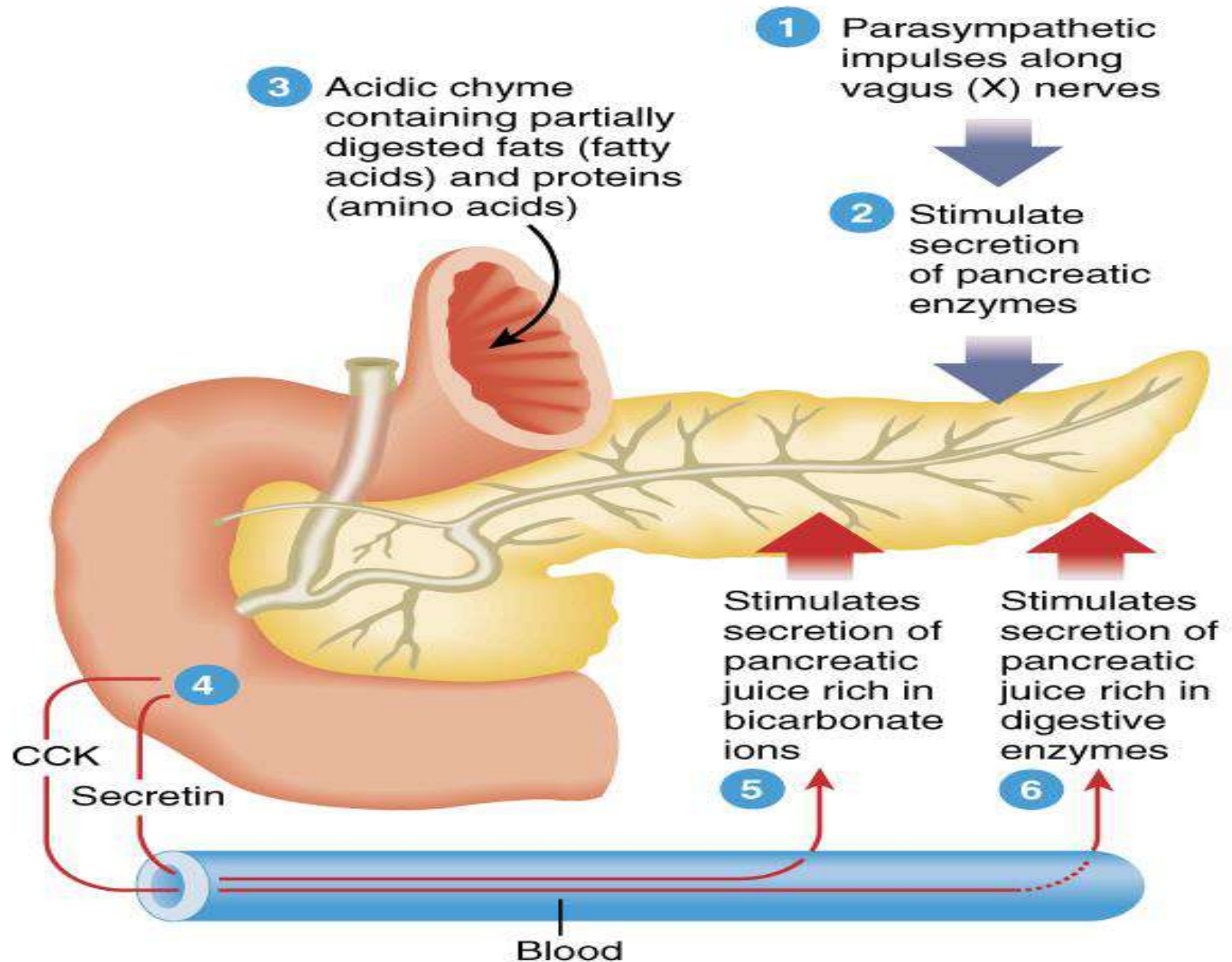
(b)

Pancreas

Copyright © The McGraw-Hill Companies, Inc. Permission required for reproduction or display.



Pengaturan Sekresi Pancreas



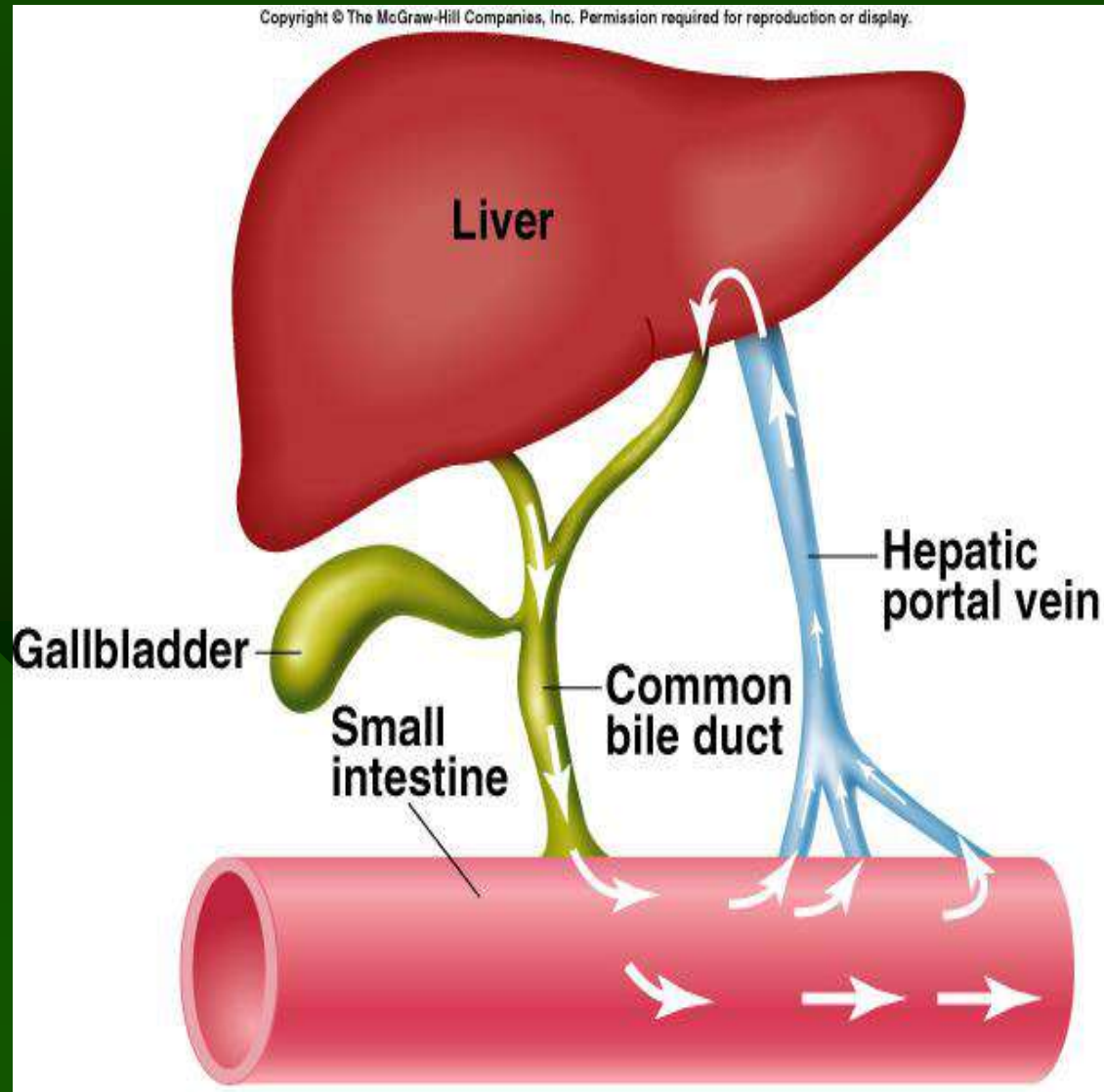


Functions of the Liver

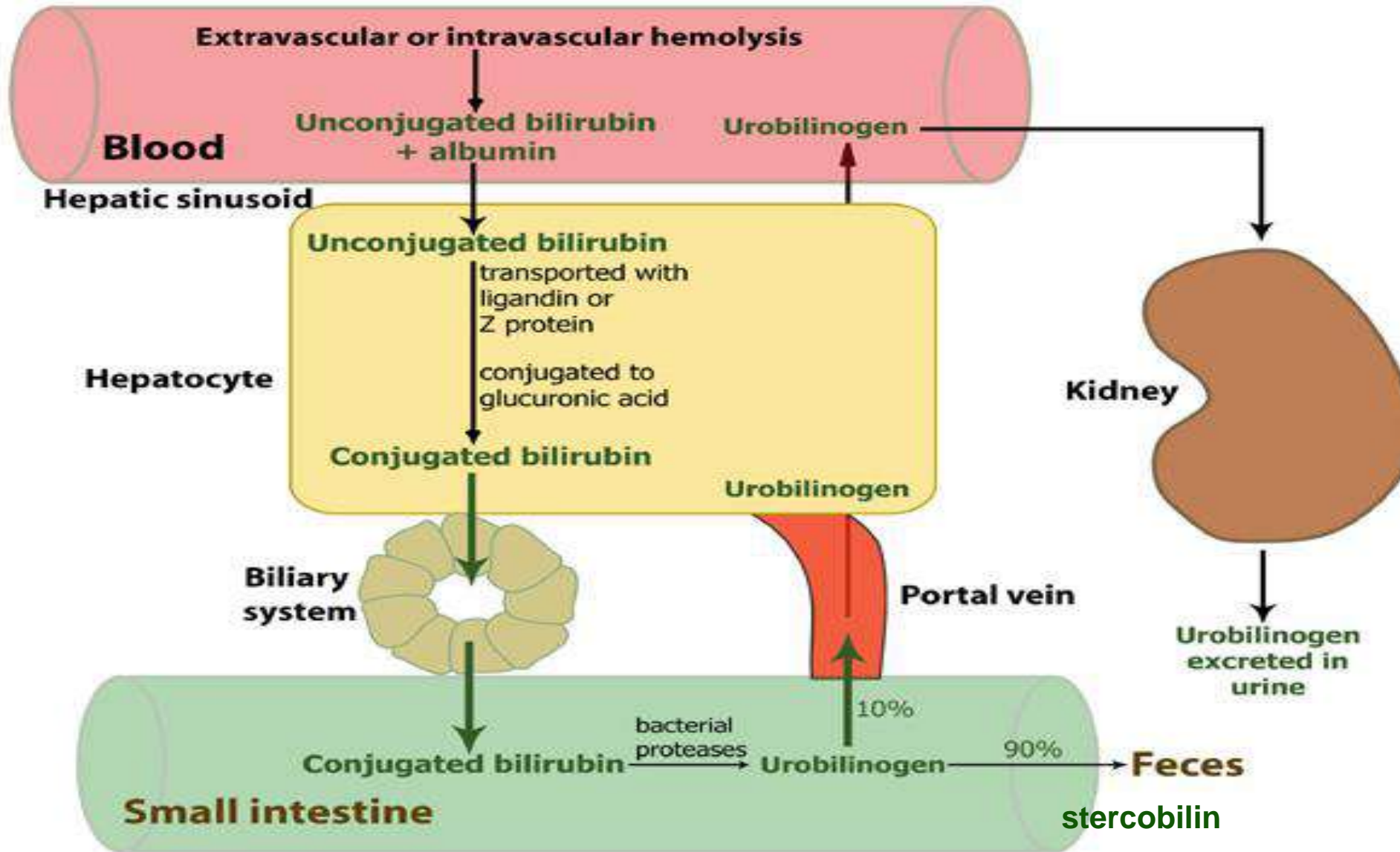
- **Bile production**
 - Salts emulsify fats, contain pigments as bilirubin
- **Storage**
 - Glycogen, fat, vitamins, copper and iron
- **Nutrient interconversion**
- **Detoxification**
 - Hepatocytes remove ammonia and convert to urea
- **Phagocytosis**
 - Kupffer cells phagocytize worn-out and dying red and white blood cells, some bacteria
- **Synthesis**
 - Albumins, fibrinogen, globulins, heparin, clotting factors

Enterohepatic Circulation

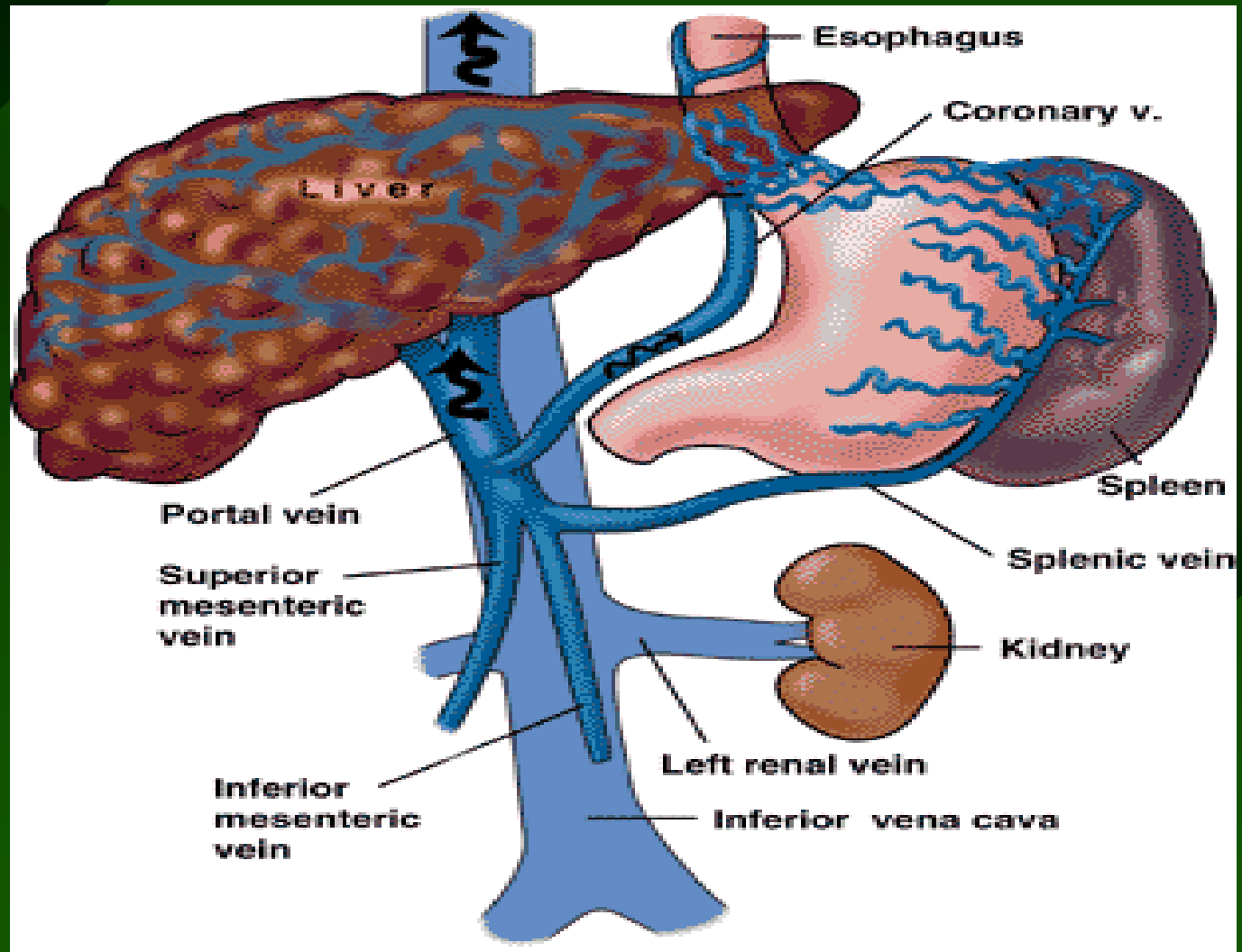
- Merupakan sirkulasi dari lever dan intestine
- Bilirubin dikeluarkan ke usus dan diabsorpsi, kemudian kembali lagi ke hepar
- Sebagian akan dikeluarkan melalui feces



Bilirubin Production & Metabolism:

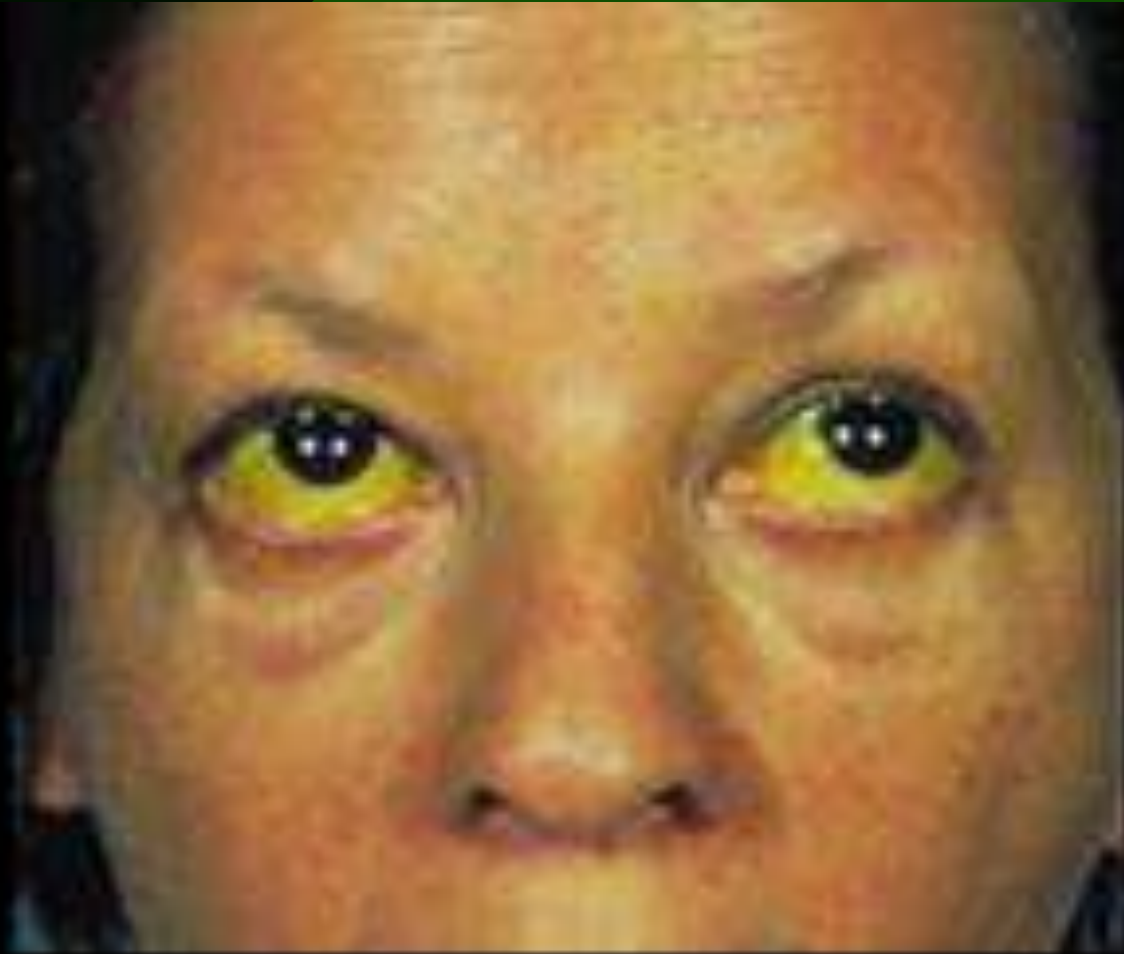

Portal Hypertension



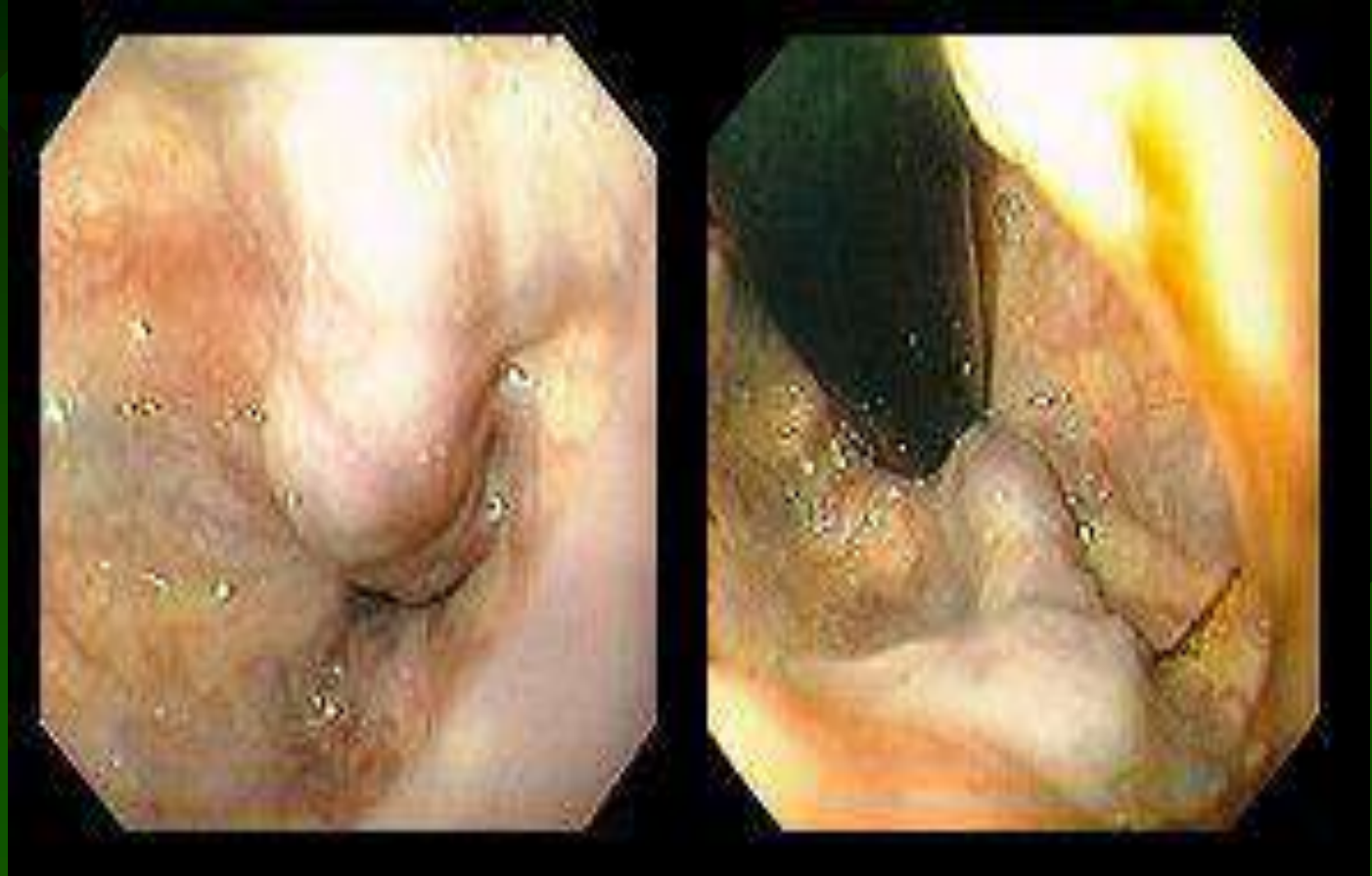Signs of Liver Disease

- Ascites
- Jaundice
- Palmar erythema
- Asterixis
- Testicular atrophy, gynecomastia
- Muscle wasting, Dupuytren contracture
- Splenomegaly

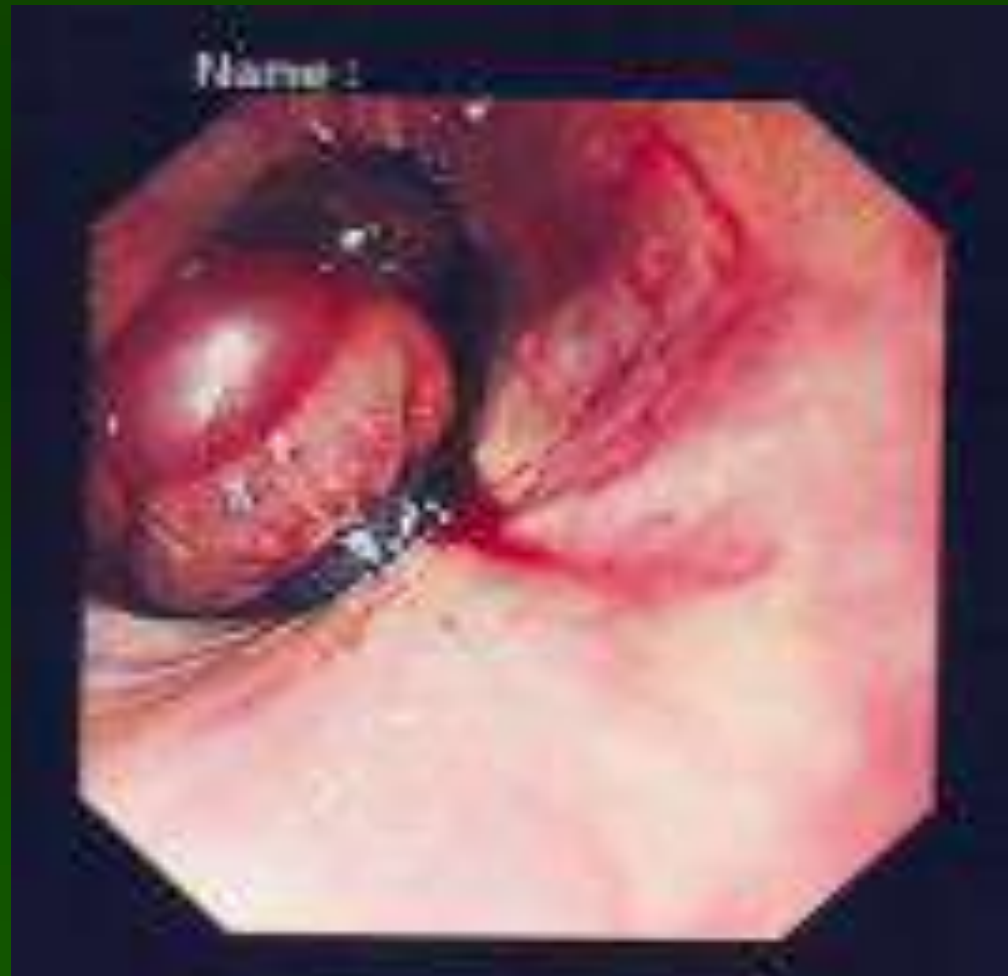

JAUNDICE

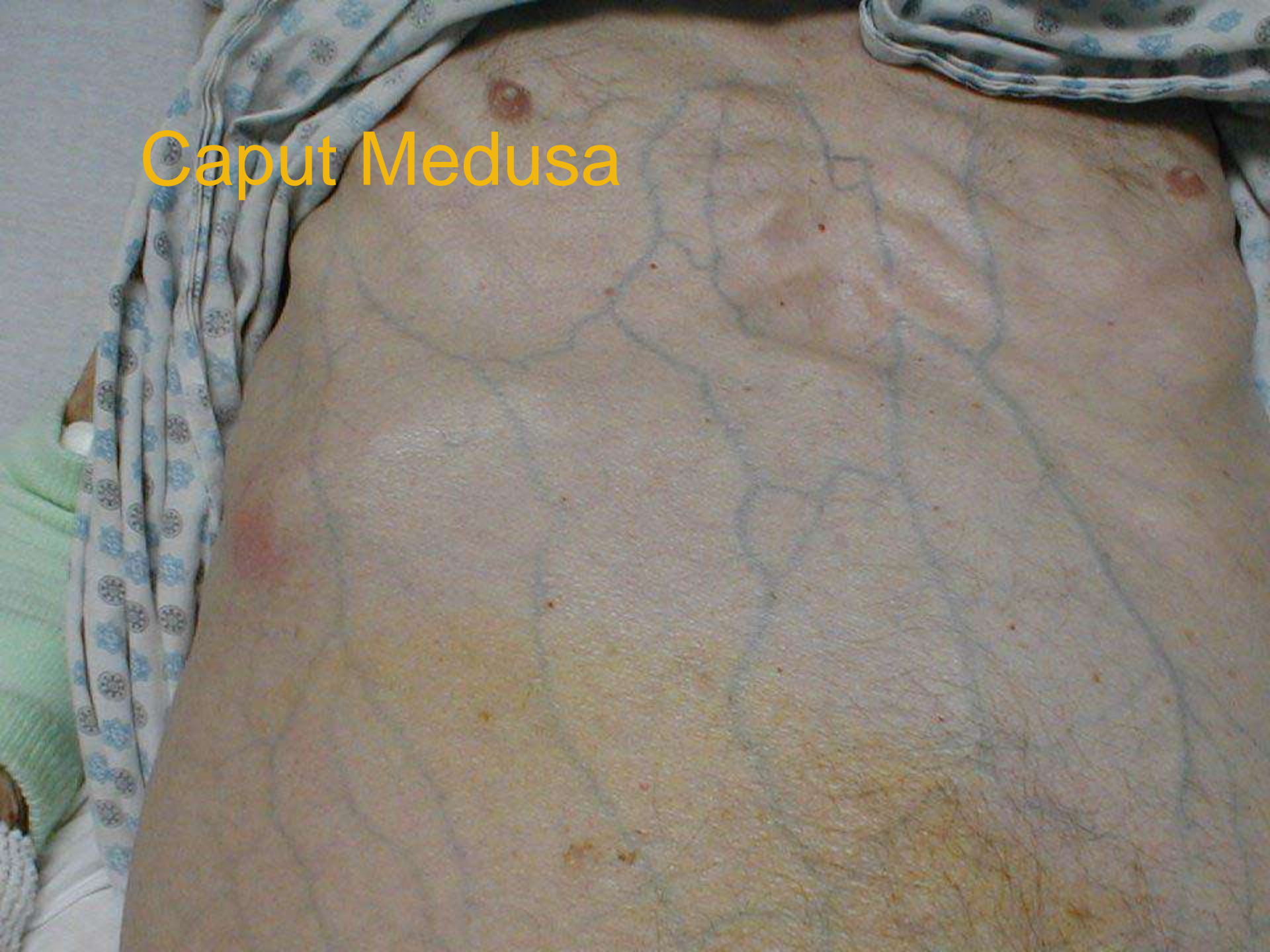Varices on EGD

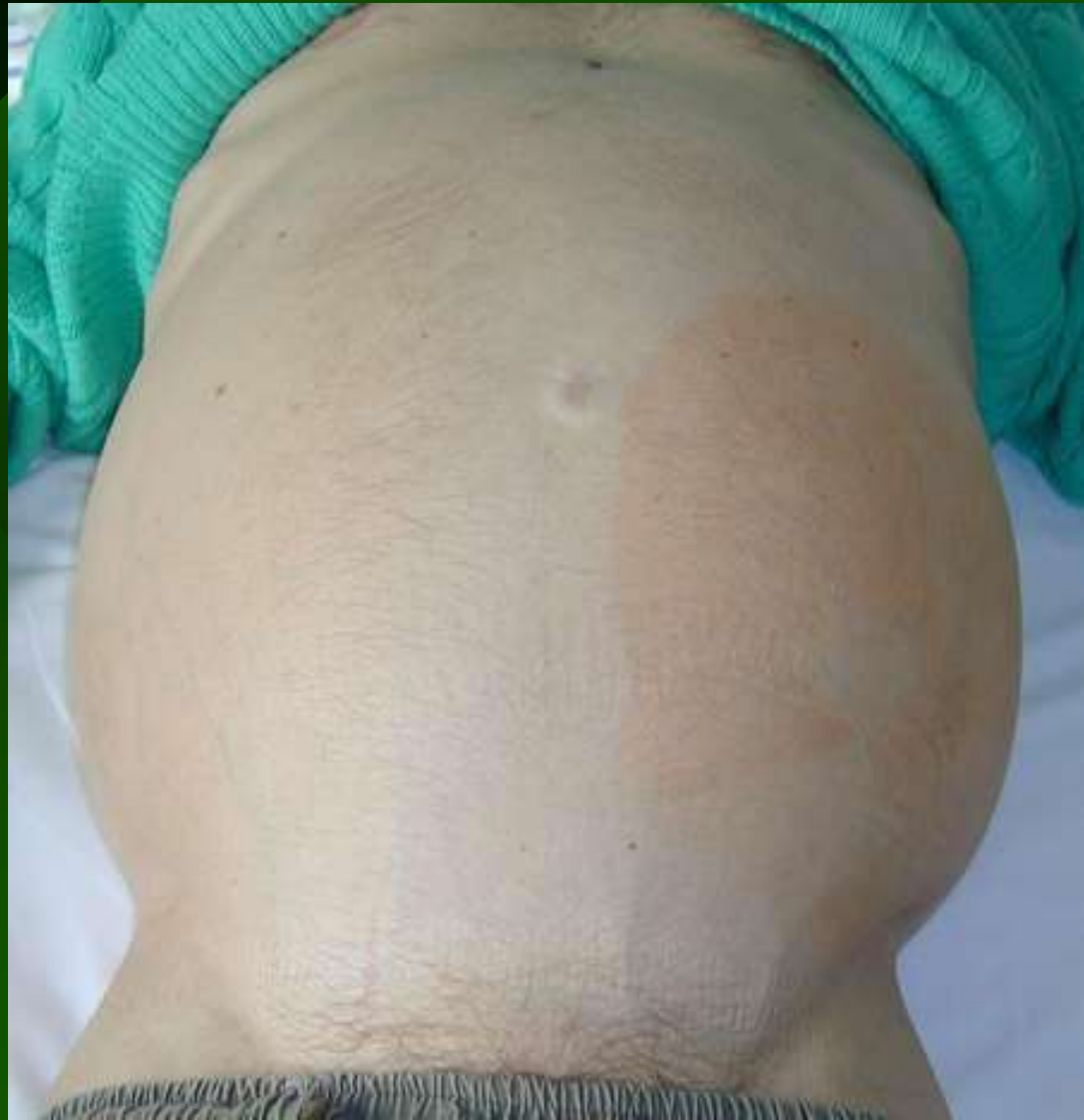

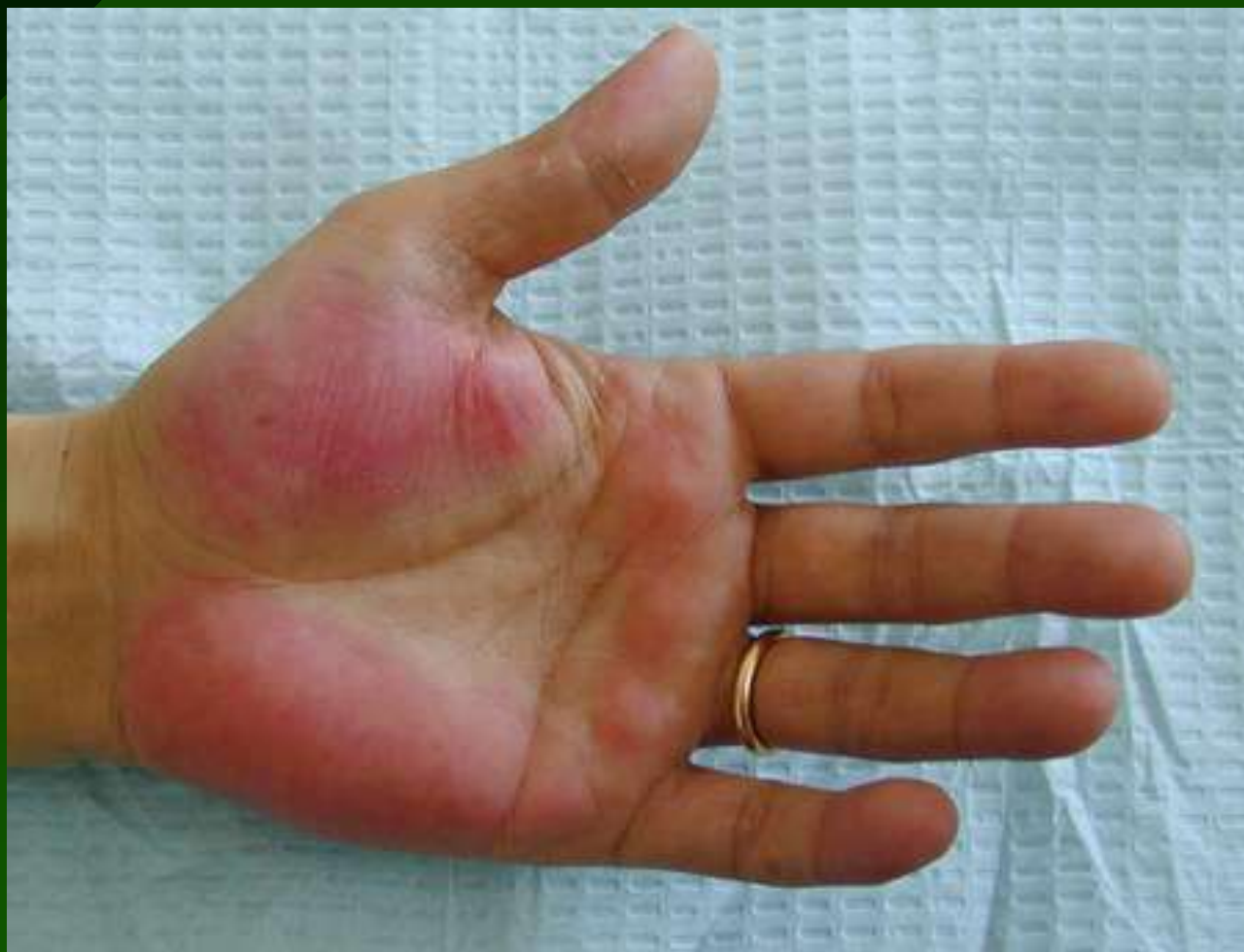Varix Banding

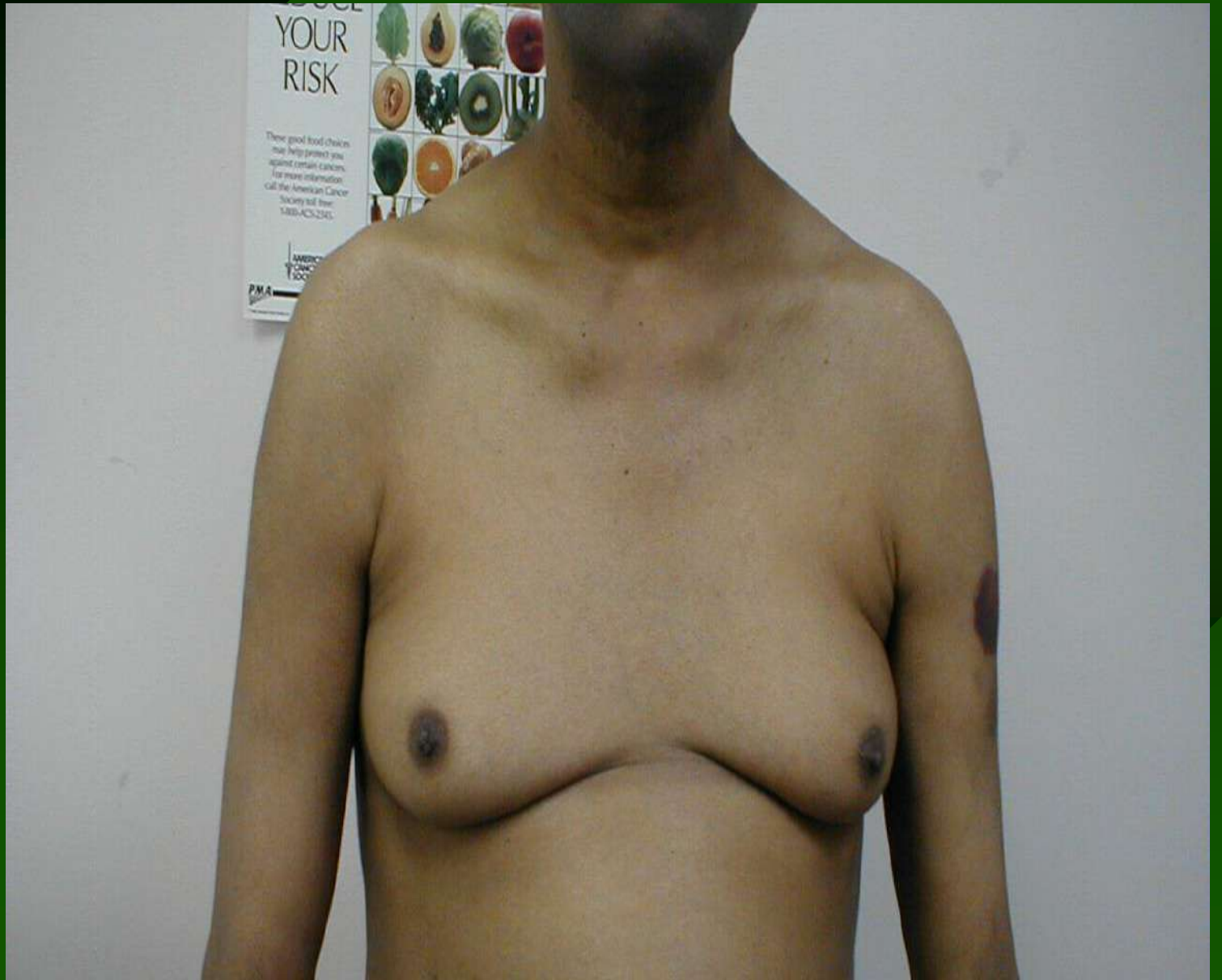

Caput Medusa

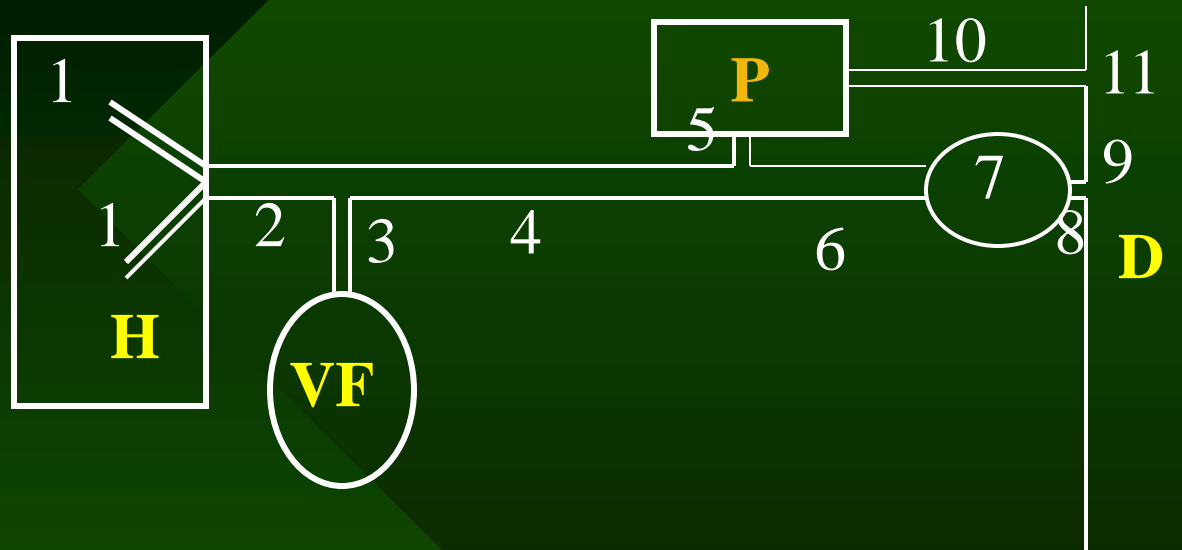






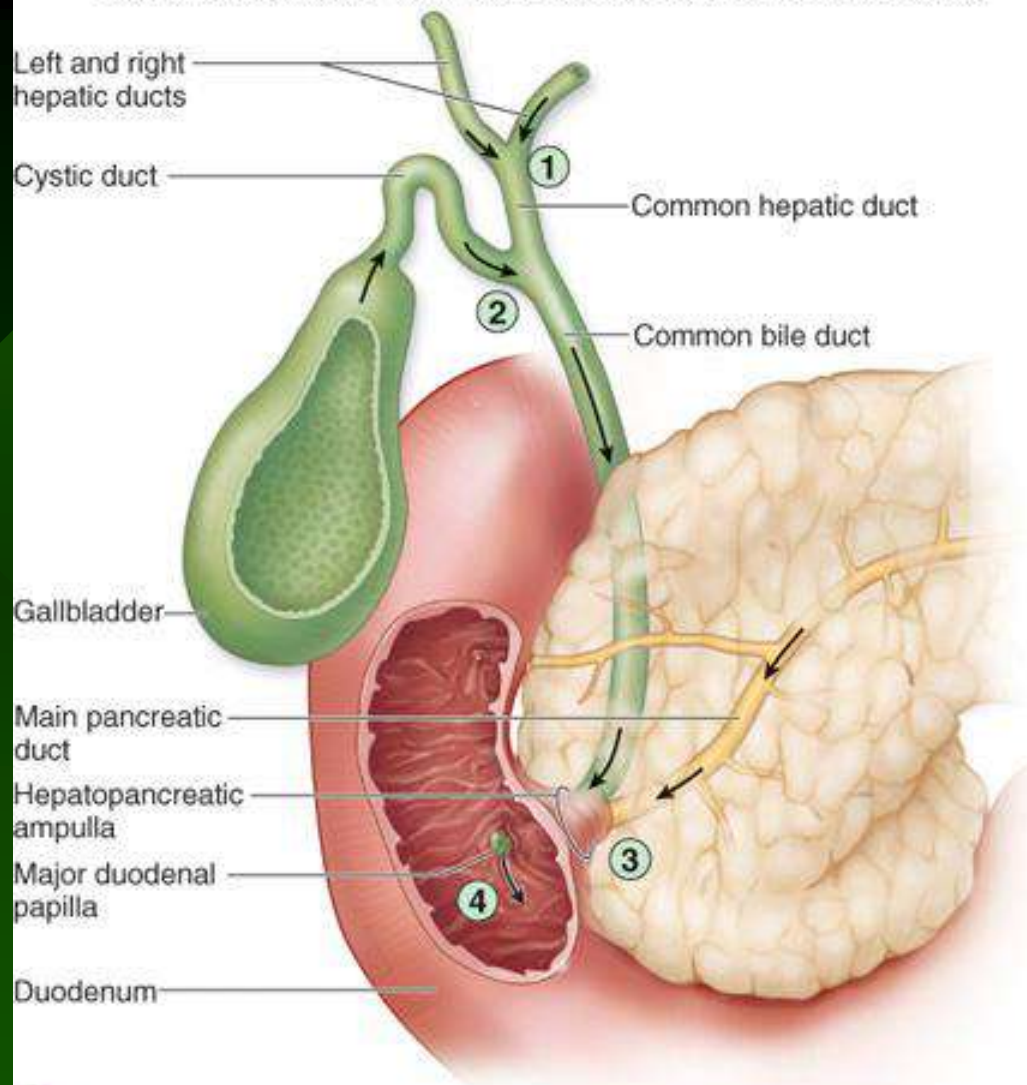


Tractus Hepatobiliaris



H : Hepar VF : Vesica Fellea P : Pancreas D: Duodenum

1. D. hepaticus 2. D. hepaticus communis 3. D. cysticus
4. D. choledochus 5. D.Pancreaticus major 6. D. hepato-pancreaticus
7. Ampulla (hepato-pancreaticus) vateri 8. Sphincter Oddii
9. Papilla duodenalis major vateri 10. Ductus pancreaticus minor
11. Papilla duodenalis minor



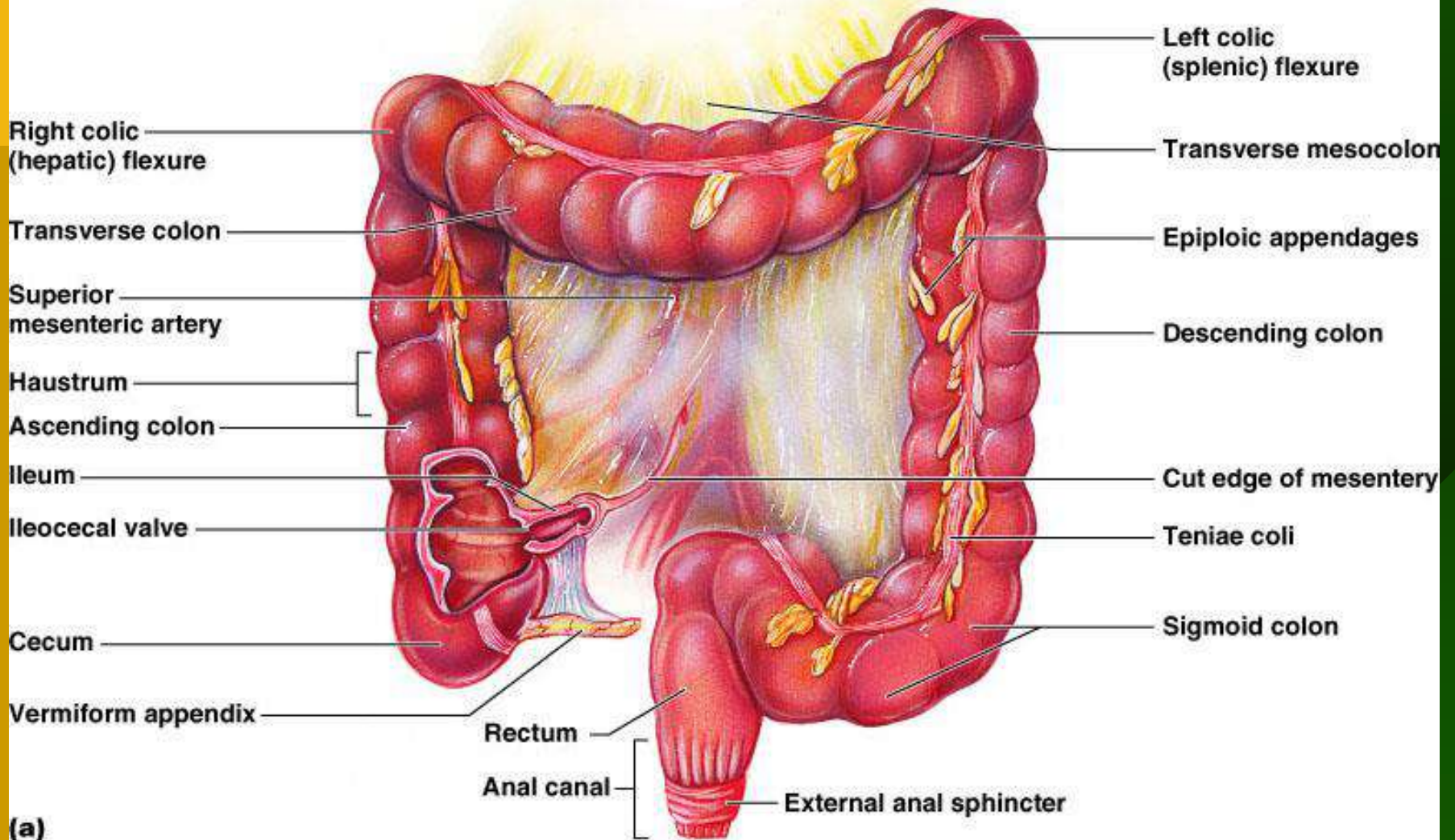
① Left and right hepatic ducts merge to form a common hepatic duct.

② Common hepatic and cystic ducts merge to form a common bile duct.

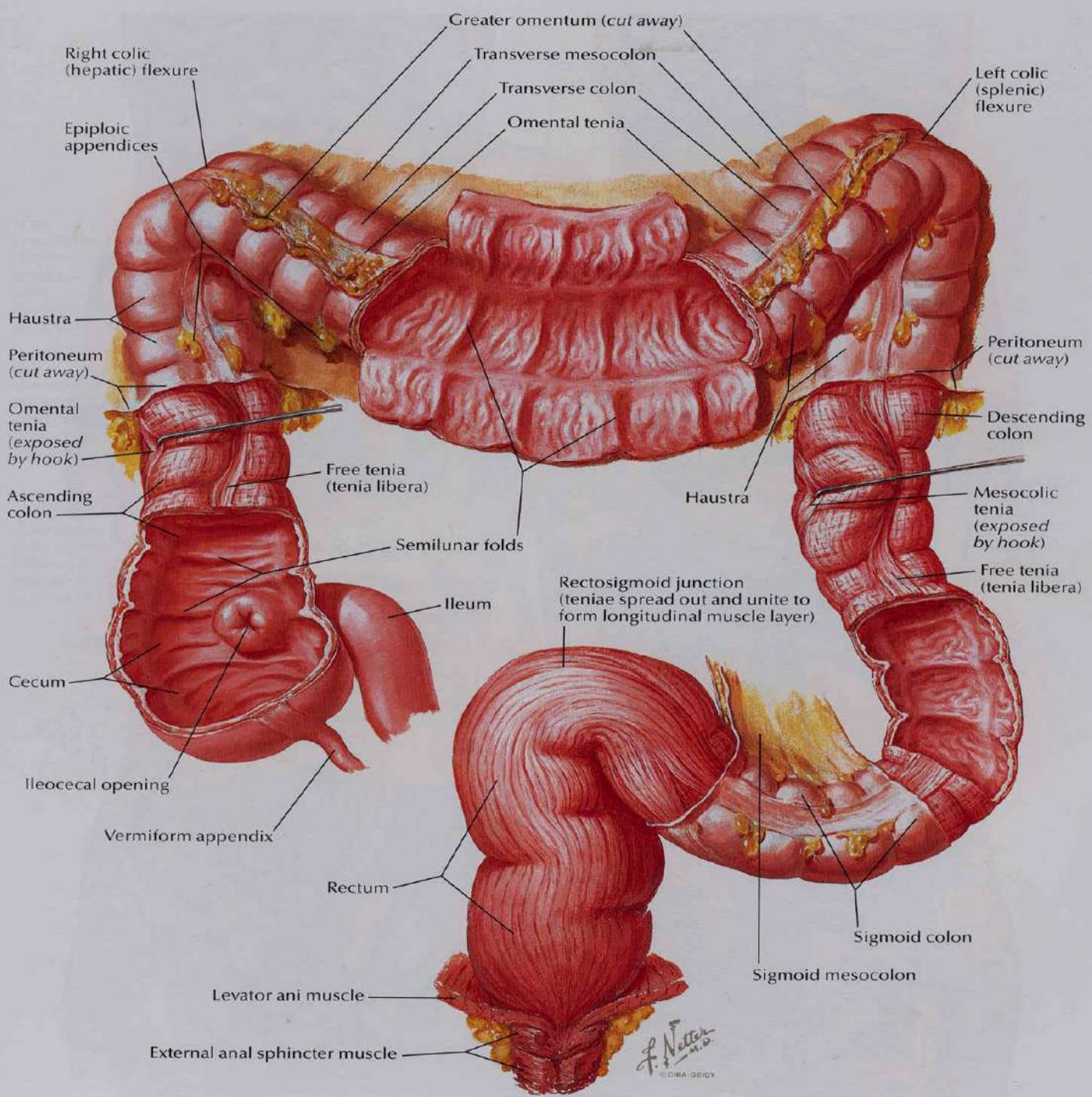
③ Pancreatic duct merges with common bile duct at the hepatopancreatic ampulla.

④ Bile and pancreatic juices enter duodenum at the major duodenal papilla.

Intestine Crassum



(a)



Rectal valve

Rectum

Hemorrhoidal veins

Levator ani muscle

Anal canal

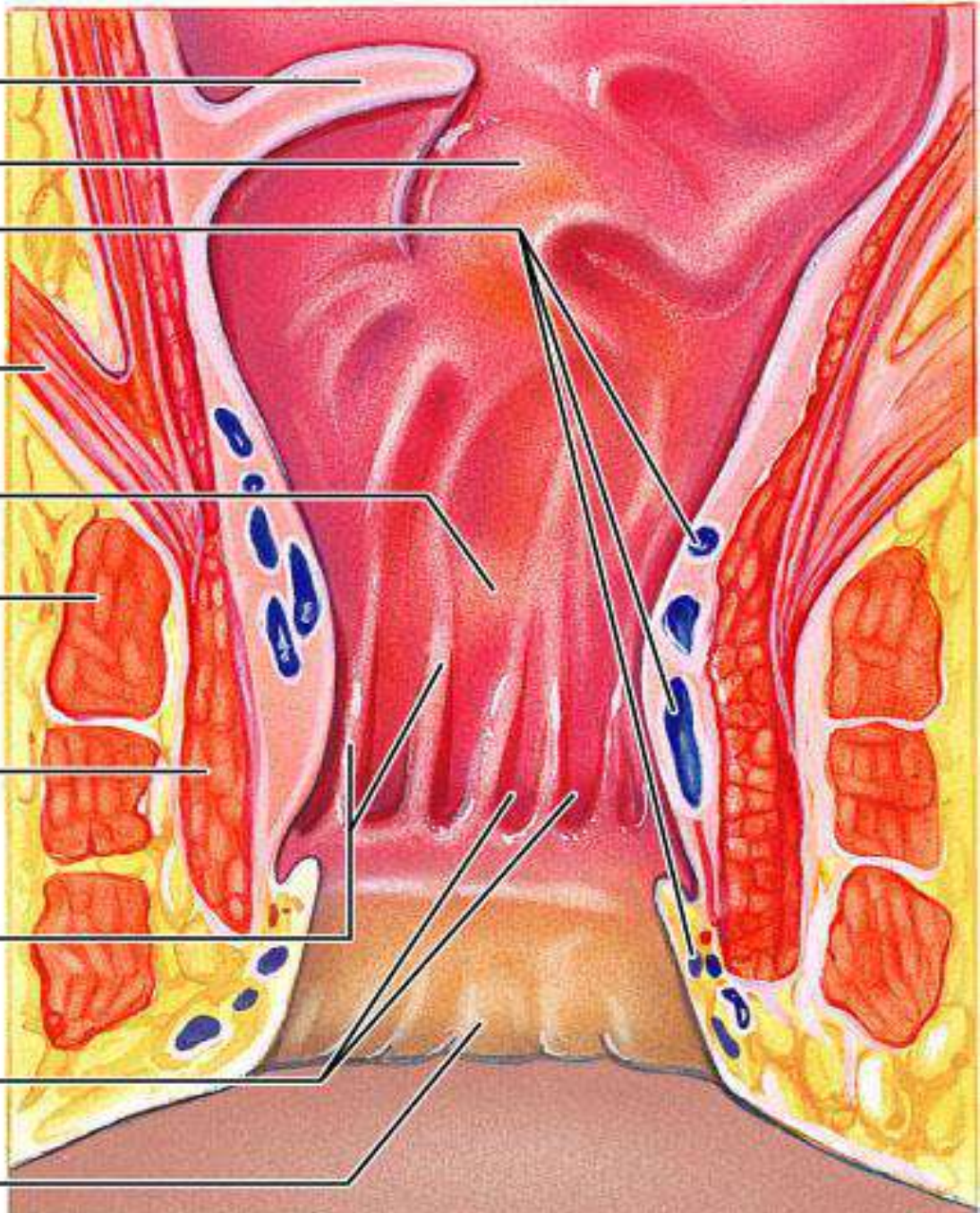
External anal sphincter

Internal anal sphincter

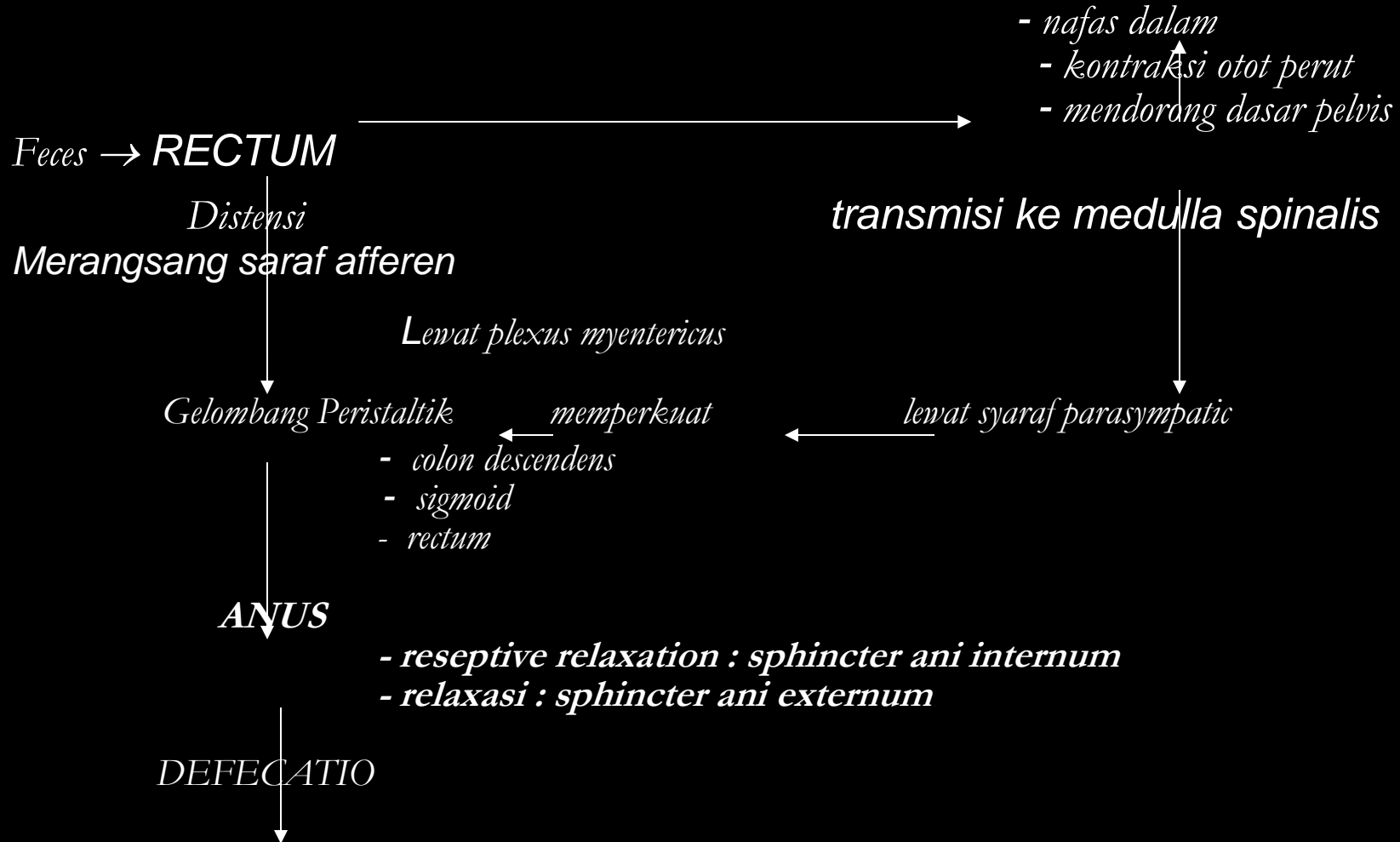
Anal columns

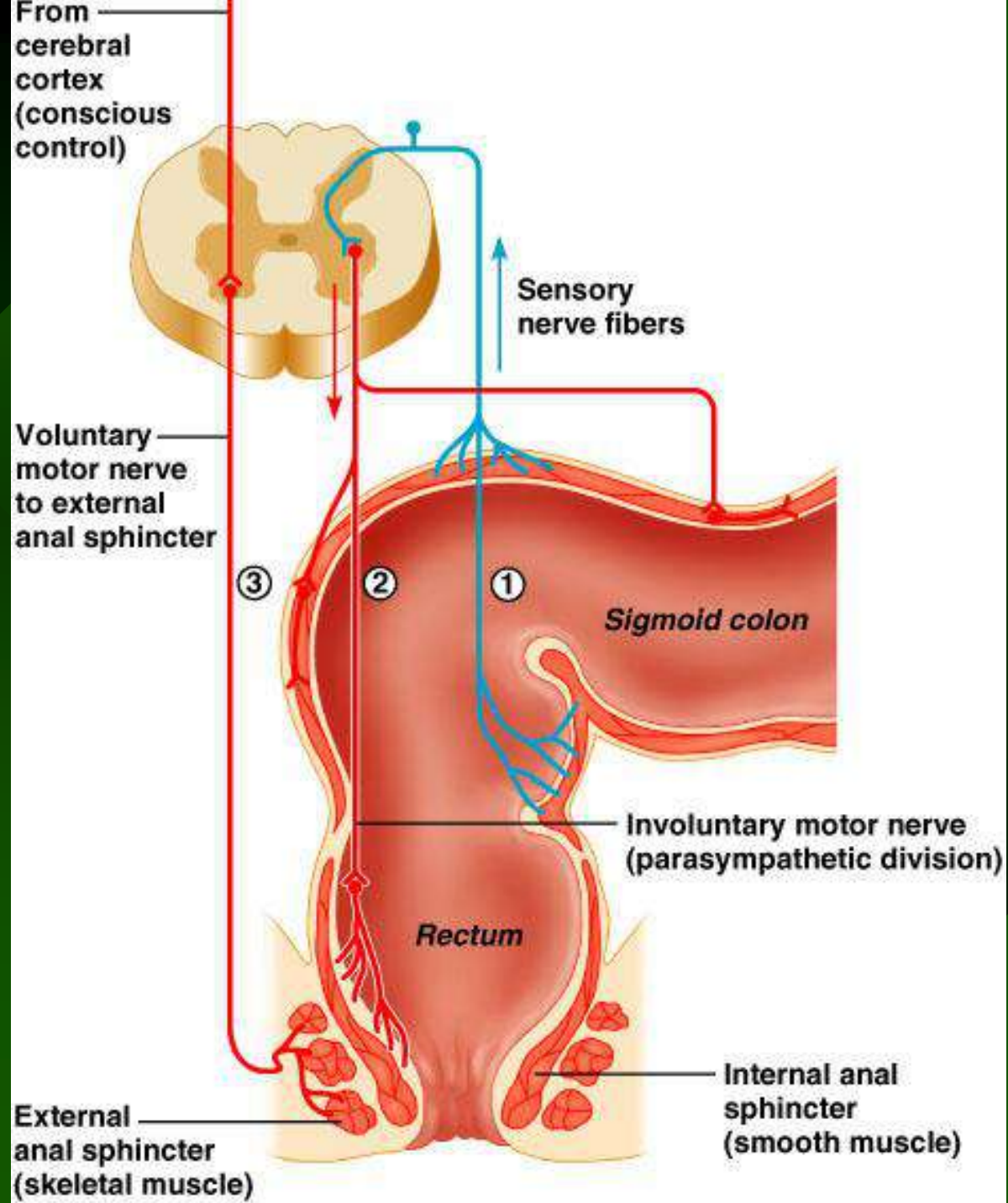
Anal sinuses

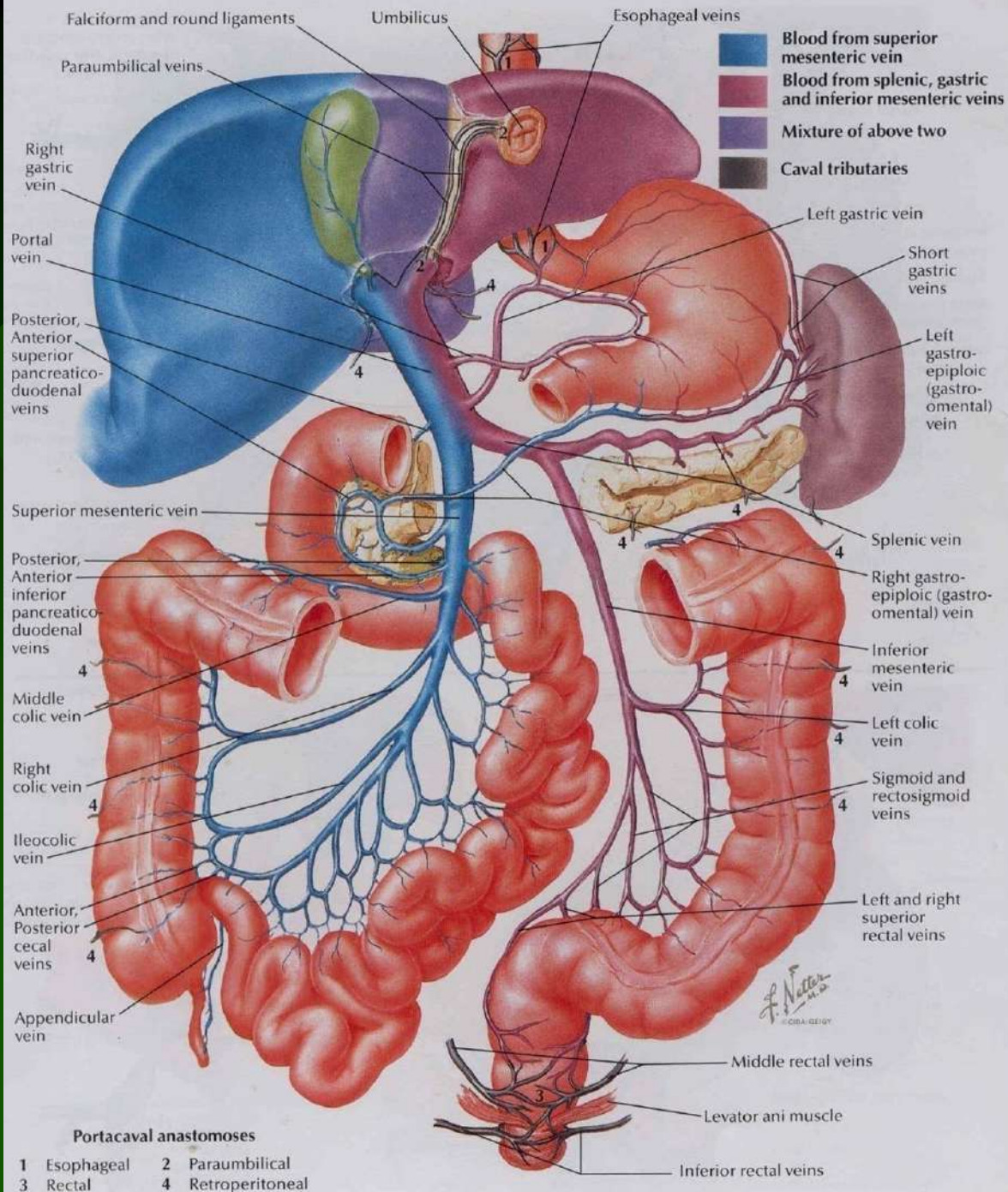
Anus




Reflek Defecatio







**SELAMAT BELAJAR
SEMOGA SUKSES**



INDONESIA

