



# **GEJALA DI BIDANG OBG**

**Dr. Kusuma Andriana SpOG**




GEJALA  
OBG

AMENORE

TUMOR

**PERDARAHAN**

KEPUTIHAN



**AMENORE**

**USIA**

**< 16 TH**  
**Seks 2<sup>nd</sup> (-)**

**> 16 th**  
**3 bl tdk haid**

**PLANO (-)**

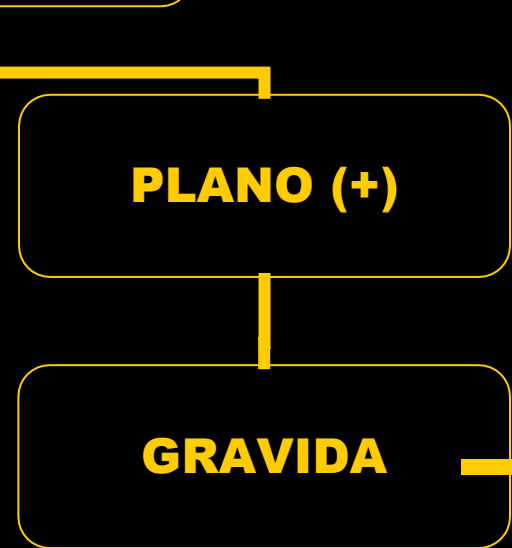
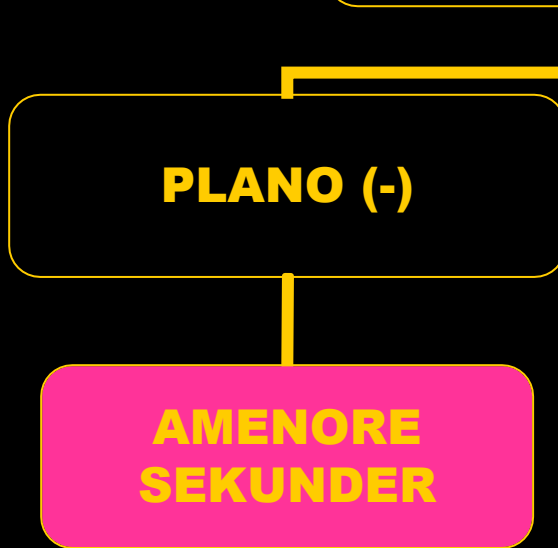
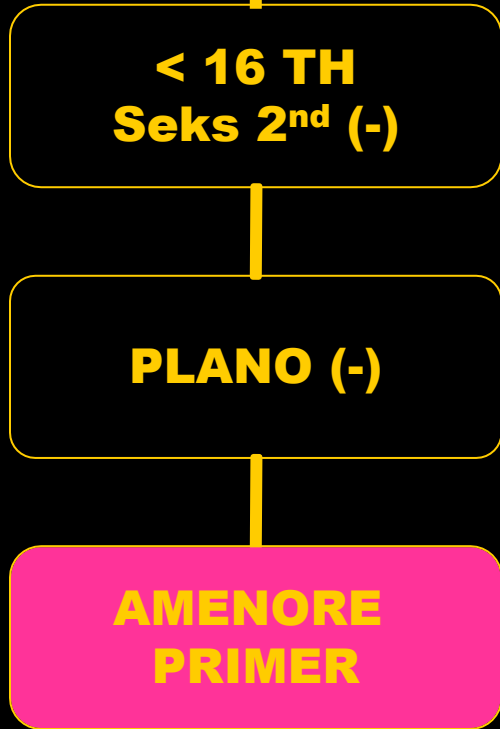
**PLANO (-)**

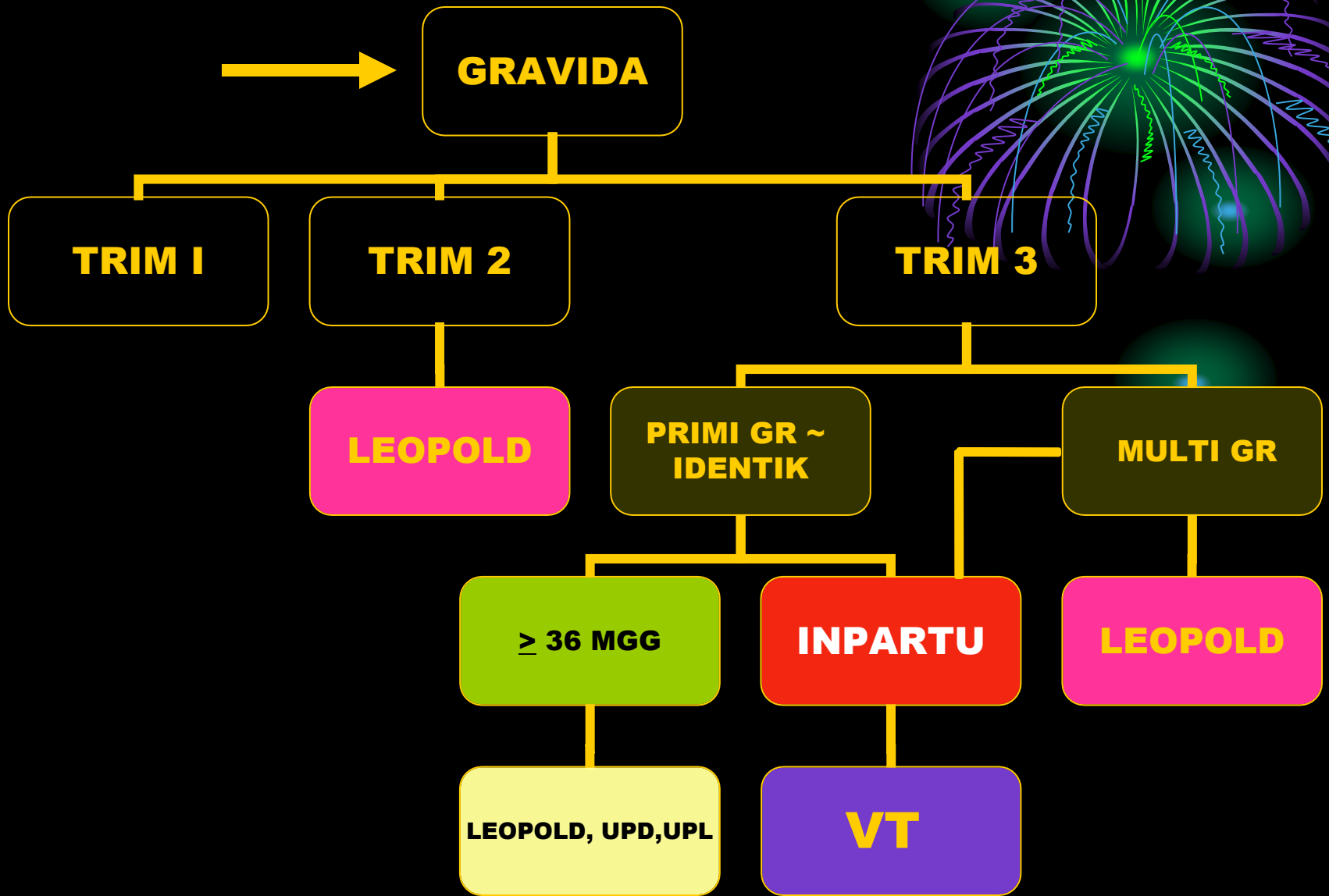
**PLANO (+)**


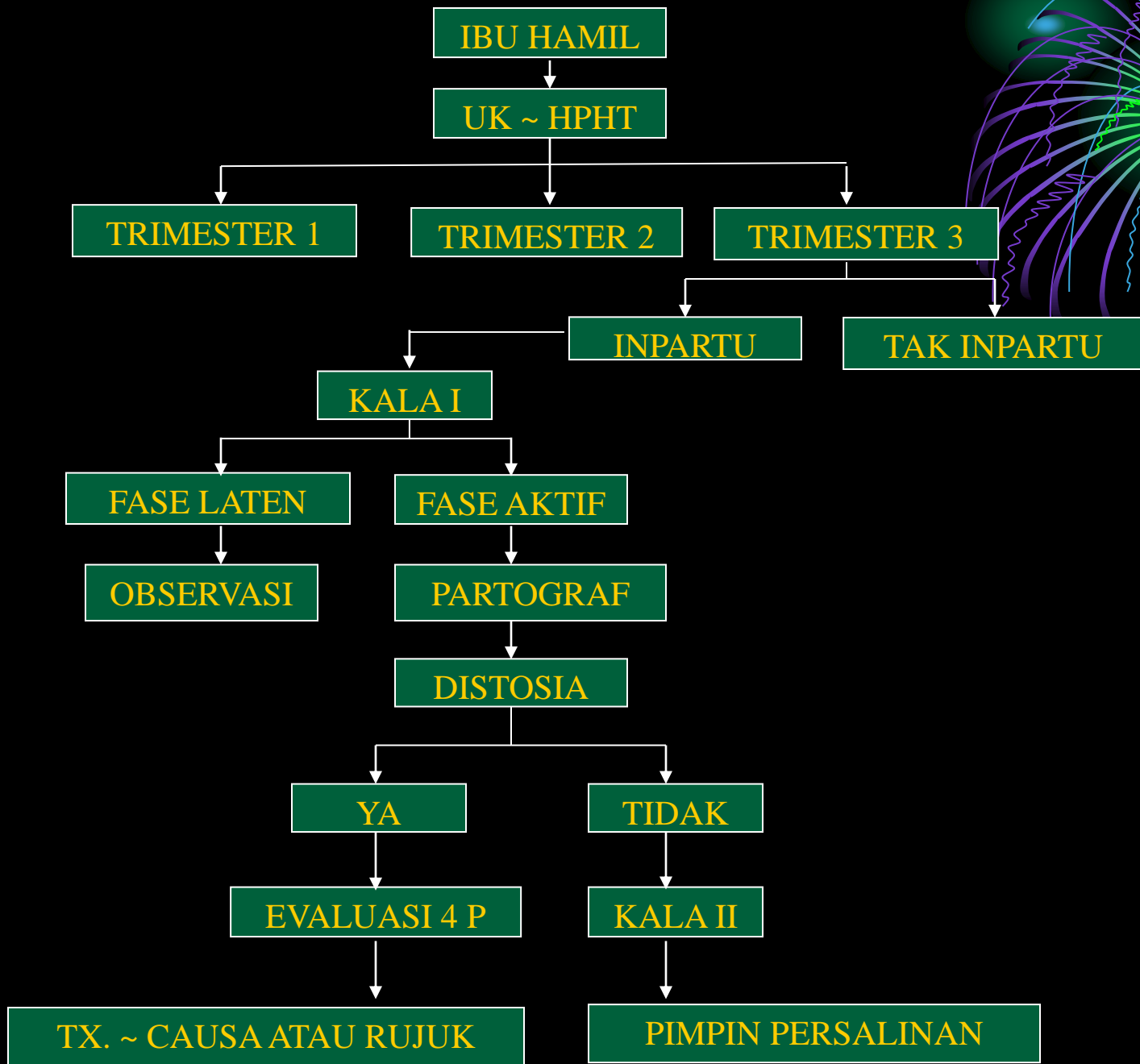
**AMENORE**  
**PRIMER**

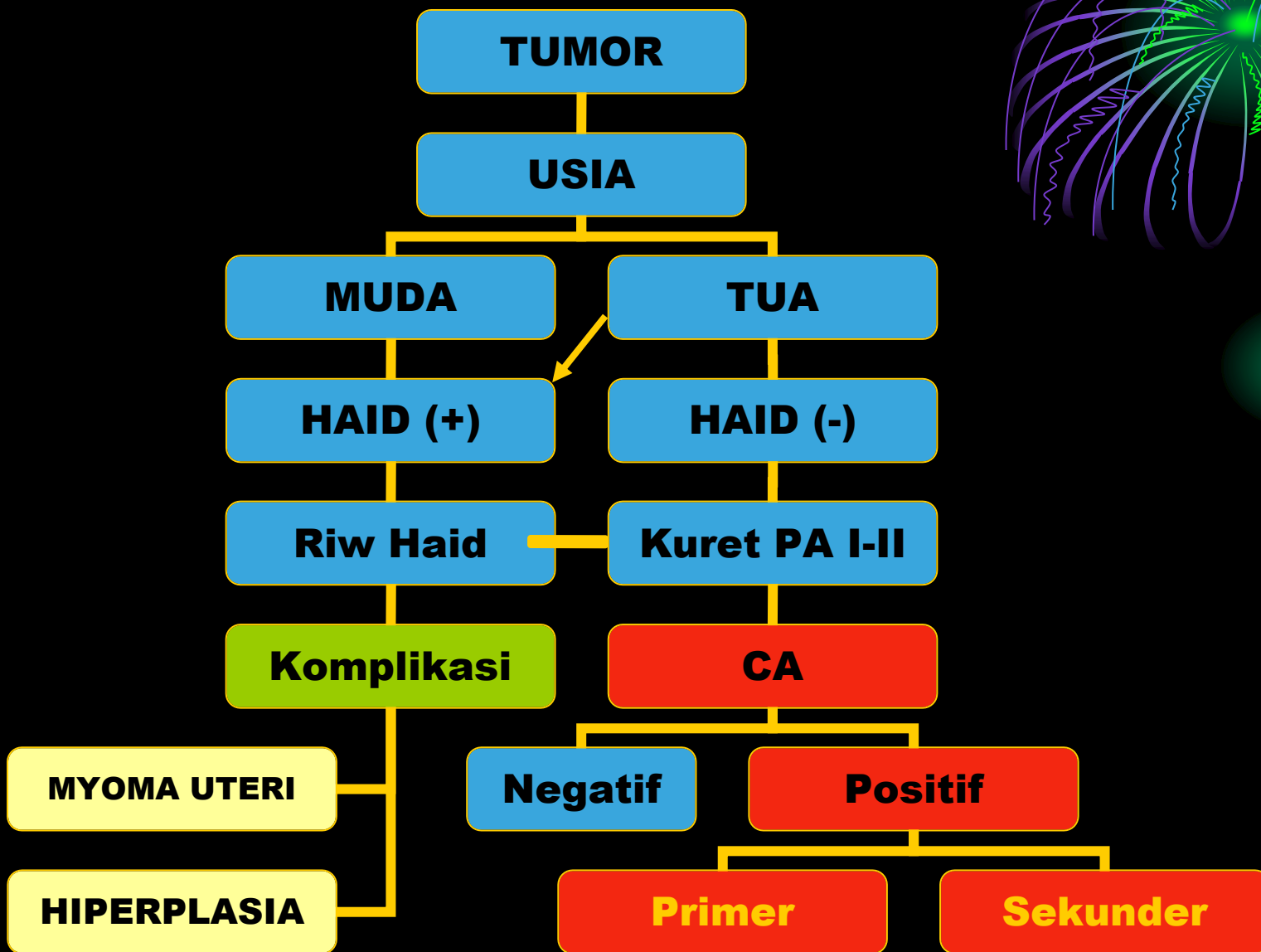

**AMENORE**  
**SEKUNDER**

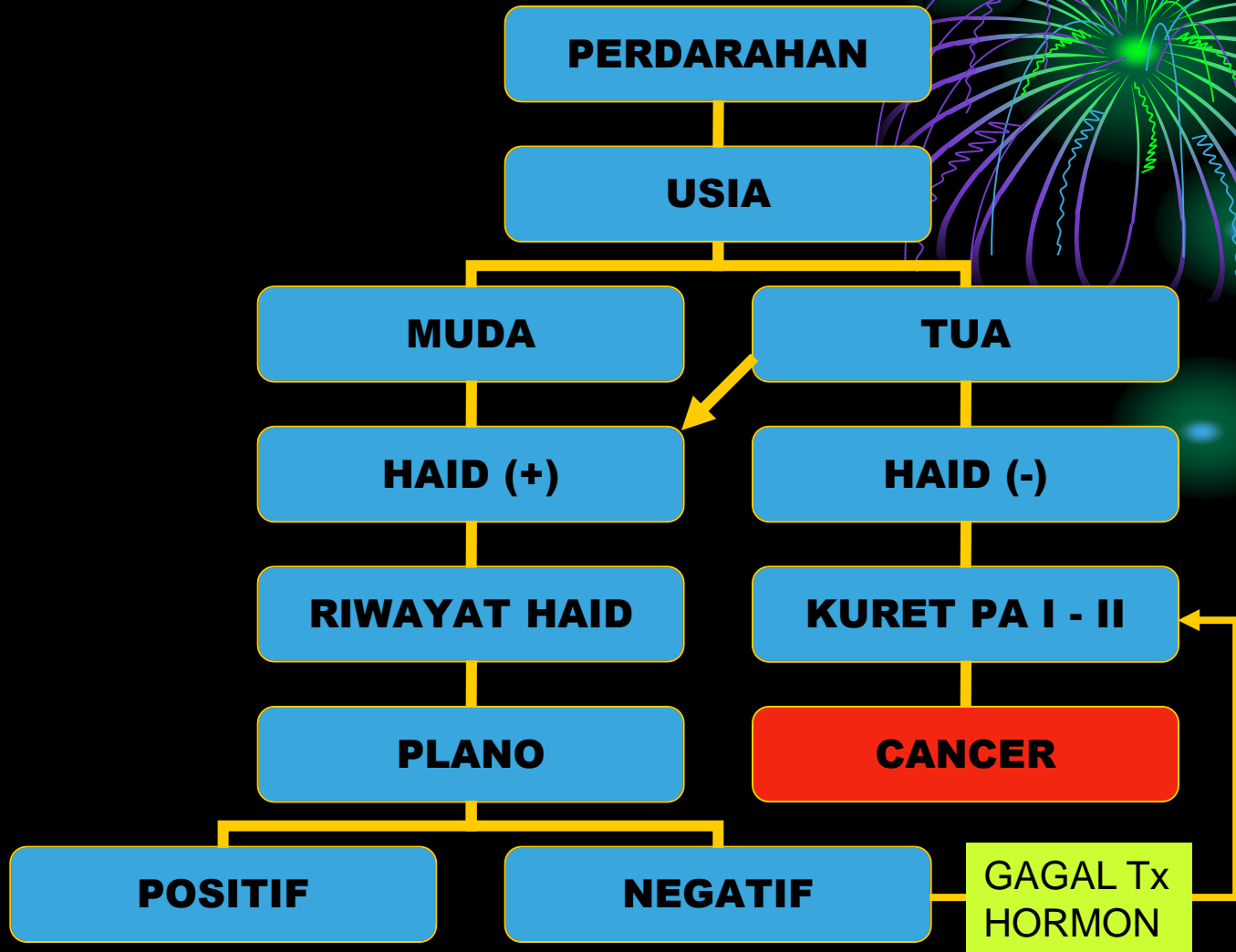
**GRAVIDA** →











# PERDARAHAN

PLANO

POSITIF

NEGATIF

USIA KEHAMILAN

GANGGUAN ORGAN

VT

< 20 MGG

> 20 MGG

TIDAK

YA

VT

~~VT~~

DUB

MYOMA


HIPERPLASIA

ABORTUS



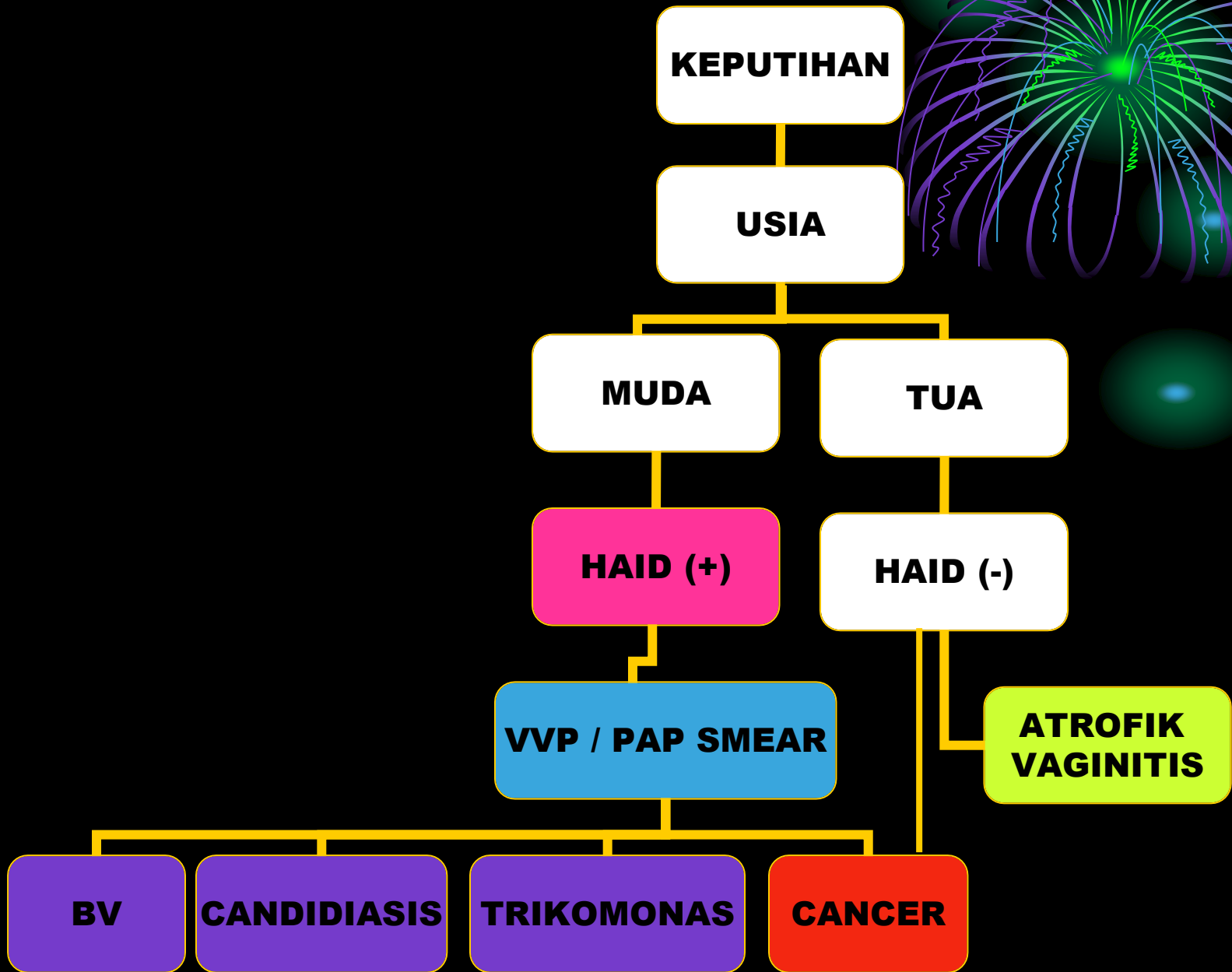
MOLA

KET


GRAVIDA







# INGIN IKUT KB → KONSELING



- **Usia**
- **Lama menikah**
- **Jumlah anak**
- **Siklus haid**
- **Keluhan → keputihan, nyeri haid, perdarahan**
- **RPD → HT, DM, CV, Migrain dll**
- **Riwayat KB sblmnya**
- **INDIKASI & KONTRAINDIKASI**

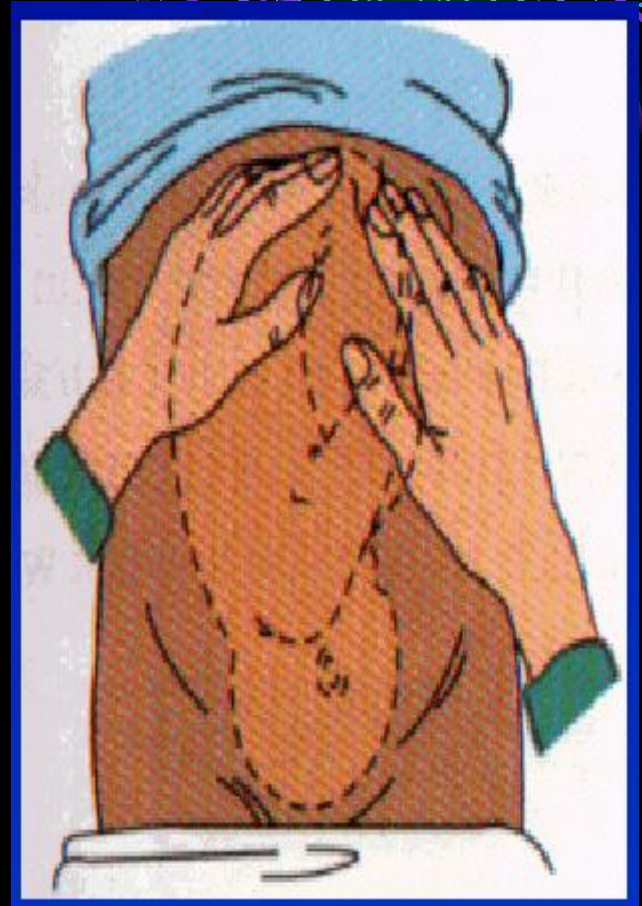# **METODE KONTRASEPSI**



- 1. Metode amenore laktasi**
- 2. KB alamiah**
- 3. Sanggama terputus**
- 4. Metode barrier**
- 5. Kontrasepsi kombinasi**
- 6. Kontrasepsi progestin**
- 7. AKDR**
- 8. Kontrasepsi mantap**

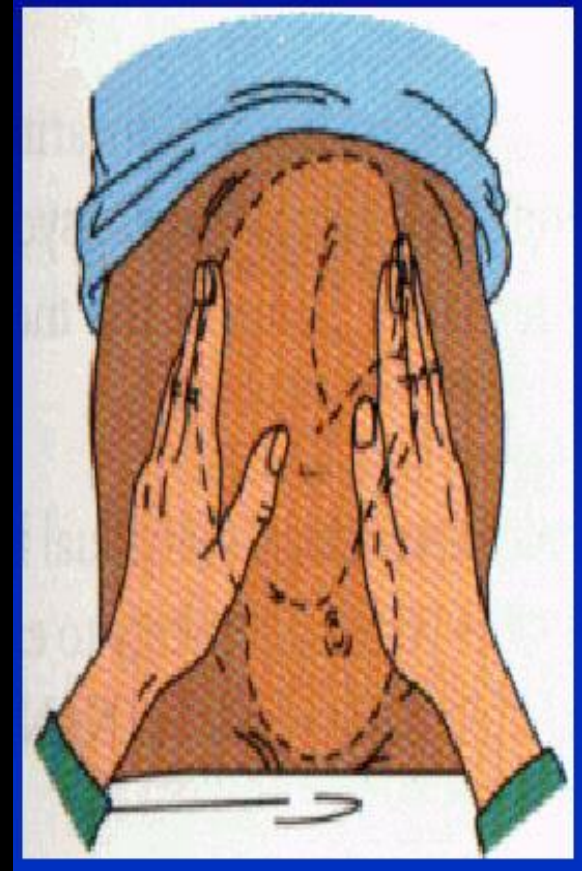
# PEMERIKSAAN LEOPOLD I

- **Dr di kanan Px, hadap ke kepala Px**
- **2 Telapak tangan di FU tentukan**
  - **Tinggi FU**
  - **Letak janin (kepala or bokong or bag kecil)**



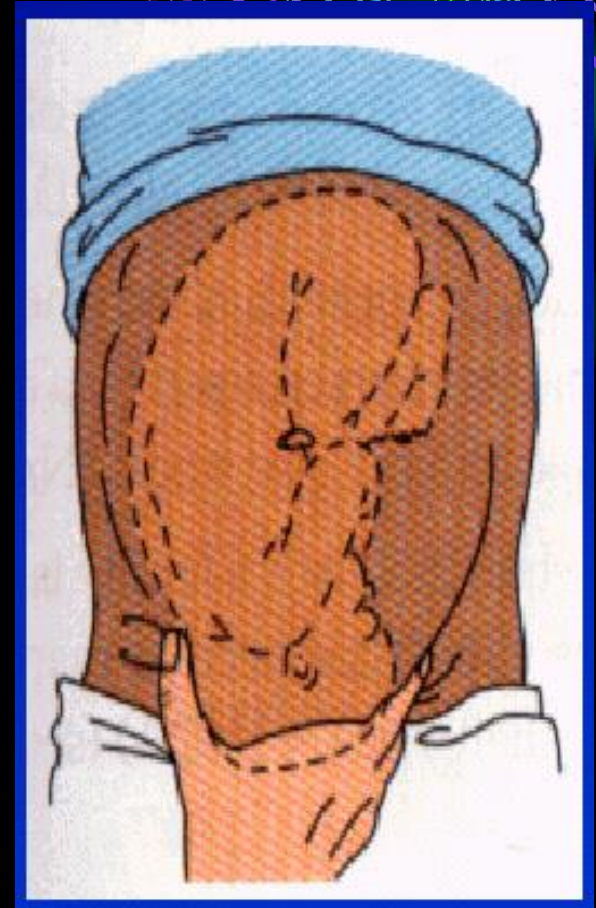
# LEOPOLD II

- **Dr. di kanan Px hadap ke perut ibu**
- **Tentukan letak punggung & bag kecil**
- **Pada let li → teraba kep or bokong**



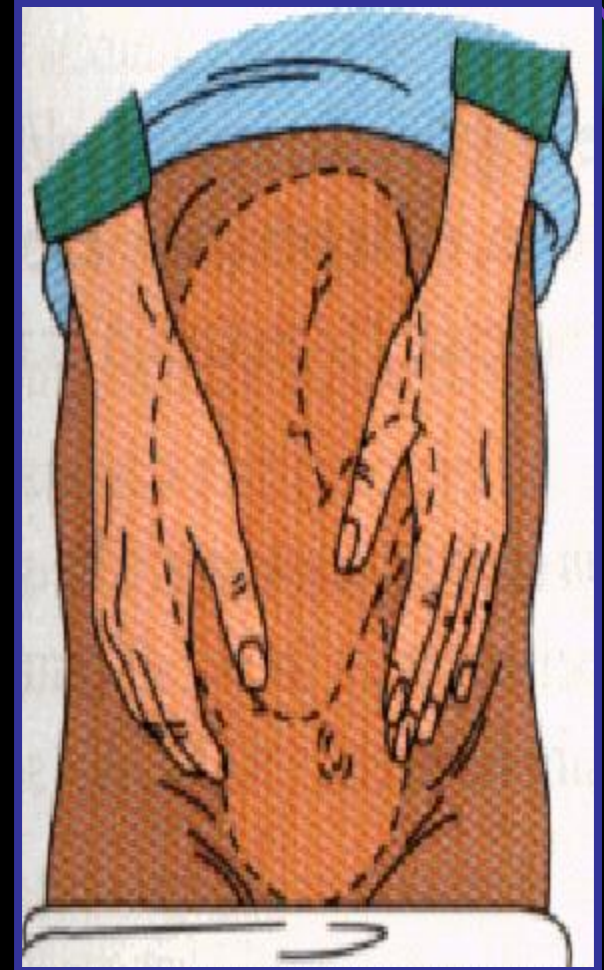# LEOPOLD III

- **Dr. di kanan Px menghadap ke perut Px**
- **Untuk tentukan**
  - **Bag terndah**
  - **Masuk PAP or not**



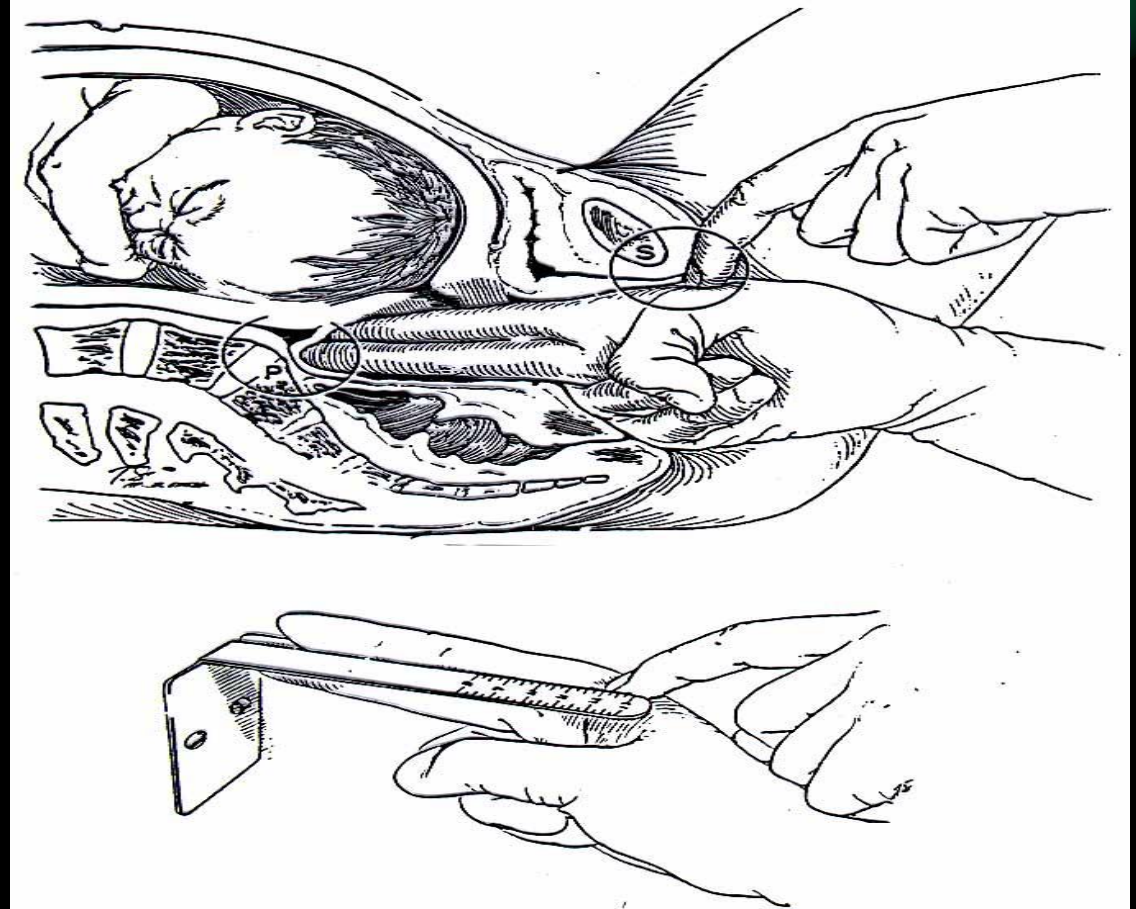
# LEOPOLD IV

- **Dr. di kanan Px, hdap ke kaki ibu**
- **Menggunakan 2 tangan**
- **Untuk tentukan :**
  - **Bag terendah**
  - **Sudah masuk**
  - **Seberapa jauh masuknya**
- **Dilakukan pada UK > 24 mwg**



# PEMERIKSAAN PANGGUL DALAN


Mengukur panggul dalam sebagian dapat dilakukan dengan pemeriksaan dalam.





- **Pintu Atas Panggul**

- **Dibentuk oleh .....**
- **Conjugata vera (atas simf – promontorium)  $\pm$  11 cm**
- **Konjugata diagonalis : CV – 1,5 cm (bawah simf - promontorium)**




- **Pintu Tengah Panggul**

- **Sakrum** → cekung / datar
- **Spina Ischiadika** → menonjol / tidak

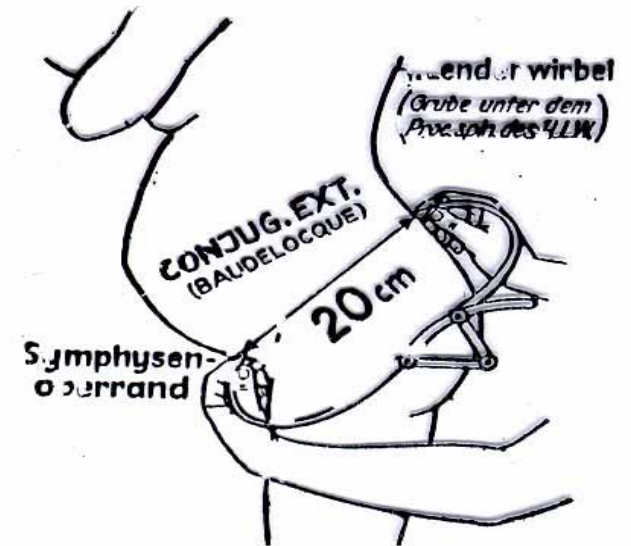
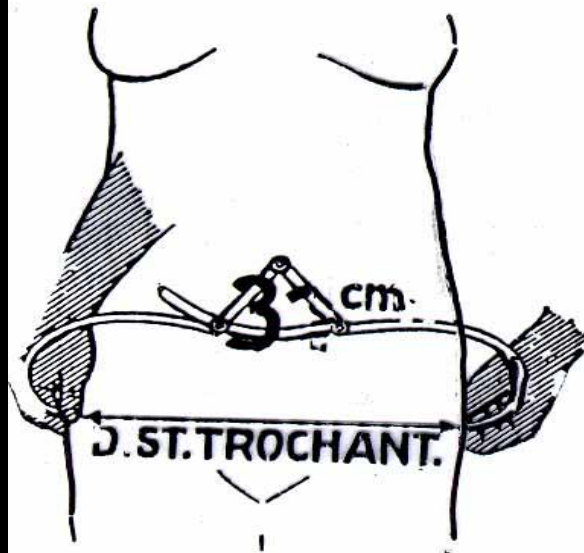
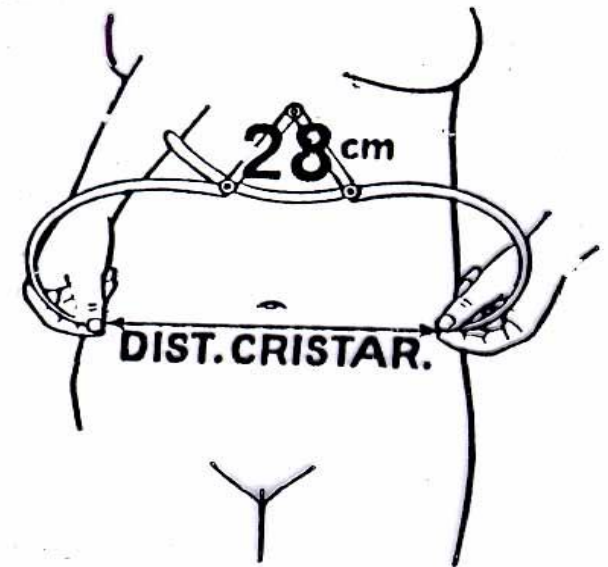
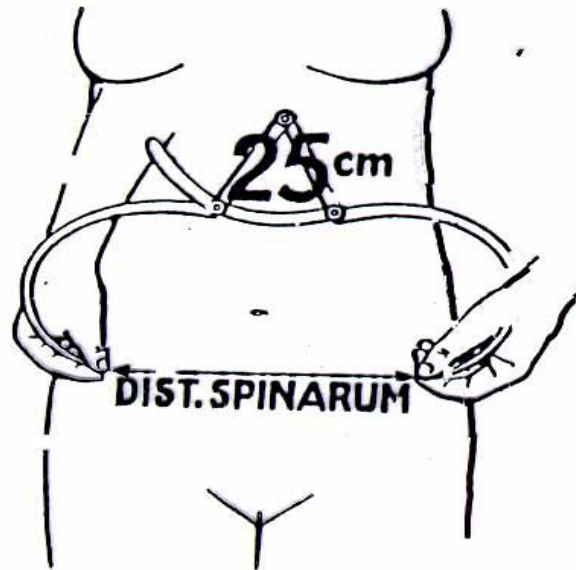
- **Pintu Bawah Panggul**

- **Arcus pubis** → + 90°
- **Diatansia tuberum** → 10, 5 cm (jarak tuber os osii D -S)



# PEMERIKSAAN PANGGUL BESAR

Pemeriksaan  
luar dengan  
menggunakan  
jangka Martin





- **Distansia spinarum ( $\pm$  24-26 cm) :**
- **Jarak antara SIAS D - S**
- **Distansia kristarum ( $\pm$  28-30 cm):**
- **Konjugata eksterna  $\pm$  18 cm**
- **Jarak antara simf – proc spinosus 5**


## UKURAN PANGGUL LUAR

- \* **Distansia Cristarum: 20-28 cm**
- \* **Distansia Spinarum: 24-26 cm**
- \* **Conjugata Externa Boudeloque  
18 cm**
- \* **Lingkaran Panggul: 80 cm**




## UKURAN PANGGUL DALAM

- \* **Conjugata vera = 11,5 cm**  
**CV = CD - 1,5 cm**
- \* **Diameter Transversa (12,5 - 13 cm)**
- \* **Diameter Obliqua (13 cm)**
- \* **Distansia Tuberum (10,5 cm)**
- \* **Arcus Pubis (> 90°)**




**PEMERIKSAAN GINEKOLOGI**

# ANAMNESA



- **Keluhan utama**
- **Riwayat Haid (durasi, frek, interval, HPHT)**
- **Riwayat Obs (Para, Ab, Mola, KE)**
- **Riwayat Gyn (op, keputihan dll)**
- **Riwayat KB**
- **Mitra seks**

# Pemeriksaan Fisik

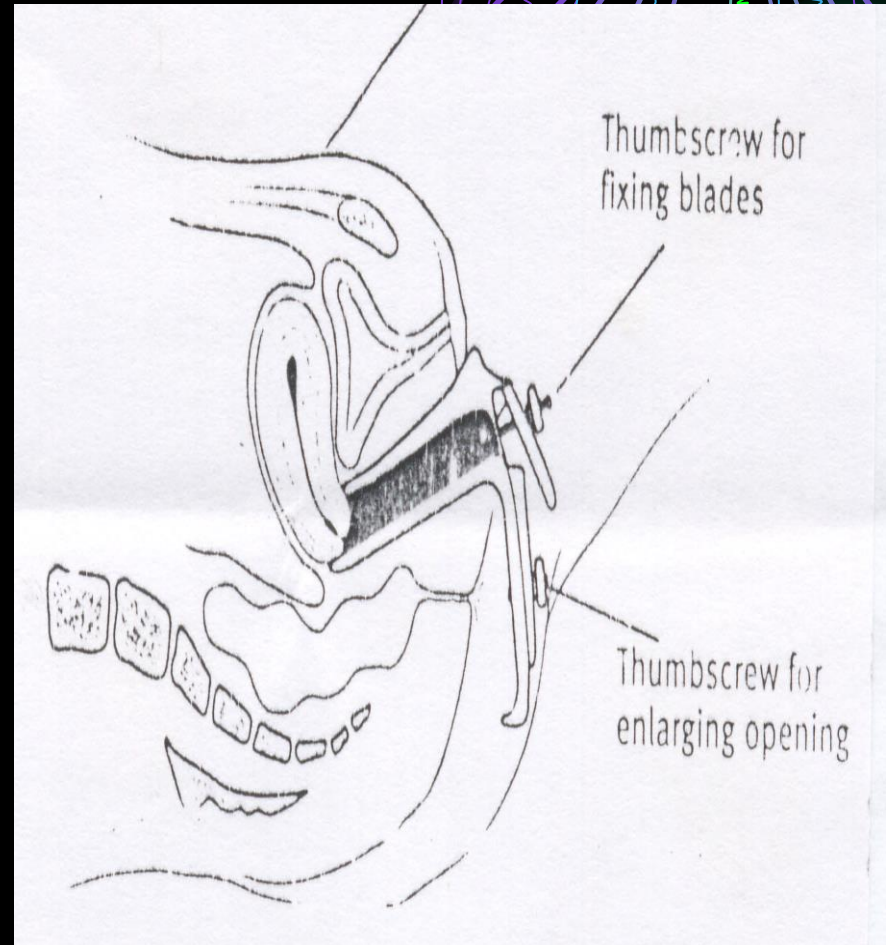


- **Kosongkan VS**
- **Jelaskan rencana DP**
- **Pemeriksaan scr. General**
- **Pemeriksaan payudara**
  - **Inspeksi → berdiri, lengan disamping**
  - **Palpasi → berbaring dan duduk, lengan diatas kepala**



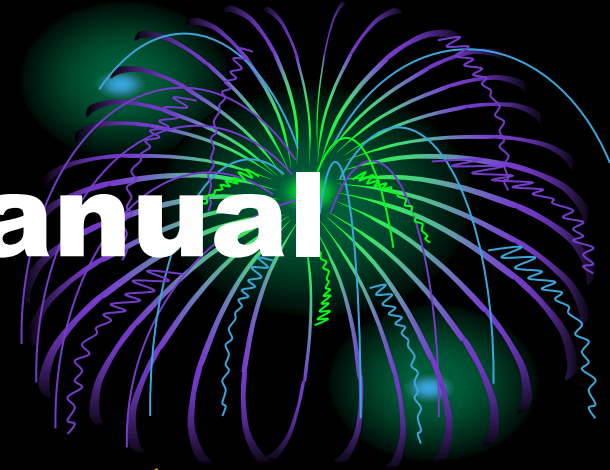# Pemeriksaan Pelvis

- **Posisi → lithotomi**
- **Inspeksi**
  - **Gen ekst**
  - **Pemeriksaan spekulum**

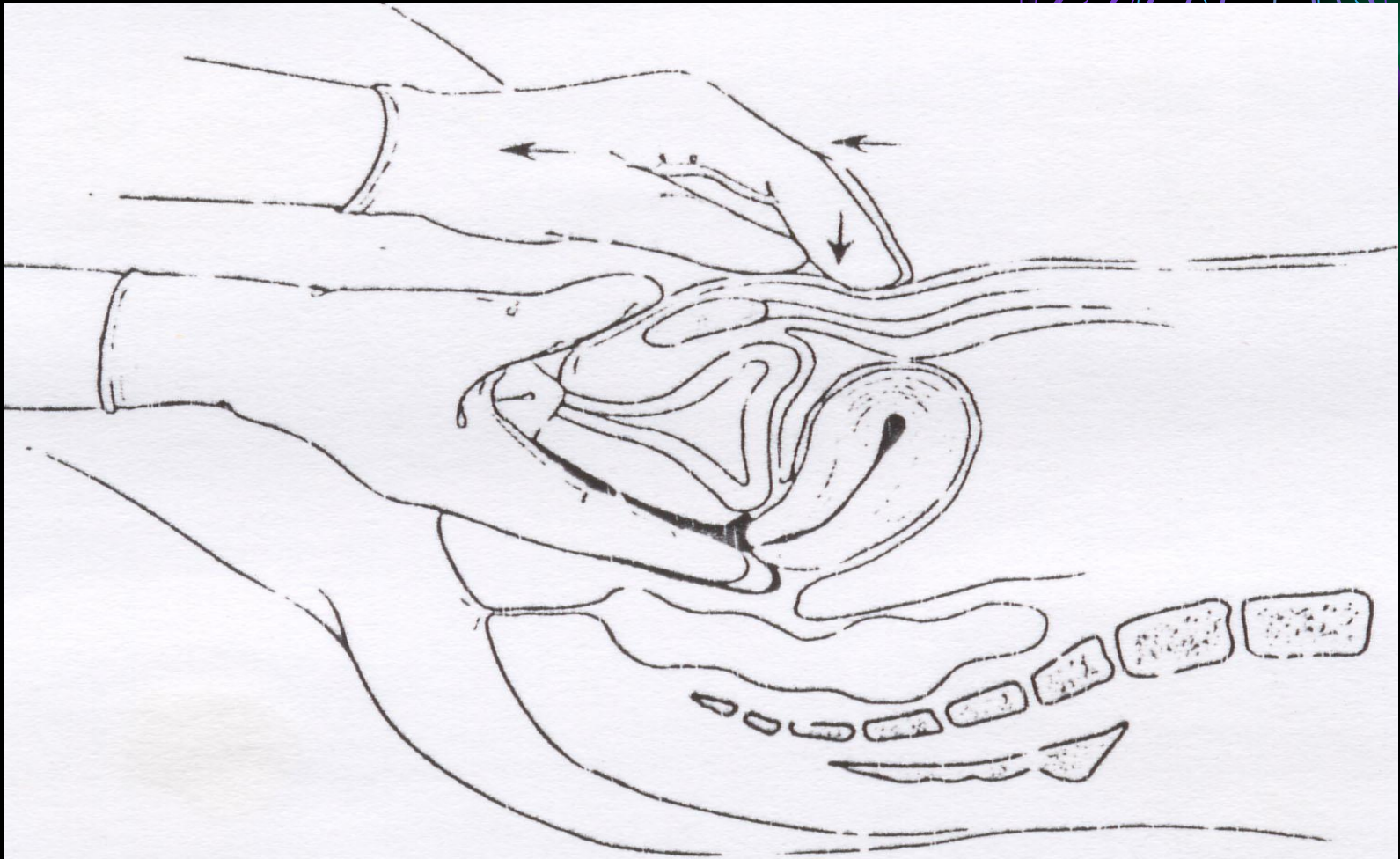
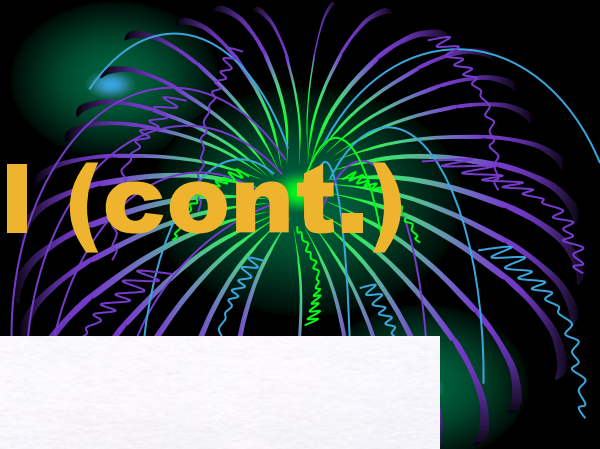

# Pemeriksaan Bimanual

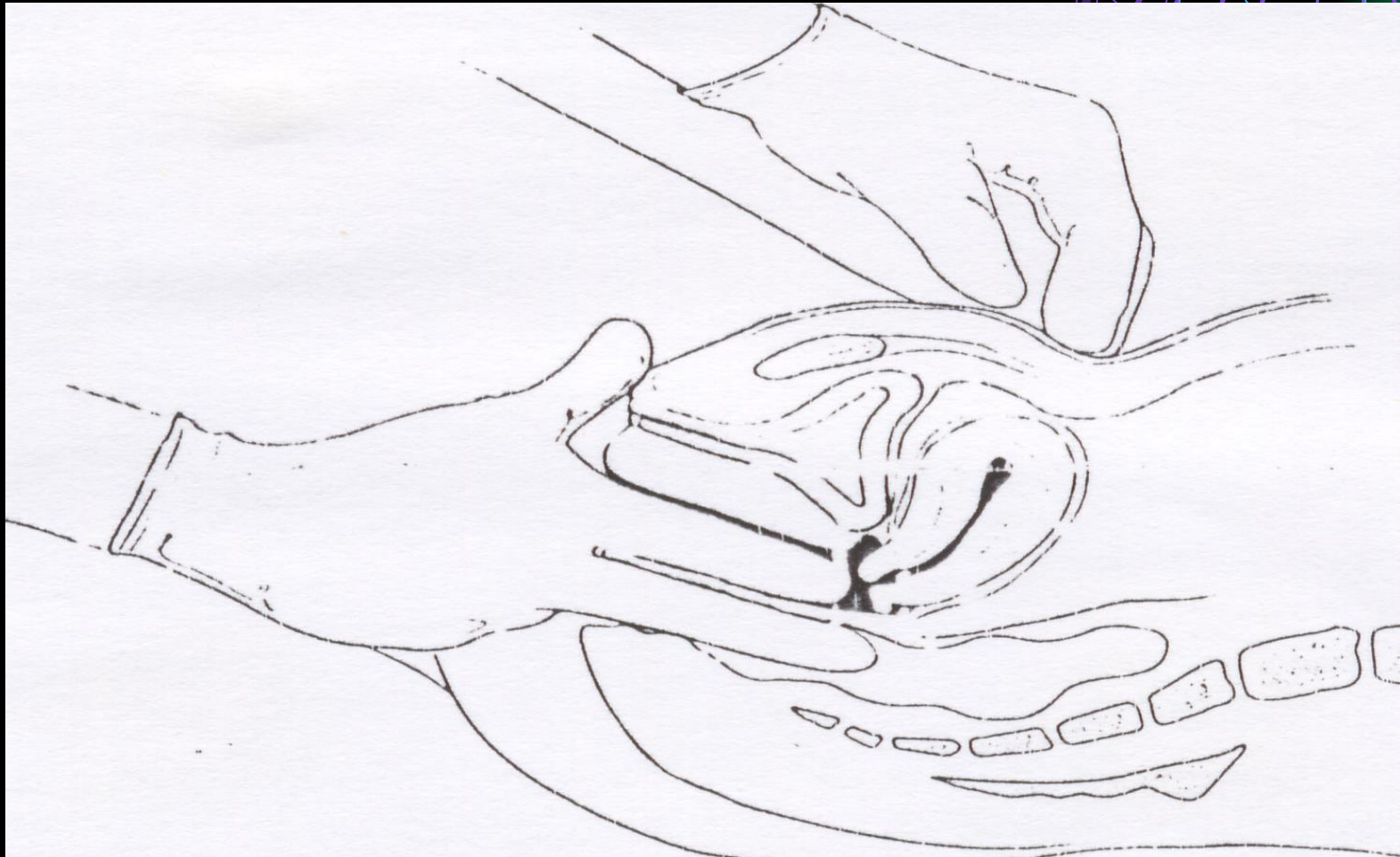

- **Untuk px yg sdh menikah**
- **Dua jari tangan kanan di vagina, tangan kiri di abdomen diatas symfisis**
- **Pemeriksaan organ pelvis**
  - **Serviks → bentuk, ukuran, mobilitas, nyeri, massa**
  - **Uterus → bentuk, ukuran, mobilitas, nyeri, massa, Ante/retro fleksi, konsistensi**
- **Adneksa → D-S, massa, nyeri, perlekatan**




# Pemeriksaan Bimanual (cont.)



# Pemeriksaan Rektovaginal



# Laporan



**Ny. X usia .... P.... ... A..... Anak terkecil usia..... th**

**Menikah ....kali selama. HPHT .....**

**KB :**

**Inspeksi : Vulva vagina : fluor / flek / fluksus / massa**

**Inspekulo : Vulva vagina : fluor / flek / fluksus / massa**

**Portio : licin/tidak; massa bentuk dan ukuran,**

**Fluor, filamen AKDR +/-**

**Ostium uteri eksternum terbuka / tertutup**

**VT : Vulva vagina : fluor / flek / fluksus / massa**

**Portio : licin/tidak; massa bentuk dan ukuran,**

**Fluor, filamen AKDR +/-**


**Ostium uteri eksternum terbuka / tertutup**

**Uterus : ukuran, bentuk, posisi (ante atau retrofleksi)**

**Adneksa Parametrium Dekstra : nyeri + / - massa + / -  
(deskripsikan)**

**Sinistra : nyeri + / - massa + / -  
(deskripsikan)**

**Cavum Duoglas : massa (deskripsi), nyeri**



**TERIMA KASIH**

**Wassalamu'alaikum Wr Wb**