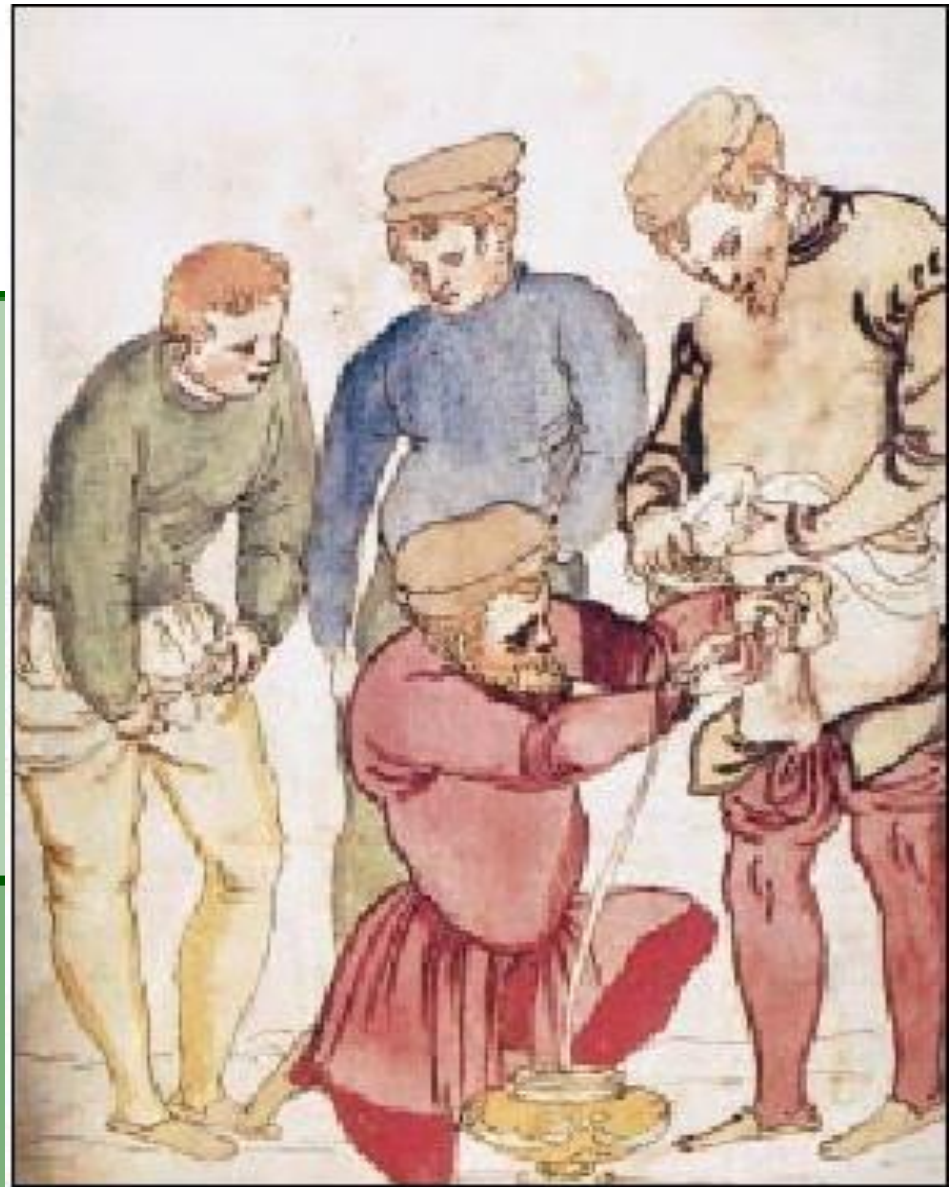



KATETERISASI

dr. Ruby Riana, SpBP

Universitas Muhammadiyah Malang

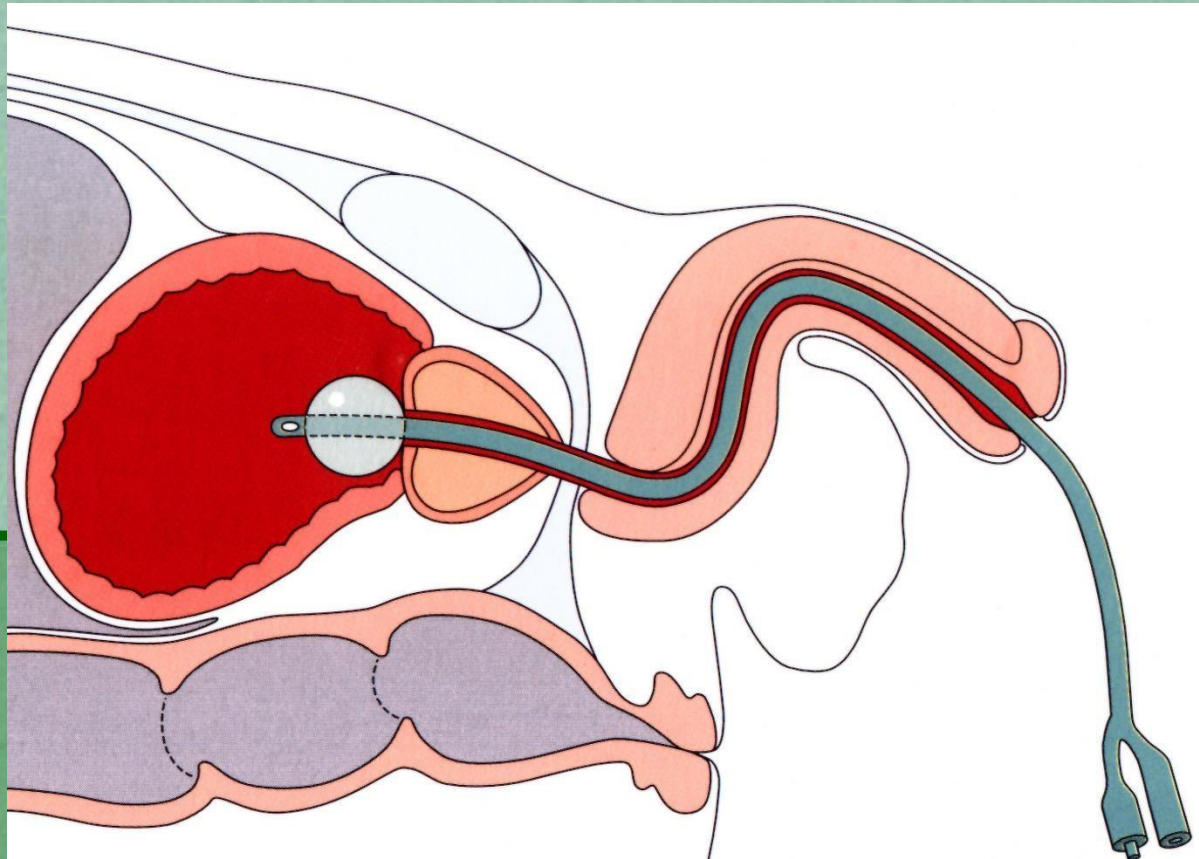


Catheter treatment from an Italian medical picture book by Henricus Kullmaurer and Albert Meher, 1510

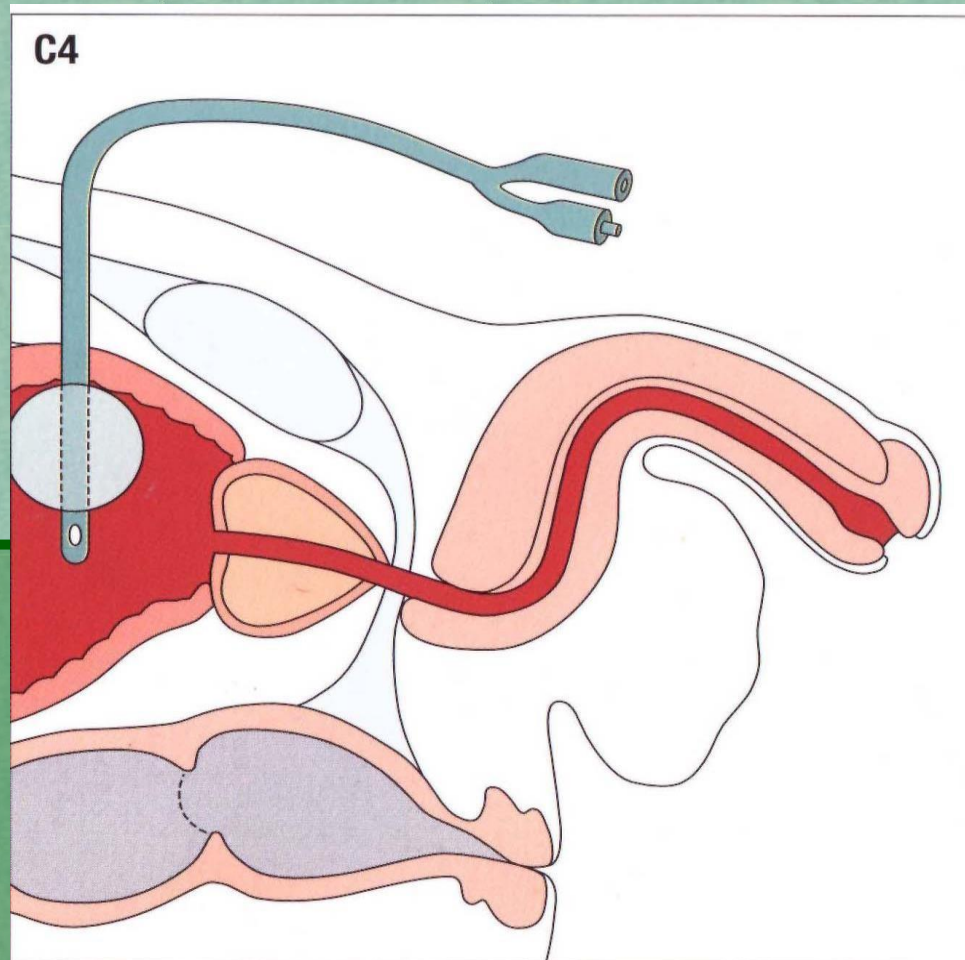
KATETERISASI SALURAN KEMIH **(Urinary Catheterization** **/Introducing catheter in urinary** **tract)**

- Kateterisasi uretra
- Kateterisasi suprapubik
- Kateterisasi ureter
- Kateterisasi renal (nefrostomi)

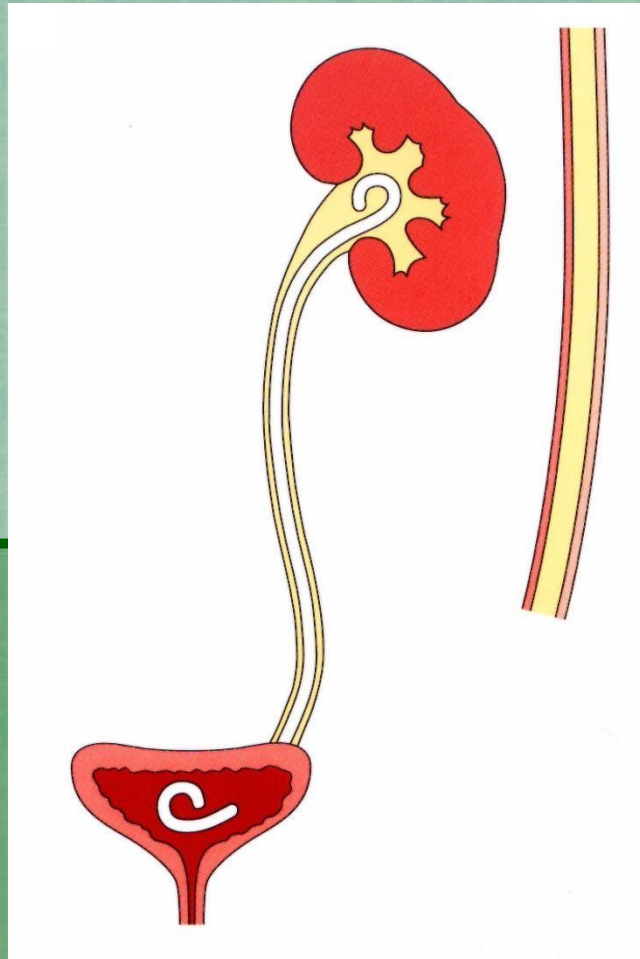
Kateterisasi Uretra



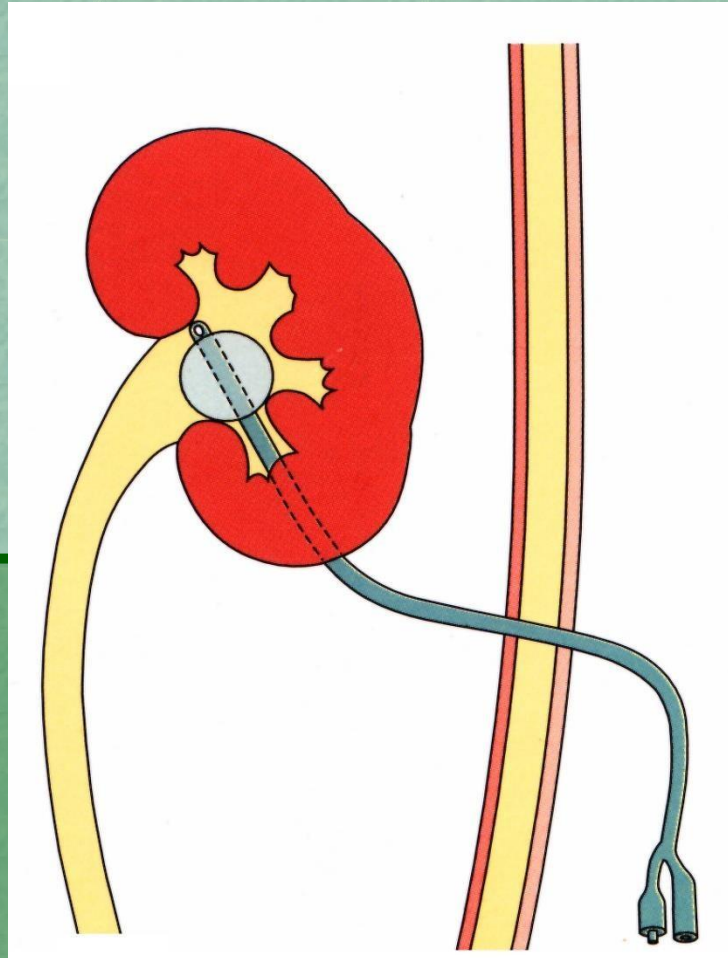
Kateterisasi Suprapubik (sistostomi)



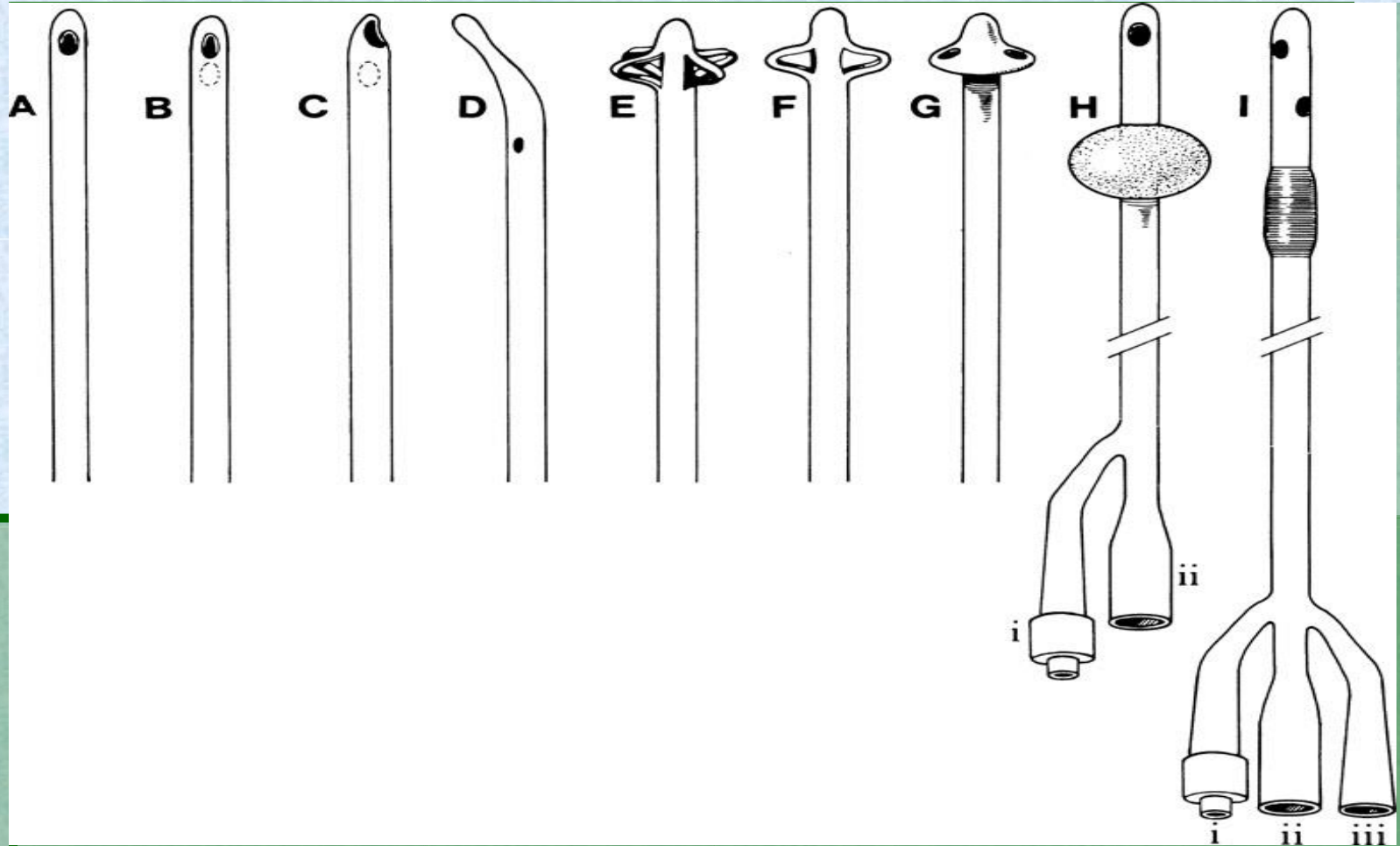
Kateterisasi Ureter (Double J /pig tail catheter)



Kateterisasi Renal (Nefrostomi)




Tipe kateter



Pezzer-Casper-Malecot self retaining catheter



Tiemman tip catheter



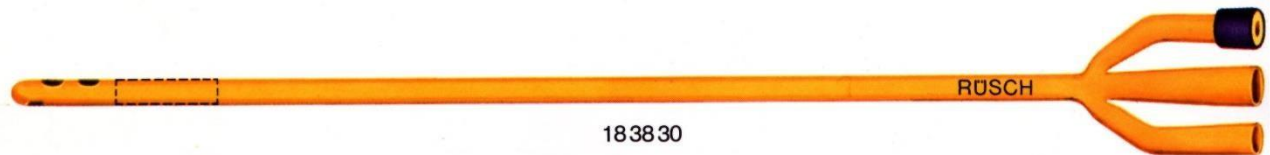
Kateter Foley (2-way and 3-way)



183530



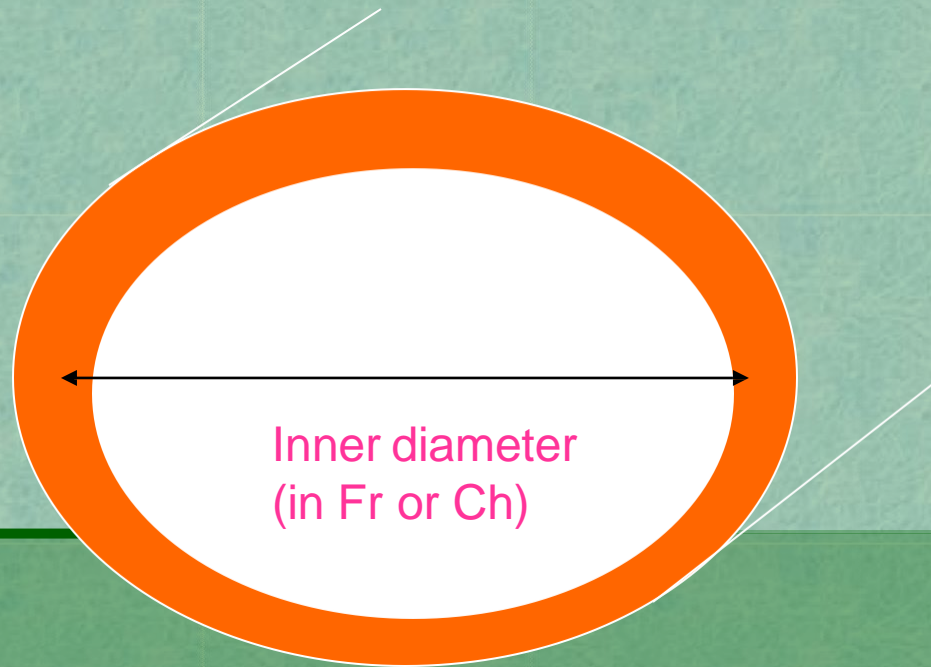
183630



183830



Ukuran Kateter



1 French (Cheriere) = 0.33 mm

KATETERISASI URETRA



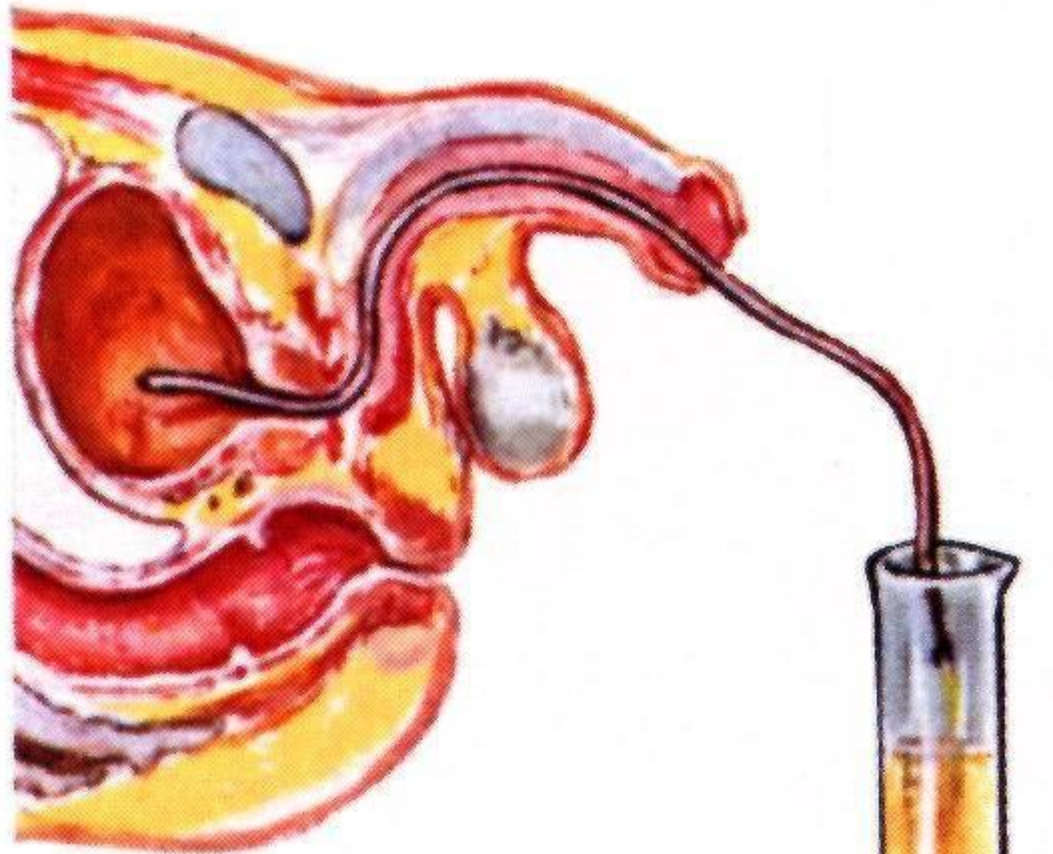Indikasi :

Diagnosis

Terapi

- Sampel urin u/ kultur urin ♀
- Pengukuran *post voiding residual urine*
- Instilasi bahan kontras u/ sistografi
- *Urodynamic study*
- Pengukuran tekanan intravesika

- **Mengatasi obtruksi infravesika**
- **Stenting uretra**
- **Kateterisasi berkala**



**2: #16 FRENCH CATHETER
PASSED; RESIDUAL
URINE MEASURED**

CYSTOMETRY

GRADUATED
RESERVOIR
(STERILE
WATER)



METER
STICK

MANOMETER
TUBE



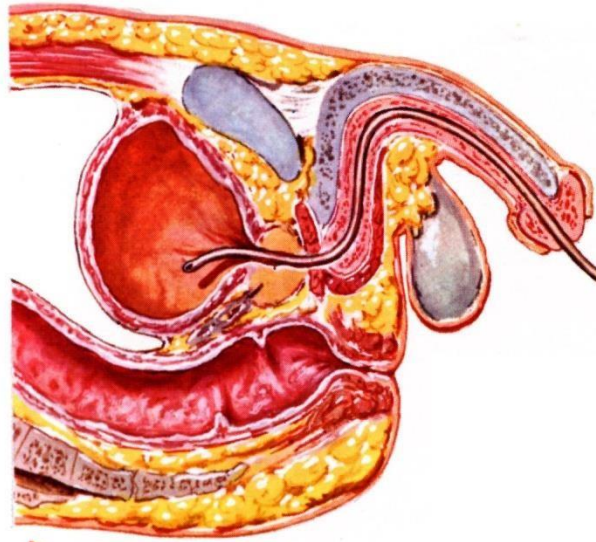
CLAMP TO
ADJUST
FLOW

MURPHY
DRIP

HEMOSTAT
TO STOP
FLOW

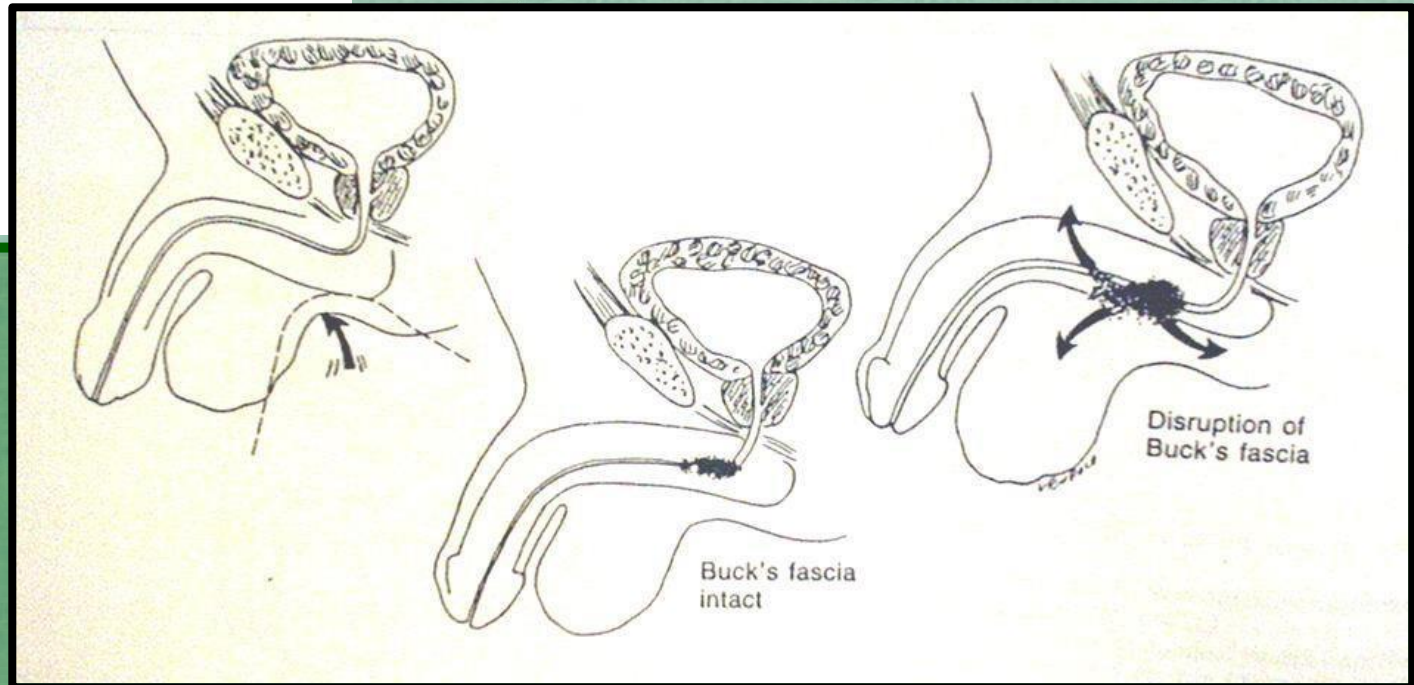
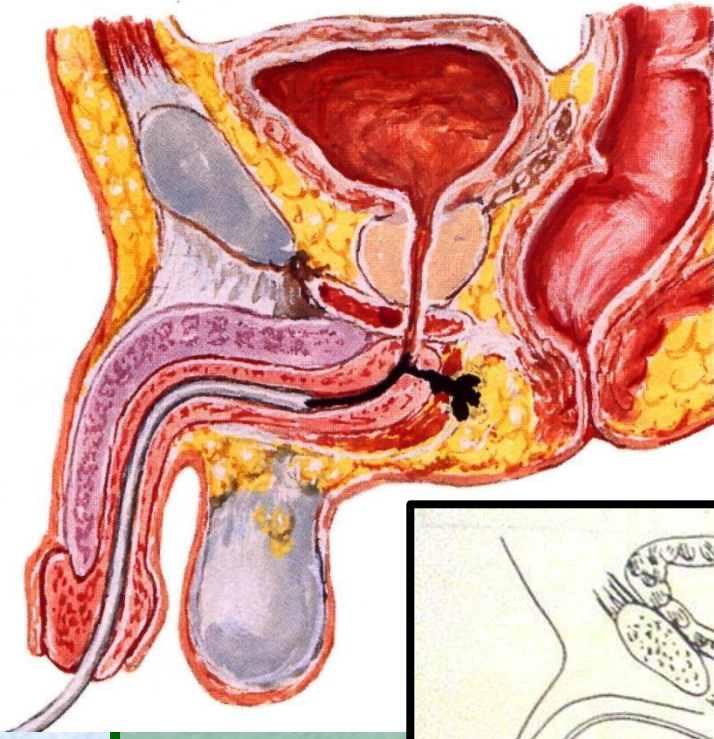


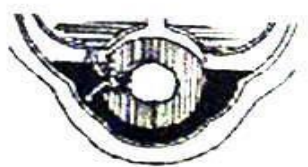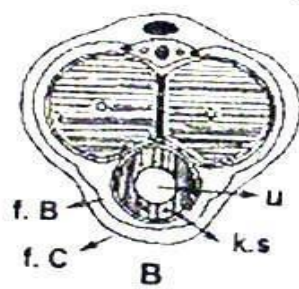
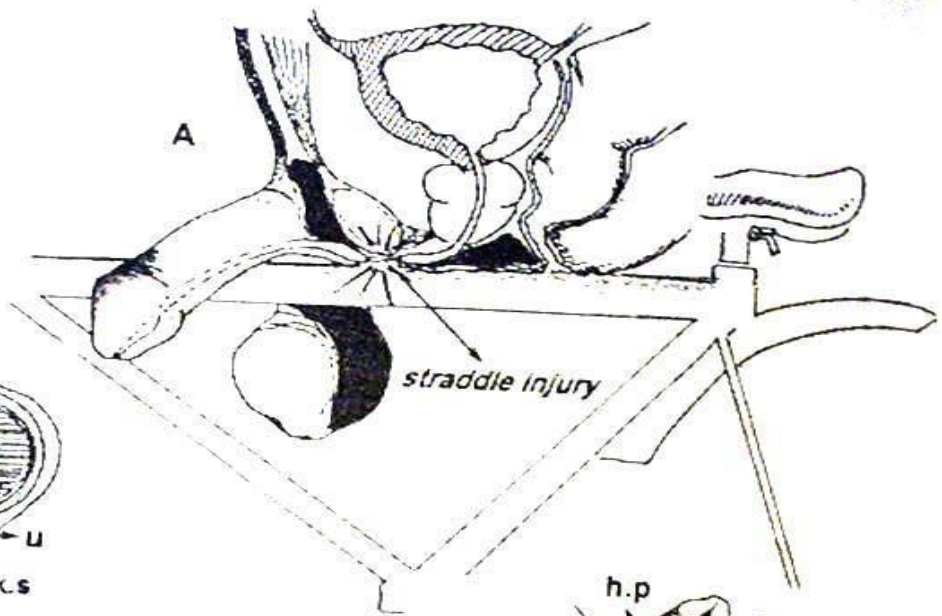
4: CYSTOMETER
ATTACHED TO
CATHETER; FLOW
STARTED AT
1 ml/sec (SLOW,
STEADY STREAM
IN MURPHY DRIP);
UNINHIBITED
CONTRACTIONS
NOTED (NORMALLY
ABSENT); PT.
INDICATES FIRST
URGE TO URINATE
(NORMAL=175 ml)
AND FEELING OF
FULLNESS (NORMAL=
350 TO 450 ml)



F. Netter M.D.
© CIBA

Kontra indikasi





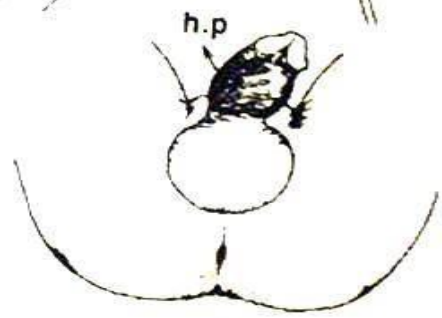
Fasia Buck utuh

C




Fasia Buck robek

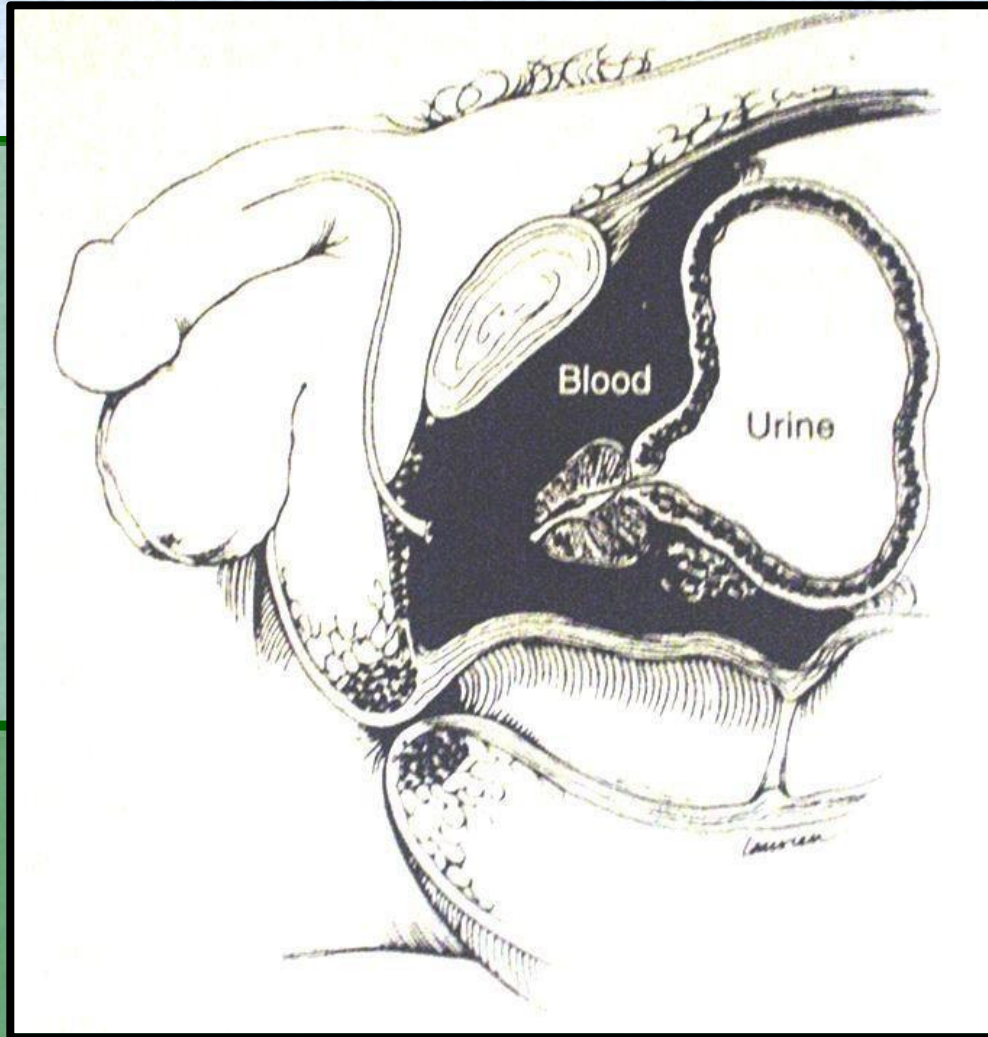
E



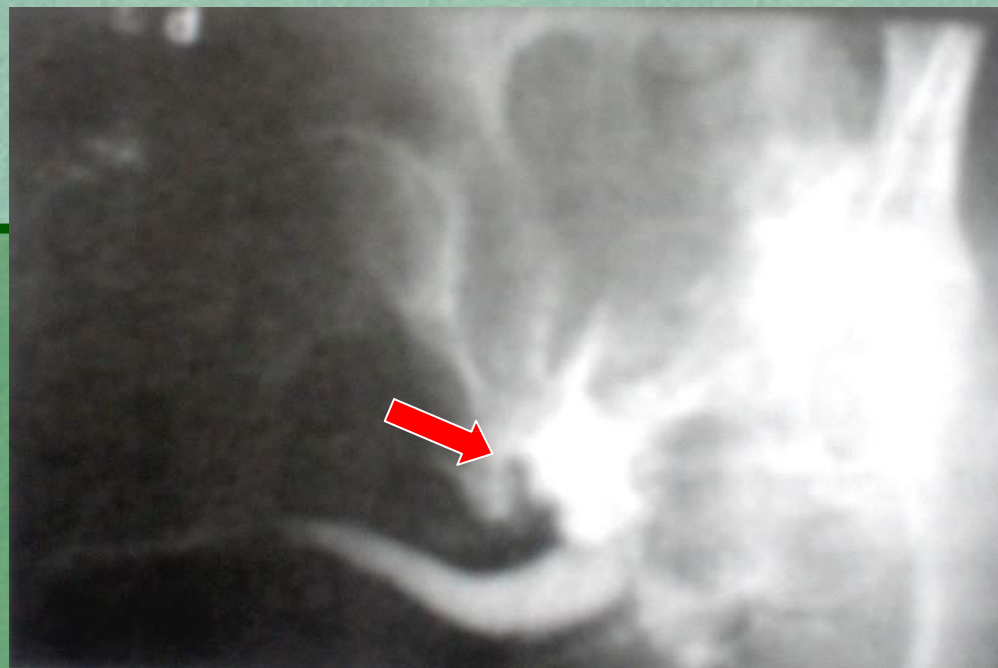
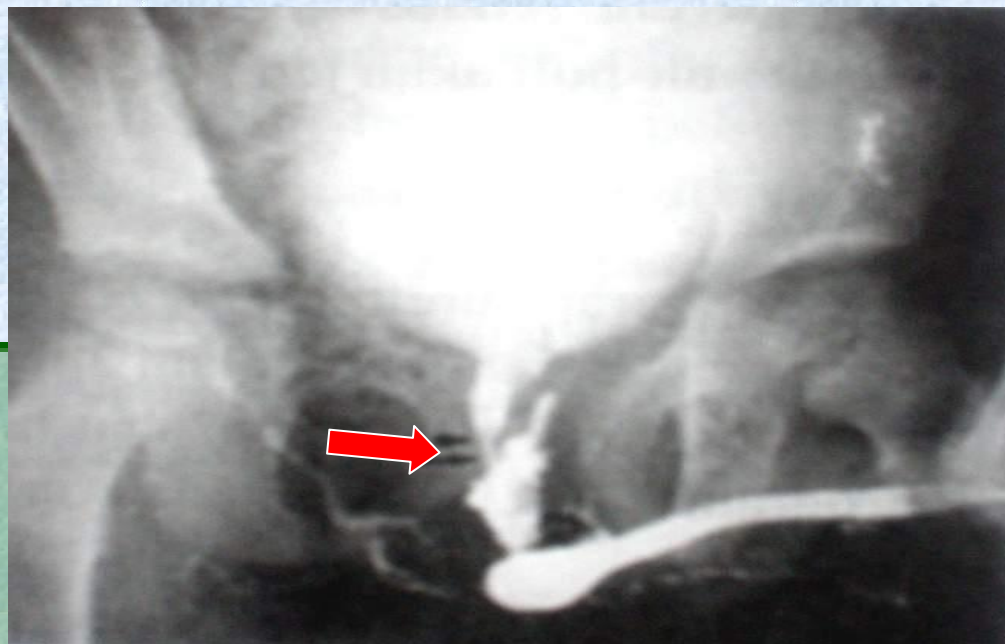
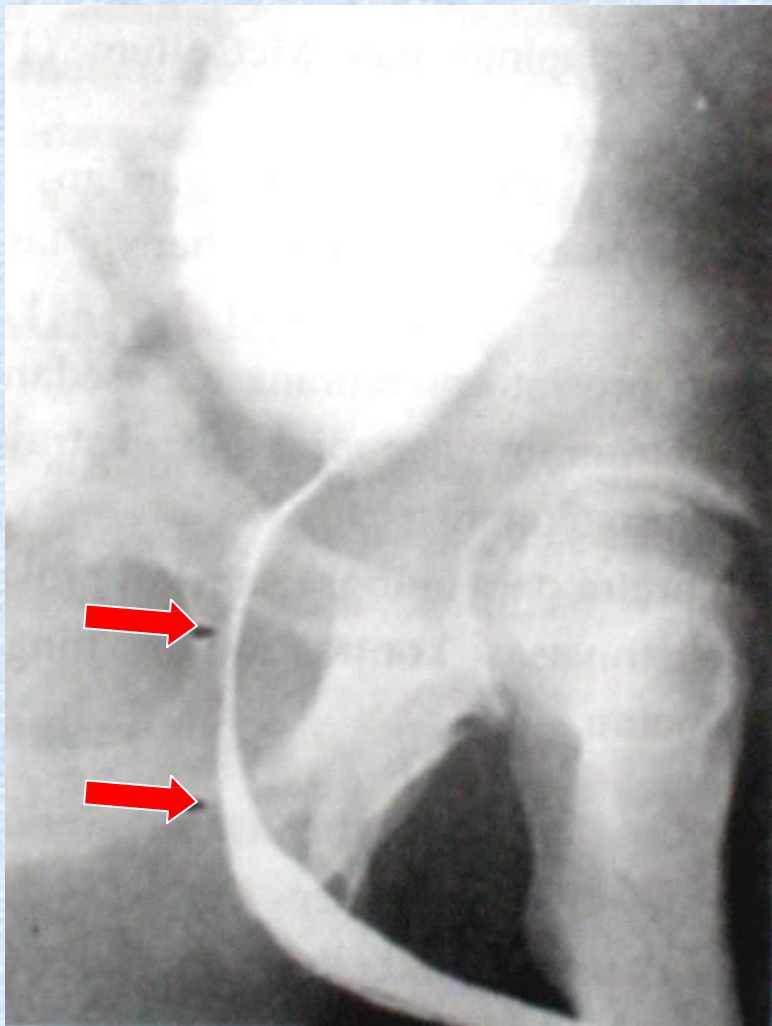
D



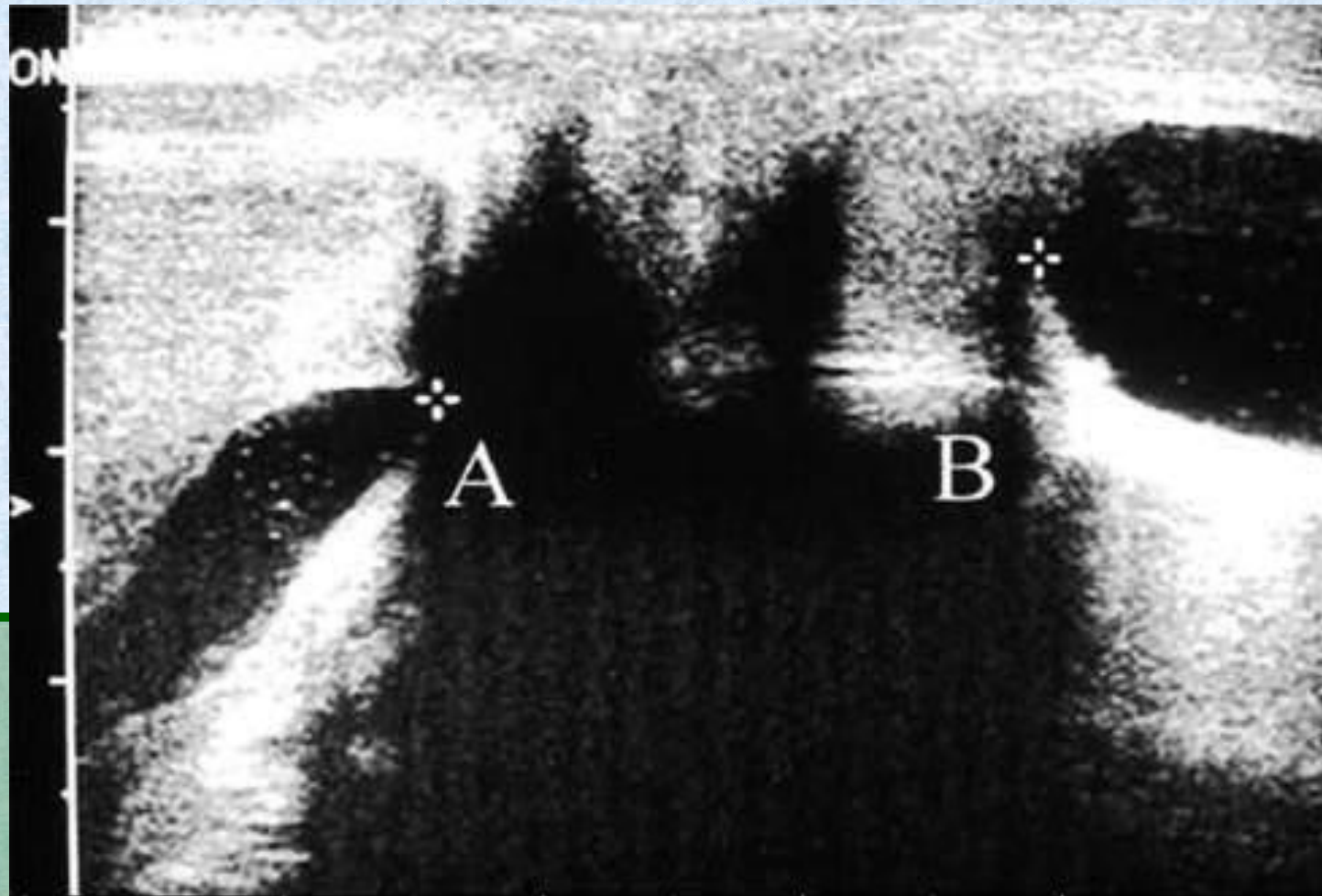
F

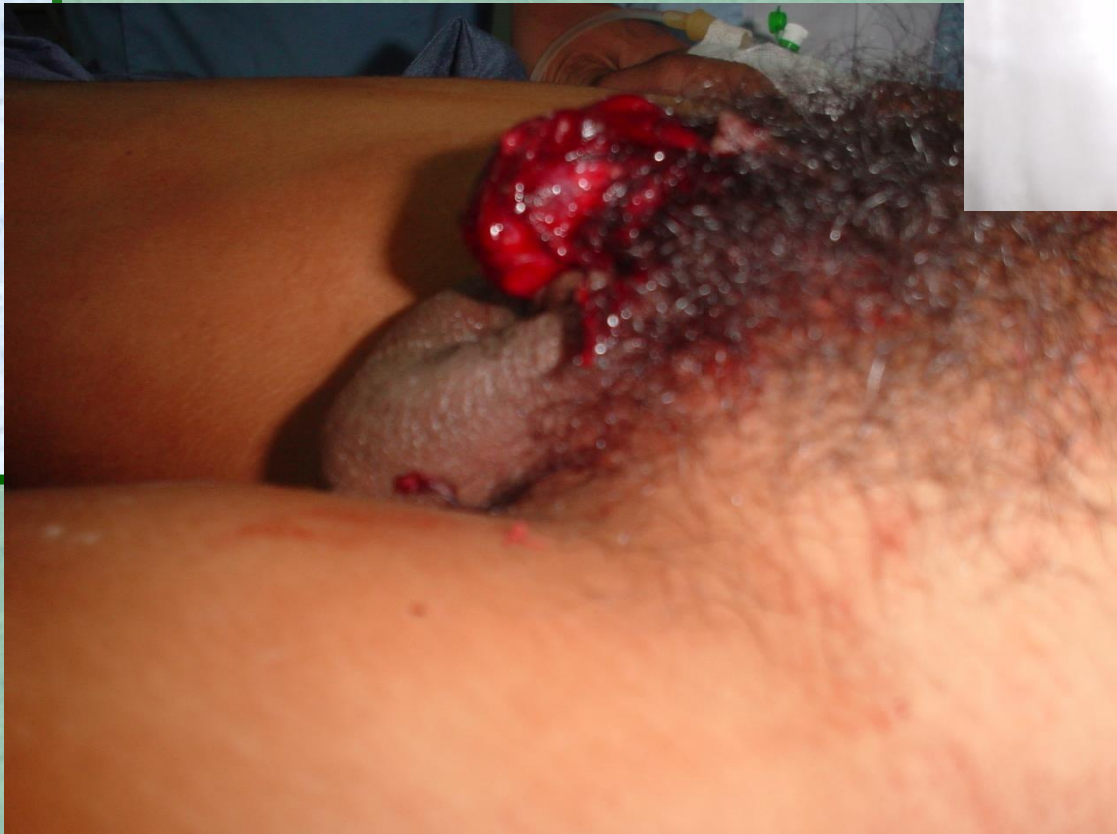
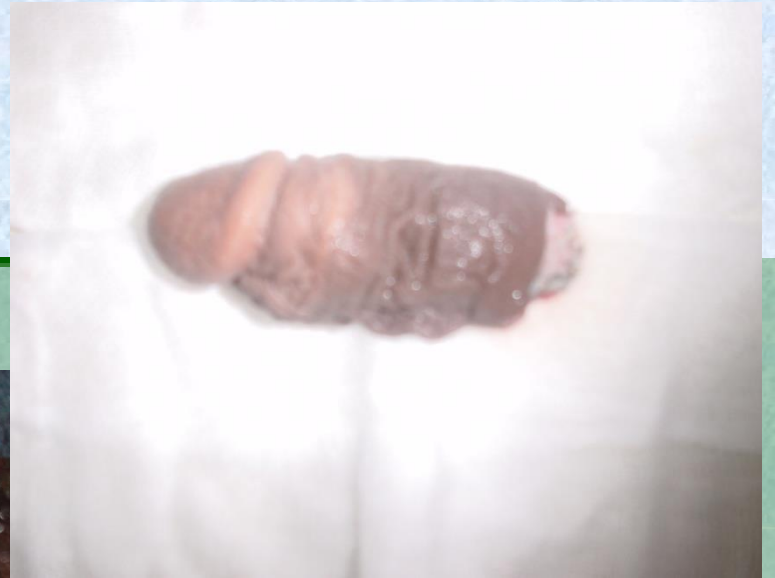
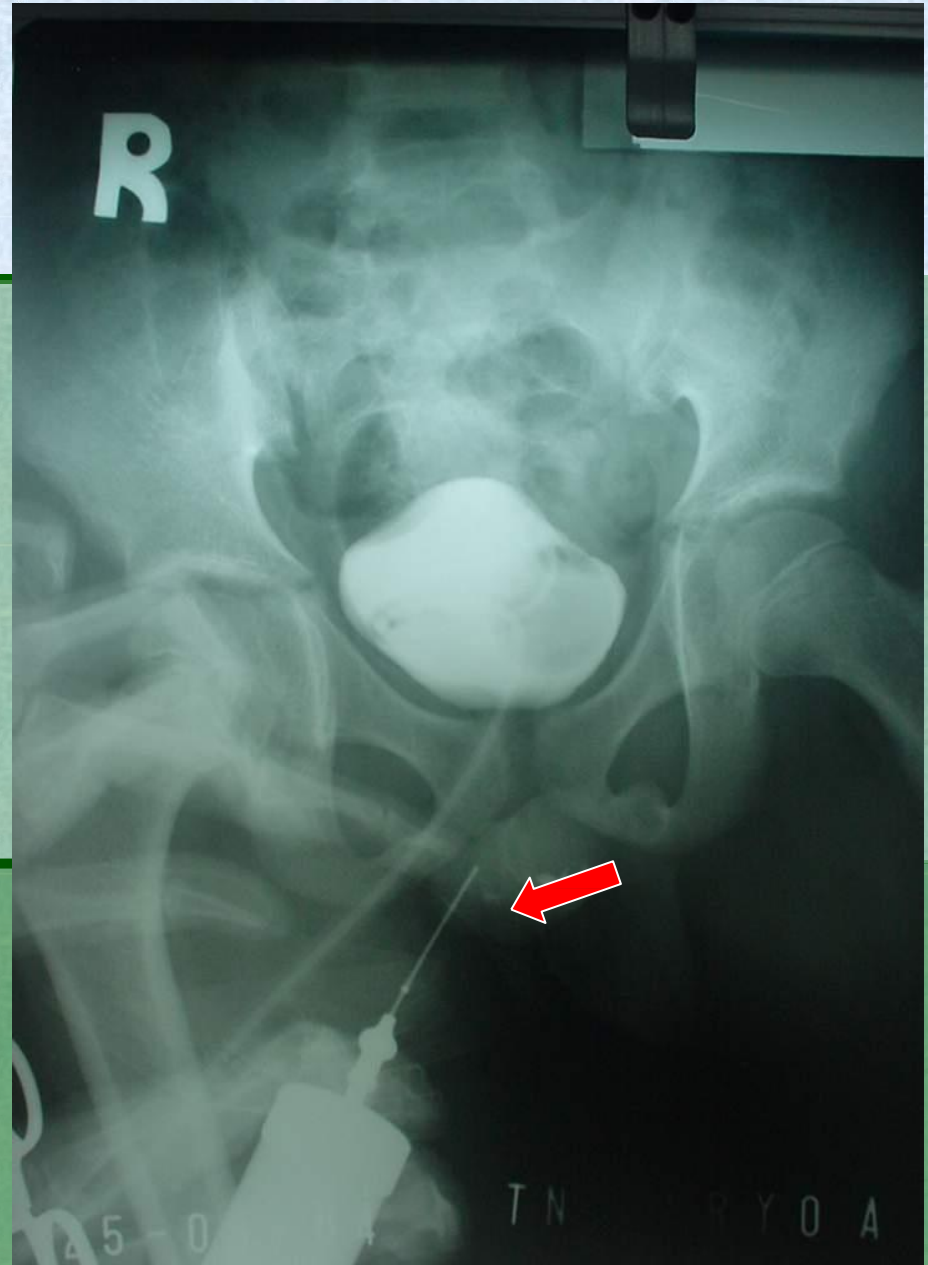
RADIOLOGI



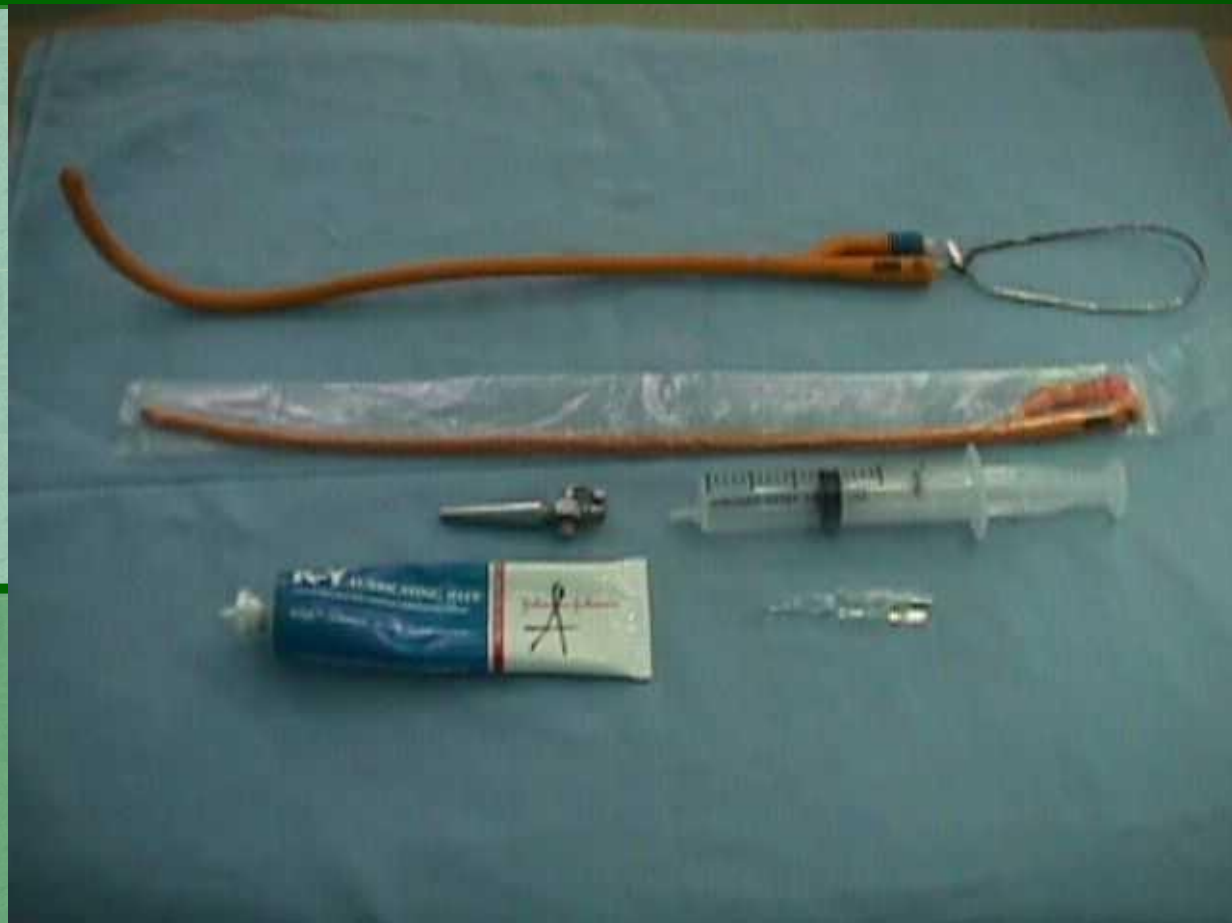RADIOLOGI







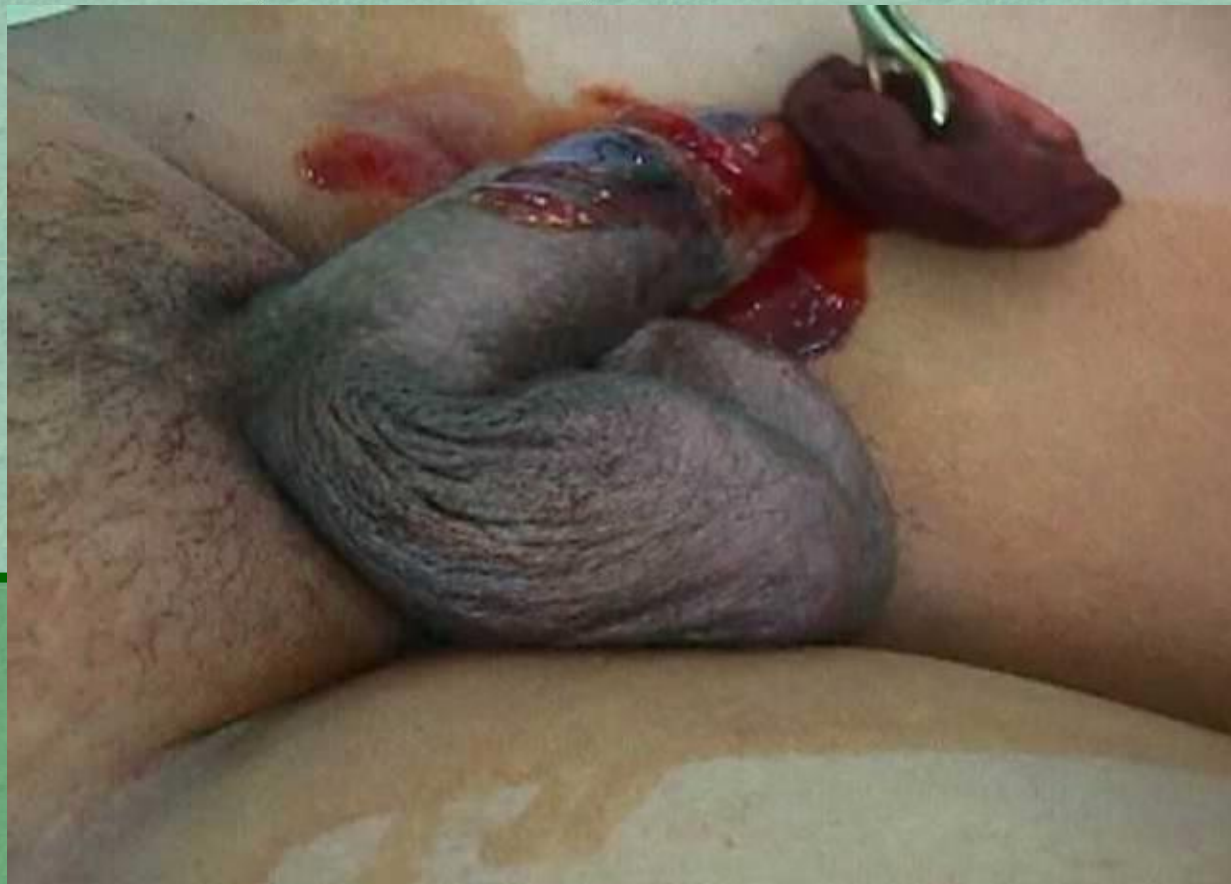Peralatan kateterisasi



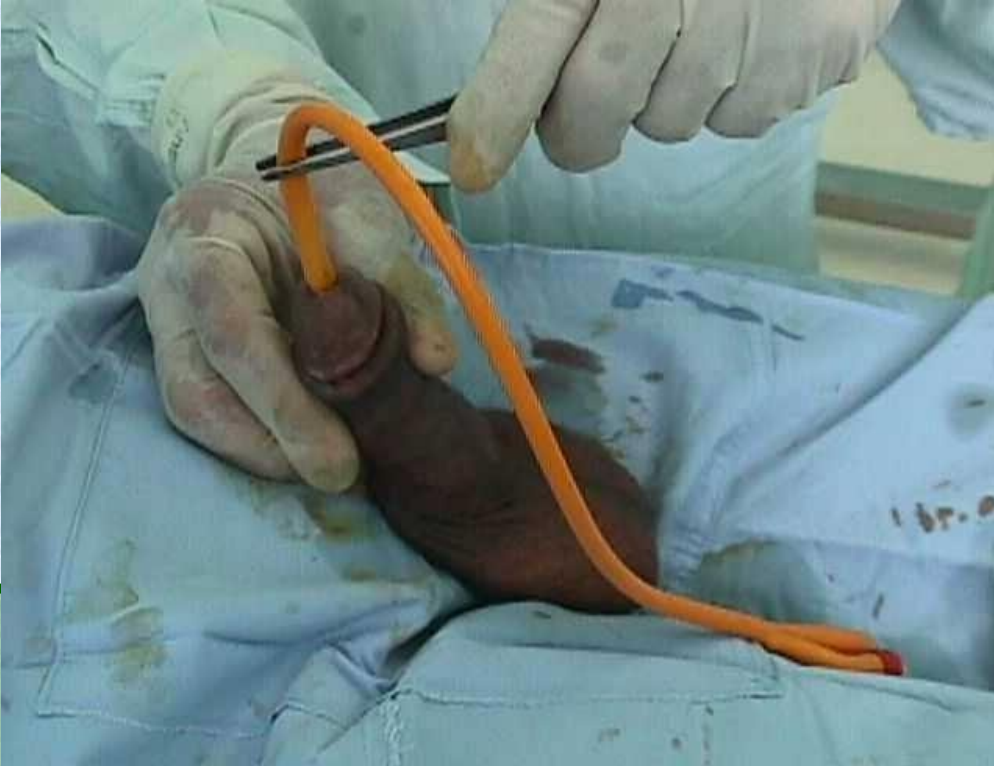
Cara kateterisasi



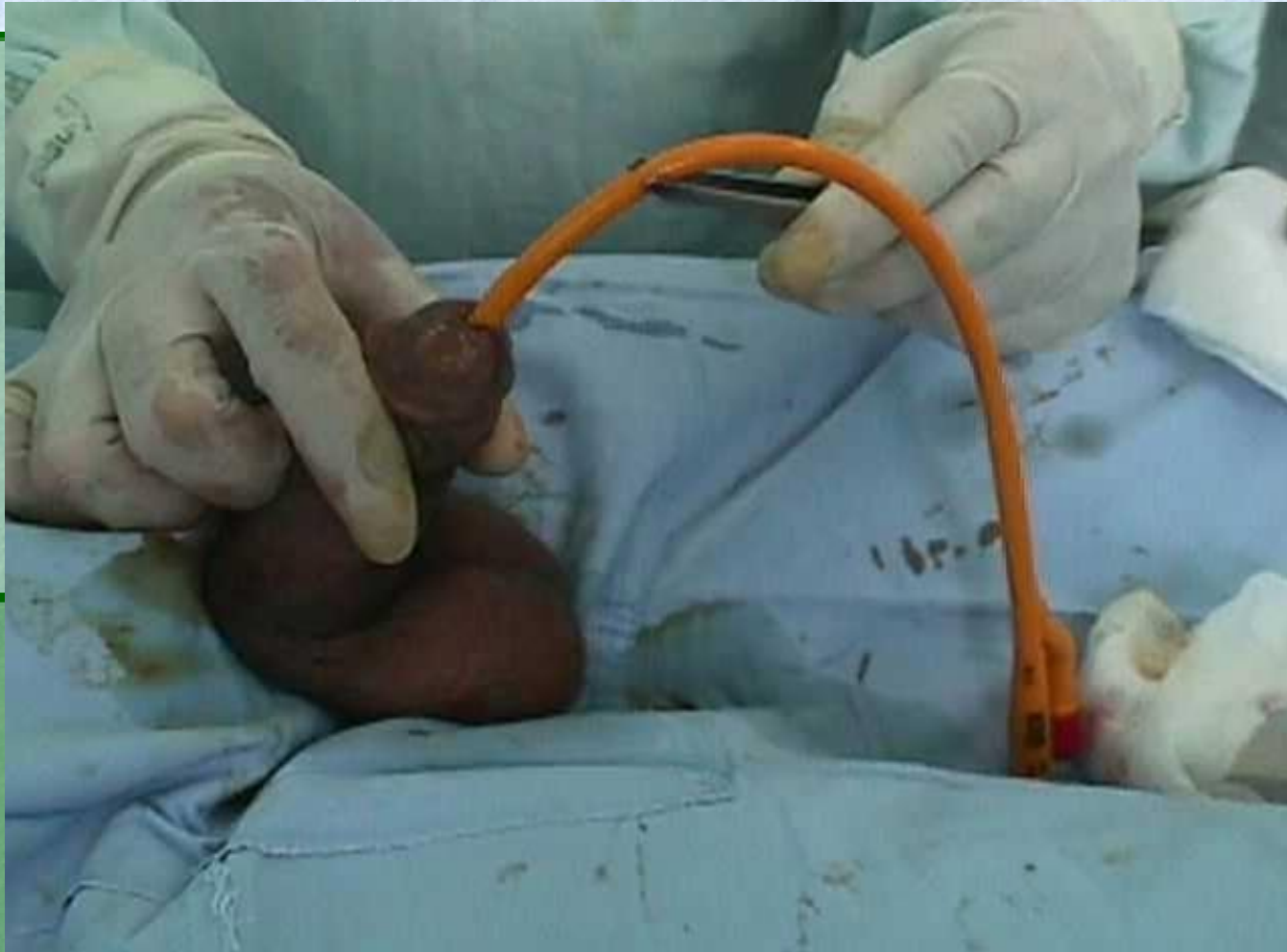Disinfection



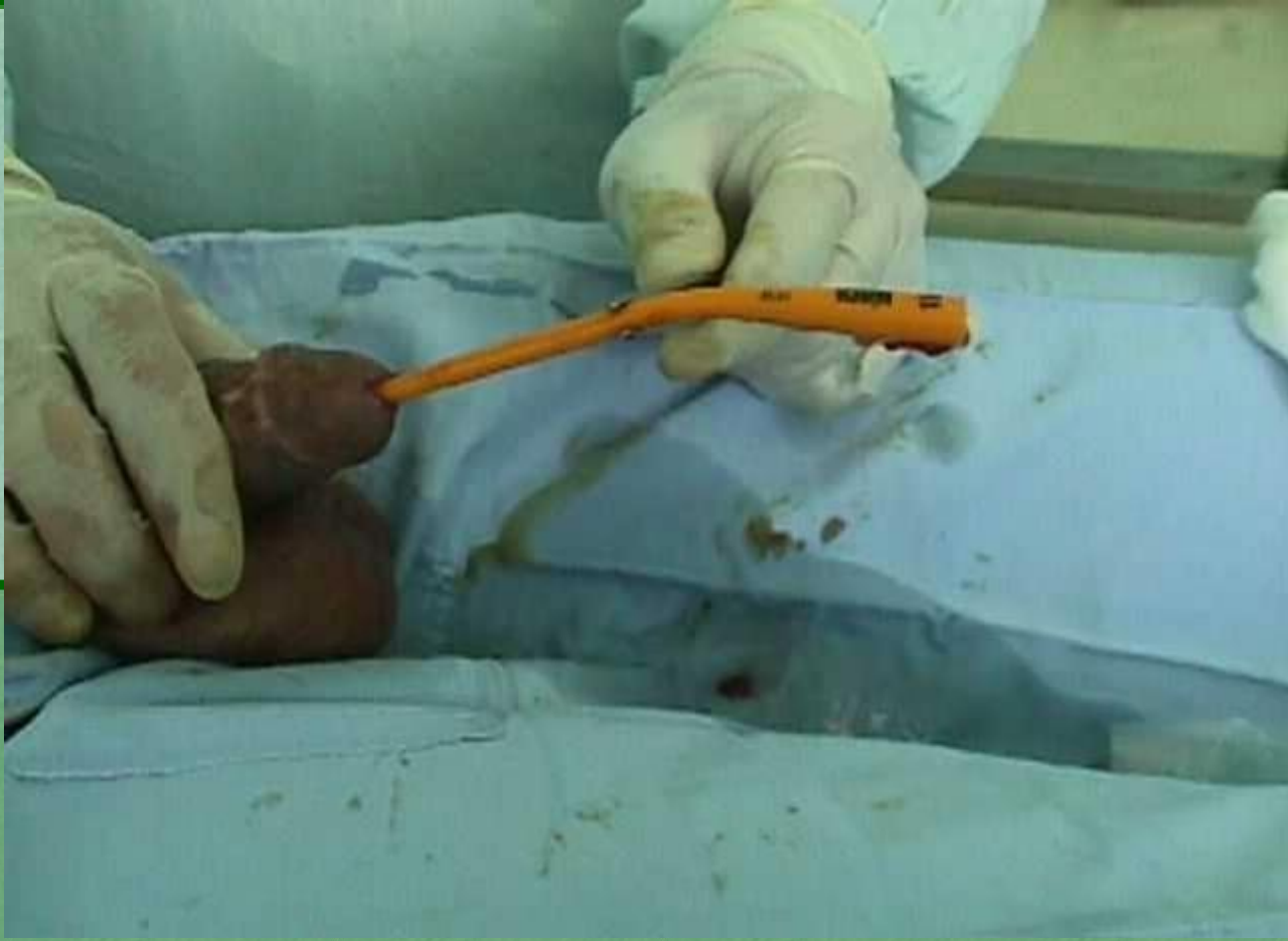Penetrasi kateter



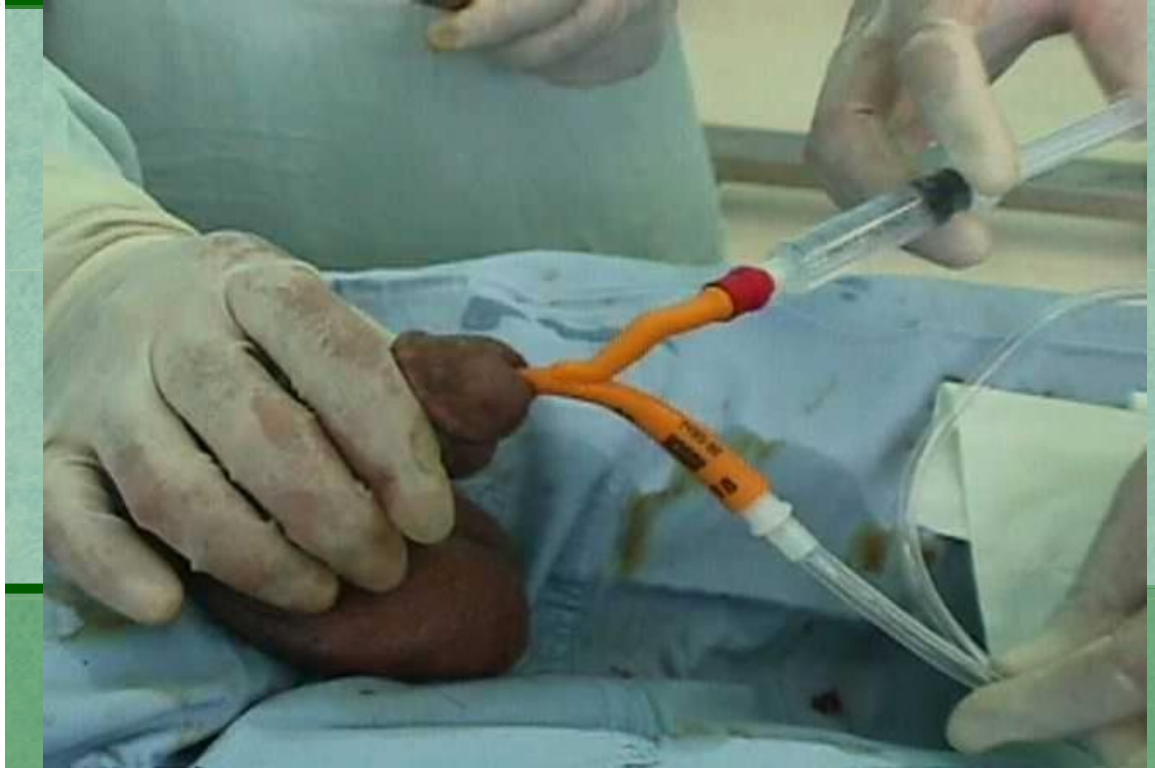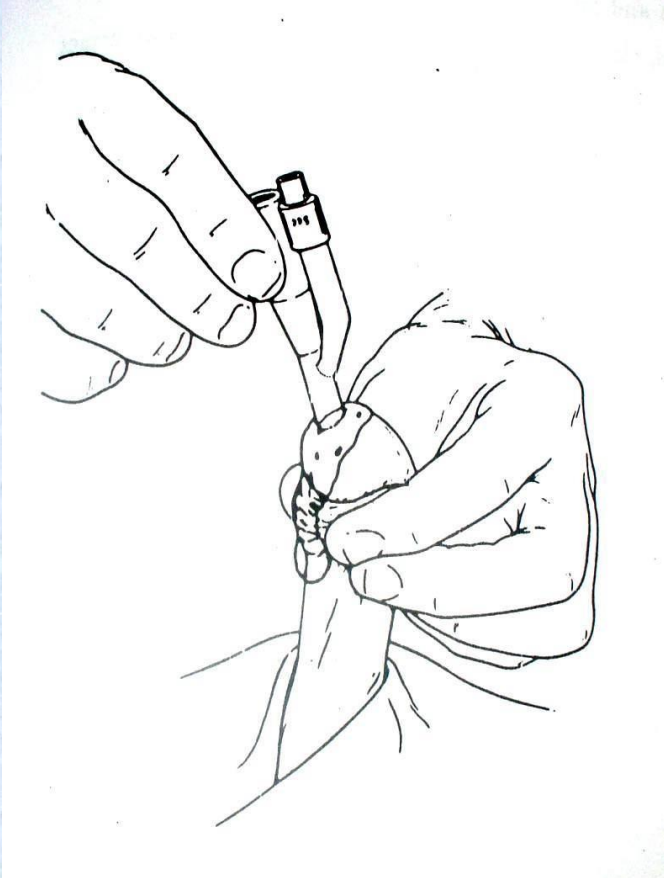
Dorong kateter secara *gentle*



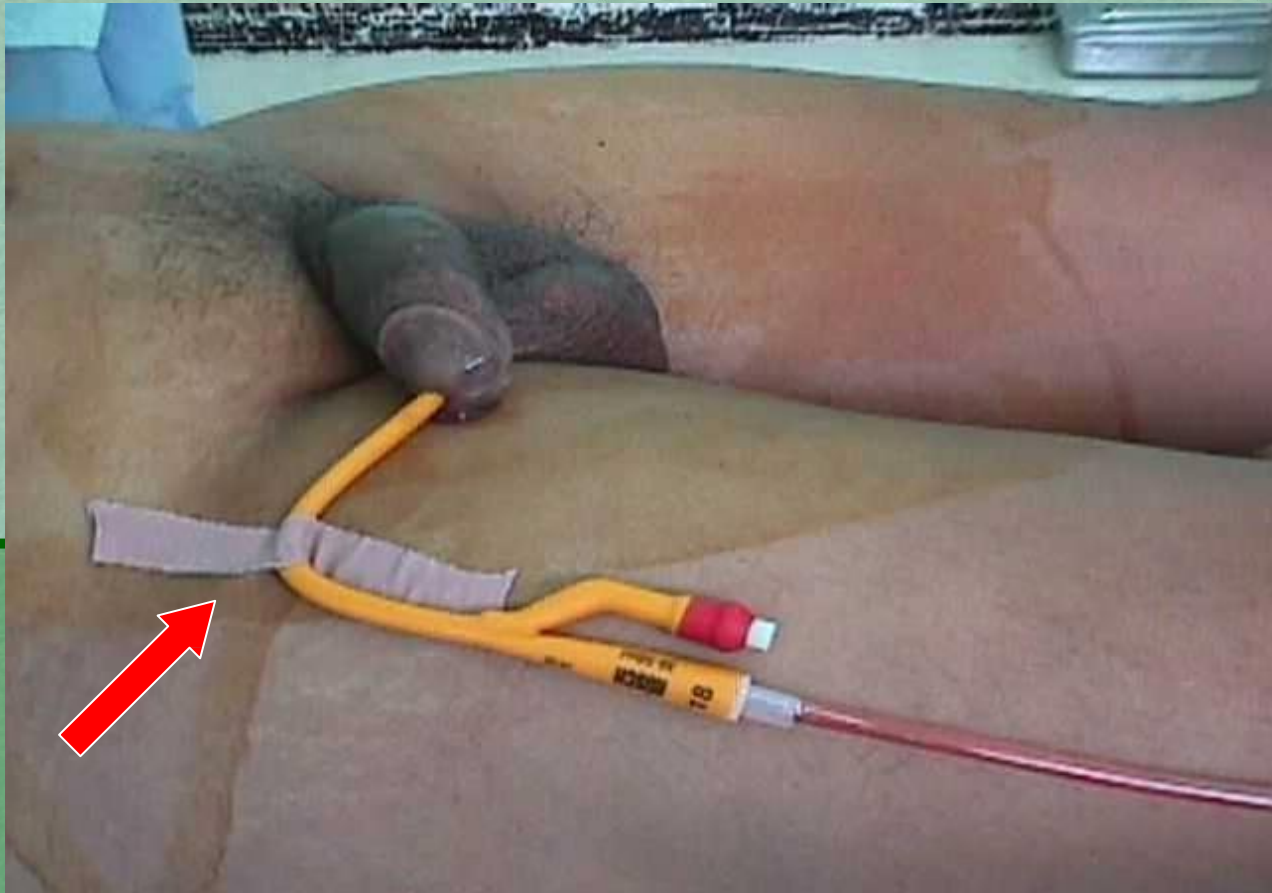Pengeluaran urin



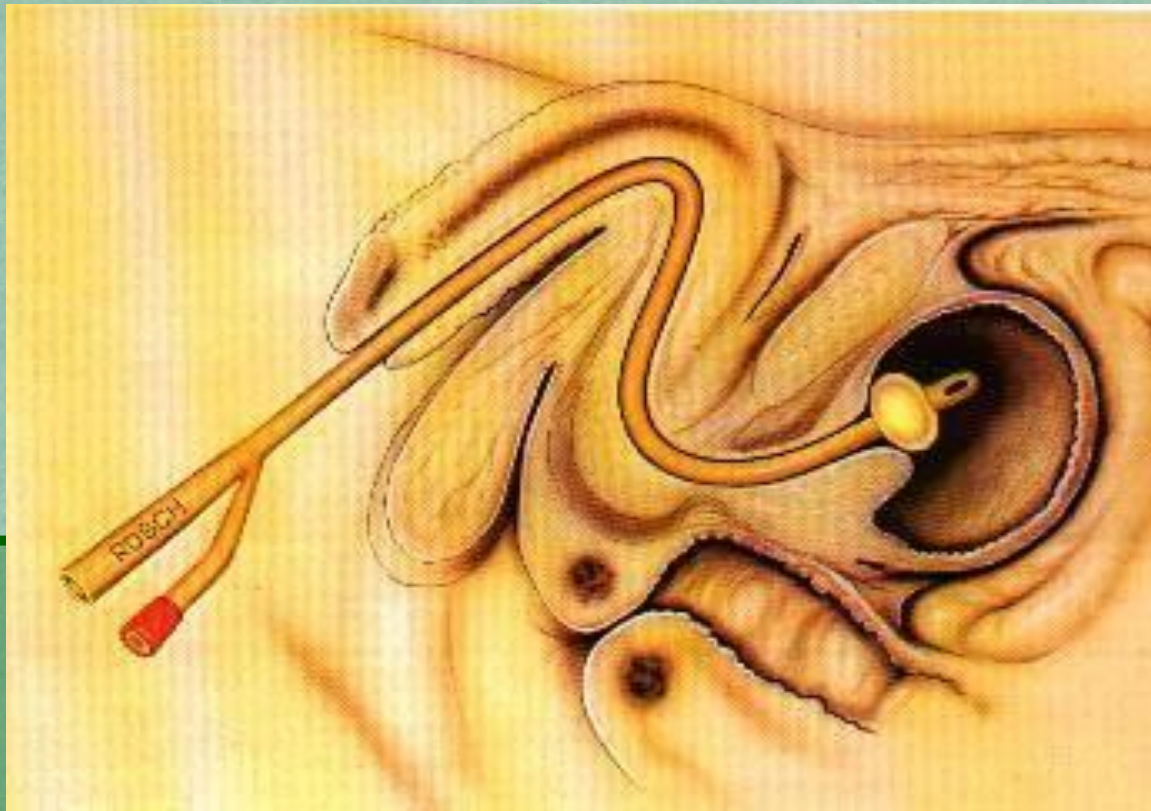Fiksasi balon kateter



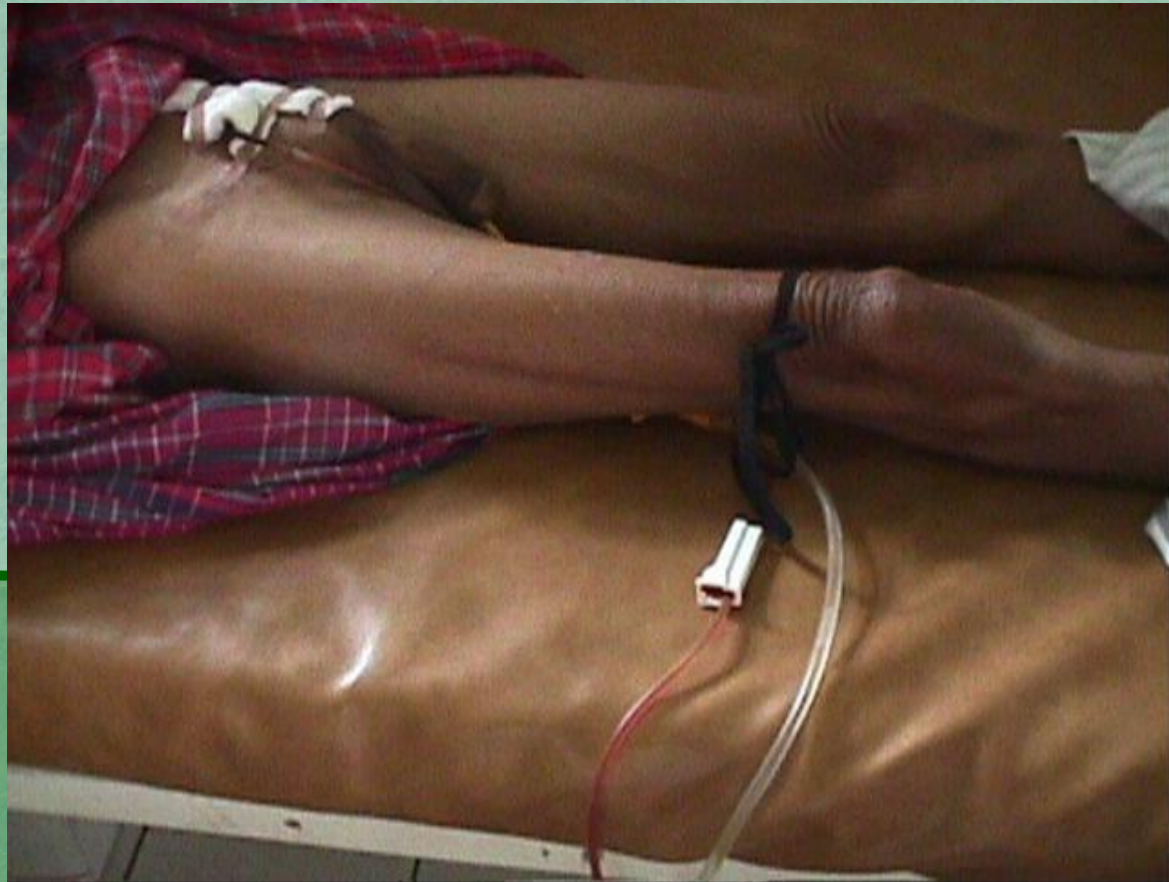Fiksasi kateter



Posisi kateter pada kandung kemih



Fiksasi yang keliru



Kesulitan pada pemasangan kateter


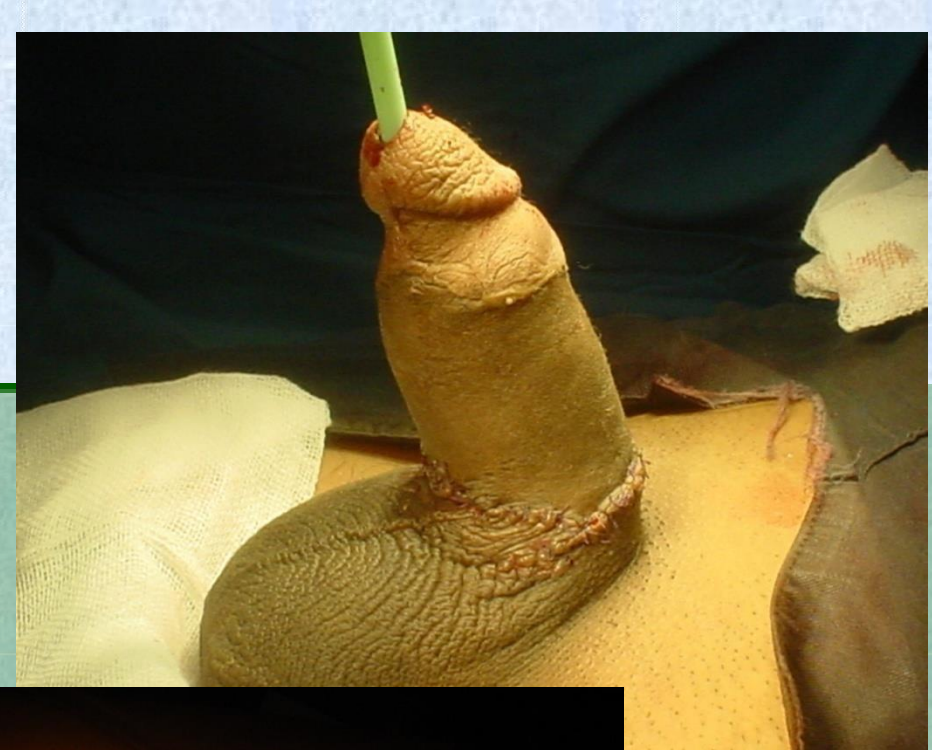
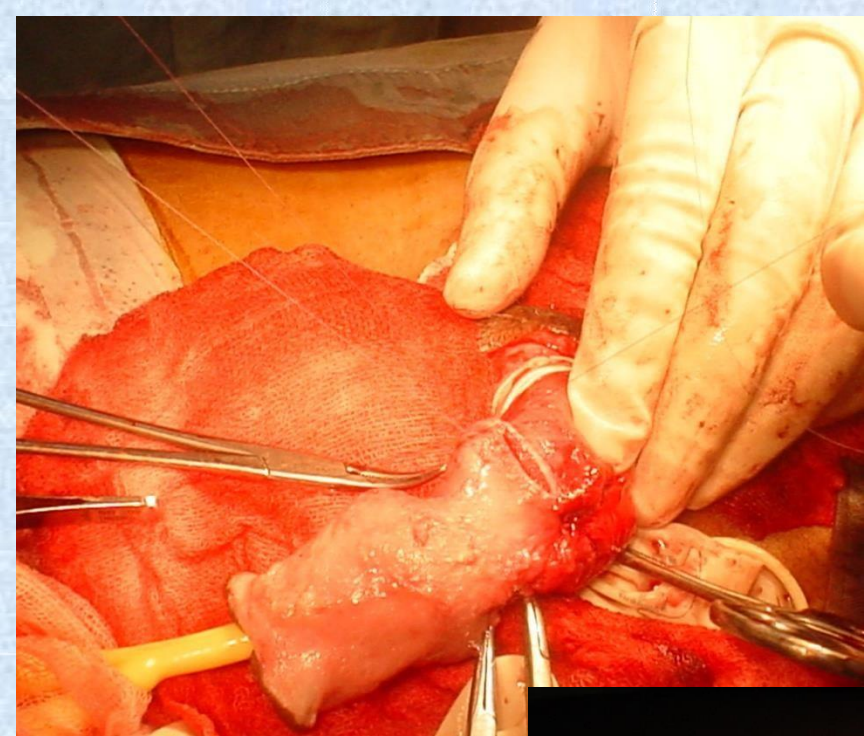
- Kesulitan melewati lengkung-S pada pars bulbosa
- Kekakuan spingter uretra eksterna
- Sumbatan organik

Perawatan selama pemakaian kateter

- Banyak minum
- Kebersihan MUE
- Penempatan *urine bag* lebih rendah dari posisi kandung kemih
- Pertahankan fiksasi yang baik dari kateter
- Selalu gunakan *urine bag*

Komplikasi

- Cedera saat penetrasi kateter atau karena fiksasi yang keliru
- Infeksi saluran kemih
- Batu buli
- Degenerasi keganasan
- Hematuria



selamat belajar