

PRAKTIKUM PATOLOGI ANATOMI
BLOK NEUROMUSCULOSCELETAL 2
 Penulis: dr. Dian Yuliartha Lestari, SpPA

I. Tingkat Kompetensi Keterampilan

Berdasarkan standar kompetensi dokter yang ditetapkan oleh KKI tahun 2012, maka tingkat kompetensi kasus neoplasma pada sistem Skin, Soft Tissue, dan Bone, adalah sebagai berikut:

Daftar Penyakit	Tingkat Kompetensi
Skin	
Tumor epitel jinak	2
Keratosi Seborrhoik	2
Kista epitel/epidermal	2
Kista Ateroma	2
Squamous Cell Carcinoma	2
Basal Cell Carcinoma	2
Xantoma	2
Hemangioma	2
Limfangioma	1
Angiosarcoma	1
Neurofibromatosis	2
Lentigo	2
Nevus Pigmentosus	2
Melanoma Maligna	1
SOFT TISSUE	
Rhabdomiosarcoma	1
Leiomyoma, Leiomyosarcoma, Liposarcoma	1
Lipoma	4A
Fibromatosis, Fibroma, Fibrosarcoma	1
BONE	
Displasia Fibrosa	2
Osteosarcoma	1
Sarcoma Ewing	1
Teratoma Sacrocoxygeal	2

(Sumber : SDKI, 2012)

II. Tujuan Belajar

1. Mahasiswa mampu memahami jenis-jenis neoplasma pada sistem Skin, Soft Tissue, dan Bone.
2. Mahasiswa mampu menjelaskan gambaran makroskopis dan mikroskopis jenis-jenis neoplasma pada sistem Skin, Soft Tissue, dan Bone.
3. Mahasiswa mampu menjelaskan patogenesis kasus neoplasma sistem Skin, Soft Tissue, dan Bone.

III. Prerequisite knowledge

Sebelum memahami konsep neoplasma pada sistem Skin, Soft Tissue, dan Bone., mahasiswa harus:

1. Memahami anatomi sistem Skin, Soft Tissue, dan Bone.
2. Memahami histologis sistem Skin, Soft Tissue, dan Bone.
3. Memahami fisiologis sistem Skin, Soft Tissue, dan Bone.
4. Memahami konsep terjadinya/patogenesis neoplasma

IV. Kegiatan Pembelajaran

Pembelajaran dilakukan dalam tahapan sebagai berikut:




Luring

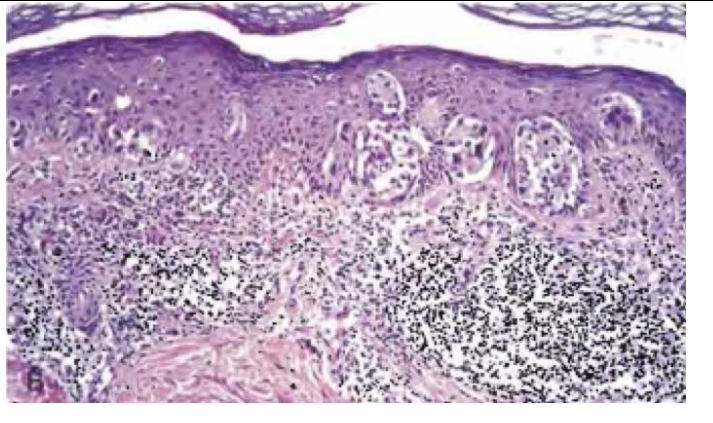
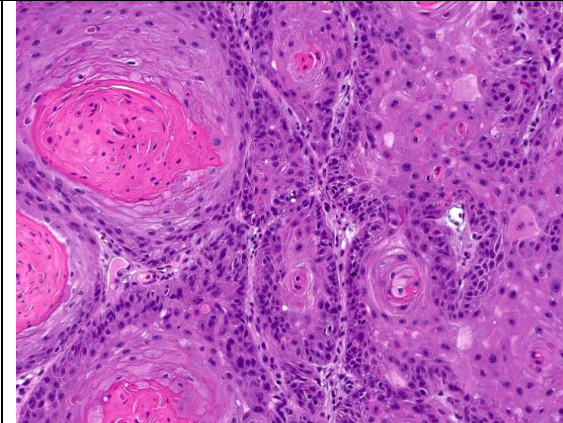
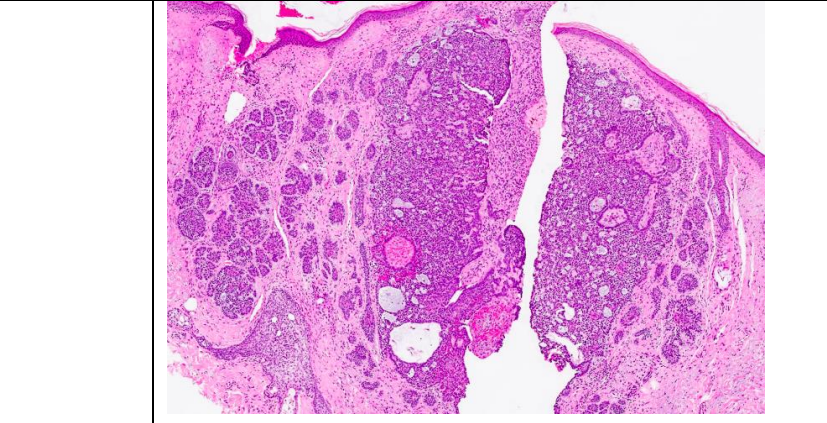
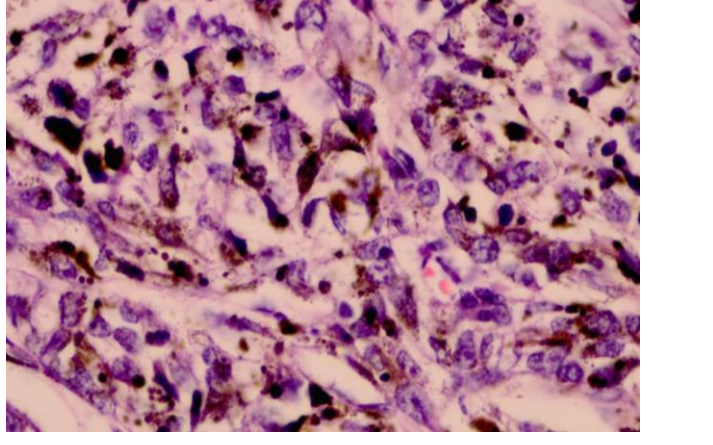
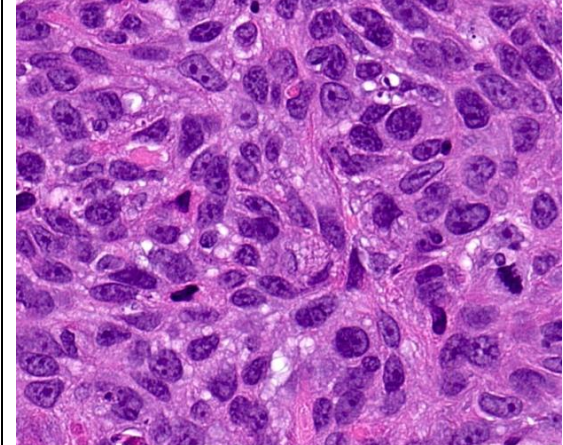
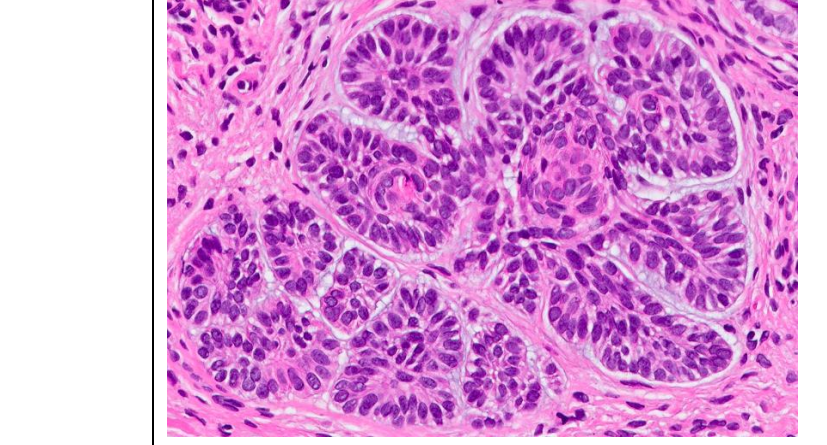
Tahapan pembelajaran	Lama	Metode	Pelaksana/ Penanggung Jawab
Pre tes dan Pengantar	35 menit	Soal dan PTT	Dosen
Demo dan Mandiri	2x50 menit	Identifikasi makroskopis dan mikroskopis	Dosen
Review	15 menit	Identifikasi makroskopis dan mikroskopis	Dosen



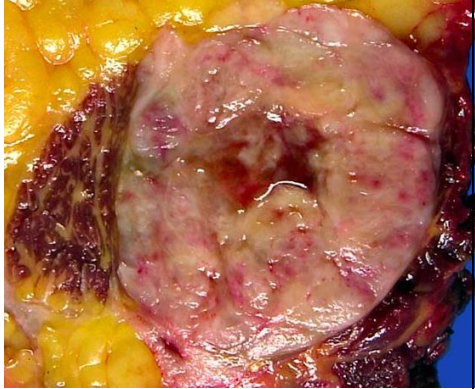
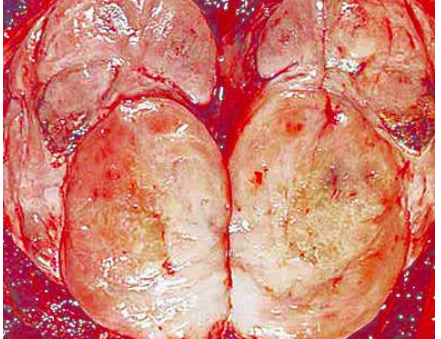
Daring

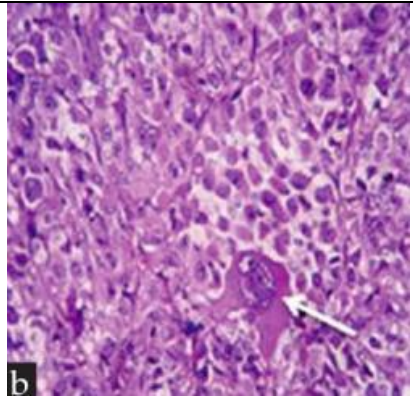
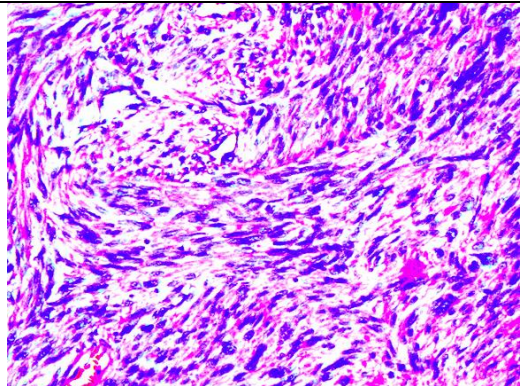
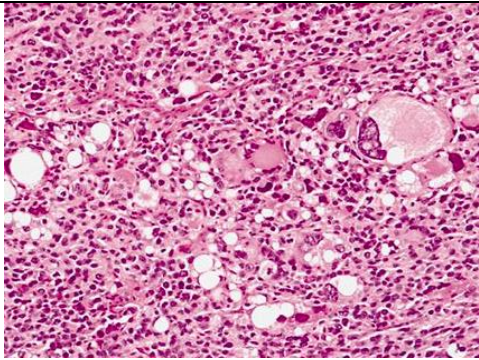
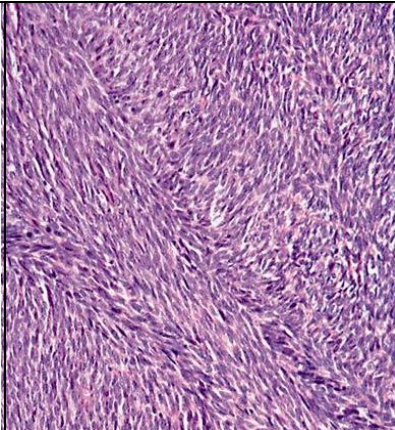
Tahapan pembelajaran	Lama	Metode	Pelaksana/ Penanggung Jawab
Pre tes dan Pengantar	35 menit	Soal dan PTT	Dosen
Demo	2x50 menit	Identifikasi makroskopis dan mikroskopis lewat PPT dan video	Dosen
Review	15 menit	Identifikasi makroskopis dan mikroskopis	Dosen

V. Sumber belajar

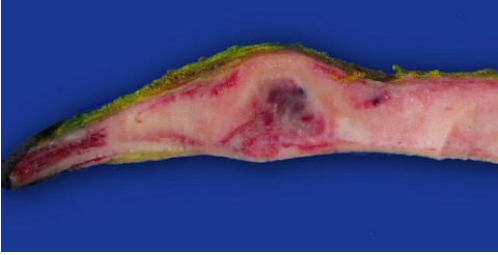



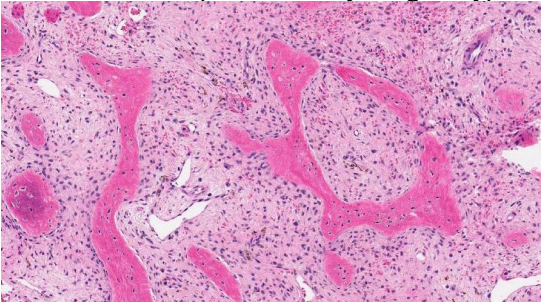

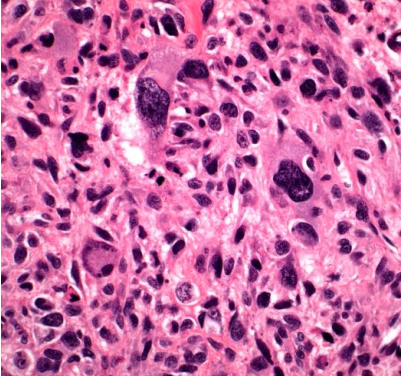
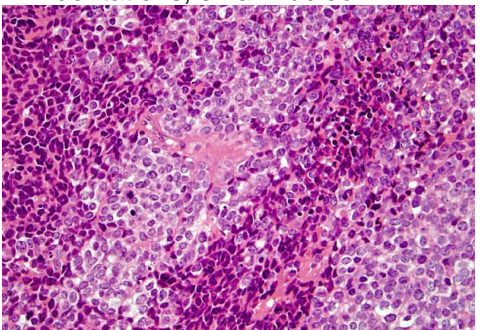
VI.	MELANOMA MALIGNA	SQUAMOUS CELL CARCINOMA	BASAL CELL CARCINOMA
Definisi (asal tumor)	Sel melanosit	Sel skuamous	Sel basal
Predileksi	Seluruh area tubuh yang mengandung sel melanosit	Seluruh area tubuh yang dilapisi sel epitel skuamous	Seluruh area tubuh yang mengandung sel basal (paling sering di wajah)
pencetus	UV	UV, iritasi, HPV	UV, iritasi
insiden	Decade 3-5	Decade 4-5	Decade 4-5
klinis			
makroskopis	Nodul atau massa memenuhi kriteria : A. asimteri B. Irregular border C. Uneven color D. Diameter > 6 mm	Nodul atau ulcus dengan bentuk bloomkol, tepi tidak rata, meninggi, dasar menggaung dan kotor. Bau (+)	Nodul atau ulcus kehitaman, tepi membentuk gambaran ulcus rodent, dasar menggaung radang. Bau (-)
			
mikroskopis	Sel inti bulat oval hingga spindle, kromatin kasar, pleomorfik, sitoplasma bergranula kecoklatan	Sel inti bulat oval, pleomorfik, hiperkromatik, tersusun dalam pulau-pulau. Kadang ditemui sel bizarre. Beberapa membentuk keratin pearl (well differentiated)	Sel inti bulat oval, pleomorfik ringan, tersusun dalam lobules, bagian tepi membentuk palisading, tampak cleft (+)

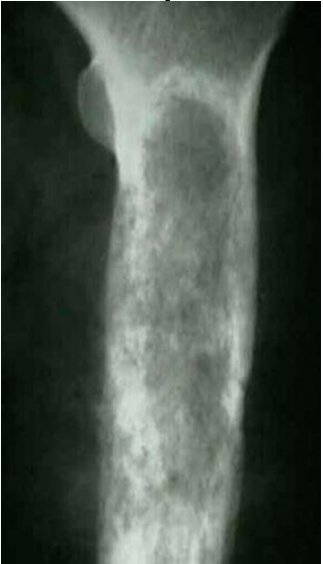



			
			
IHK	Melan A, S100	CK, p63, EMA	p53, BCL 2, p63

	RHABDOMYOSARCOMA	LEIOMYOSARCOMA	LIPOSARCOMA	FIBROSARCOMA
Definis (asal sel tumor)	rhabdomyoblast	Smooth muscle	lipoblast	fibroblast
Predileksi	Head, neck, UG	Uterus, extremitas, retroperitoneum	Thigh (29%), internal trunk (21%), limb girdles (18%), upper extremity (16%), thoracoabdominal wall (10%)	Lower extremities, trunk
Insiden	0-9 tahun (50%)	40-69 tahun	54-70 tahun	40-50 tahun
Makroskopis	<p>Circumscribed, nonencapsulated mass</p> 	<p>Low grade : hard masses and resemble leiomyomas, with white whorled cut surface</p> <p>High grade : large, soft, often with necrosis, hemorrhage and cystic degeneration</p> 	<p>large (median 8 - 10 cm, up to 23 cm), multinodular, white-yellow hemorrhage, necrosis</p> <p>Usually deep (subfascial)</p> 	<p>well circumscribed, nonencapsulated</p> <p>Fleshy, hemorrhagic, necrotic, white-tan</p> 
Mikroskopis	<ul style="list-style-type: none"> Eccentric eosinophilic granular cytoplasm rich in thick and thin filaments If round and elongate, are called strap cells or tadpole cells 	<ul style="list-style-type: none"> Fascicular growth pattern (bundles intersect at right angles) Palisading of spindle cells with eosinophilic fibrillary cytoplasm, focal granularity Nuclei are cigar-shaped and blunt-ended with variable atypia, often with cytoplasmic vacuoles at both ends of nuclei (unlike neural lesions) 	<ul style="list-style-type: none"> Well circumscribed but non-encapsulated with infiltrative borders At least focal typical liposarcomatous areas 	<ul style="list-style-type: none"> Highly cellular fibroblastic proliferation in herringbone pattern Cells have scant cytoplasm, tapering elongated dark nuclei with increased granular chromatin, variable nucleoli

				
Jenis	<ul style="list-style-type: none"> Embryonal Alveolar Pleomorphic 	<ul style="list-style-type: none"> Spindle/conventional Epithelioid myxoid 	<ul style="list-style-type: none"> Well differentiated Dedifferentiated Myxoid Pleomorphic 	<ul style="list-style-type: none"> Dermatofibrosarcoma Myxoid fibrosarcoma Pleomorphic fibrosarcoma
IHK	Desmin, Myogenin, MyoD1	Vimentin, Desmin, SMA	MDM2, S100	Retikulin, Vimentin

	FIBROUS DYSPLASIA	OSTEOMA	OSTEOSARCOMA	EWING SARCOMA
Definisi (asal sel tumor)	Fibrocystic disease of bone	Compact matur trabeculae bone	Malignant osteoblast	peripheral primitive neuroectodermal tumor (PNET) = Askin Tumor
Predileksi	Any bone	Paranasal sinuses (frontal sinus most common), orbit, nasal cavity, jaw bones, cranial vault	Long bone extremities, metaphysis (90%)	Paraspinal tissue, pelvis, chest wall, extremities
Insiden	M=F, 3 rd decade	M:F = 3:2, mean 37 yo	Bimodial : 10-14 tahun (>); > 40 tahun	5-25 tahun
Makroskopis	Well circumscribed lesion with a sclerotic rim centered within the cortex	<ul style="list-style-type: none"> Sessile, polypoid shape Median size 3.0 cm (range 0.5 - 8 cm) Smooth, bosselated surface Cut surface with dense compact bone (ivory osteoma), trabecular bone (mature osteoma, or both 	Conventional (high grade intramedullary) osteosarcoma: <ul style="list-style-type: none"> Intramedullary mass: usually a metaphyseal epicenter with cortical permeation and a soft tissue component that raises the periosteum Size (mean): 5 - 10 cm 	<ul style="list-style-type: none"> White, fleshy, ill defined tumor with extensive involvement of medulla and cortex with periosteal elevation May be necrotic or resemble pus

		<p>patterns)</p> 	<p>Cut surface: gritty and mineralized (hard) - may have cartilaginous areas (chondroblastic osteosarcoma), hemorrhage, necrosis and cystic change</p> 	
<p>Mikroskopis</p>	<ul style="list-style-type: none"> • Branching and anastomosing irregular trabeculae of woven bone ("C" and "S" shapes) with no conspicuous osteoblastic rimming • Intervening fibrous stroma containing cytologically bland spindle cells, without prominent cytologic atypia 	<ul style="list-style-type: none"> • Composed primarily of dense, compact bone and broad trabeculae of mature bone within paucicellular fibrous stroma • Outer surface is sharply demarcated and lined by respiratory epithelium in sinus tumors 	<ul style="list-style-type: none"> • Neoplastic cells: marked atypia (pleomorphic, hyperchromatic) • Multiple cell morphologies often present in one tumor (epithelioid, plasmacytoid, spindled, small round cells, clear cells, giant tumor cells) 	<ul style="list-style-type: none"> • undifferentiated and densely cellular with "light" cell and "dark" cell appearance • Sheets of small, round, uniform cells with scant clear cytoplasm, divided into irregular lobules by fibrous strands • Indistinct cell membranes • Cytoplasm frequently has glycogen vacuoles; may be amphophilic • Round nuclei with indentations, small nucleoli 

<p>Gambaran Radiologis</p>	<p>Single or multiple well circumscribed intramedullary lesions with a sclerotic rim</p> 	<p>Well demarcated tumors Dense compact bone with varying amounts of central lucency</p> 	<p>Periosteal reactions: Sunburst pattern Codman triangle</p> 	<p>Plain film and CT</p> <ul style="list-style-type: none"> ○ Permeative: 76% ○ Laminated (onion skin) periosteal reaction: 57% ○ Sclerosis: 40% 
----------------------------	--	---	---	---

VII. PENILAIAN

Menggunakan slide (PPT) dengan metode MCQ

1. Mahasiswa mampu mendiagnosis berdasarkan keluhan, pemeriksaan fisik, gambaran makroskopis dan mikroskopis
2. Mahasiswa mampu menganalisis metode pemeriksaan patologi anatomi yang diperlukan
3. Mahasiswa mampu mengidentifikasi kelainan yang terjadi secara makroskopis dan mikroskopis
4. Mahasiswa mampu menyebutkan salah satu pathogenesis penyebab kelainan yang terjadi

DAFTAR PUSTAKA

1. Kumar, Vinay. Abba, Abul. Aster, Jon. 2018. Robbin, Basic Pathology 10th edition. Elsevier.
2. Rosai. 2011. Rosai and Ackerman : Surgical Pathology 10th edition. Elsevier