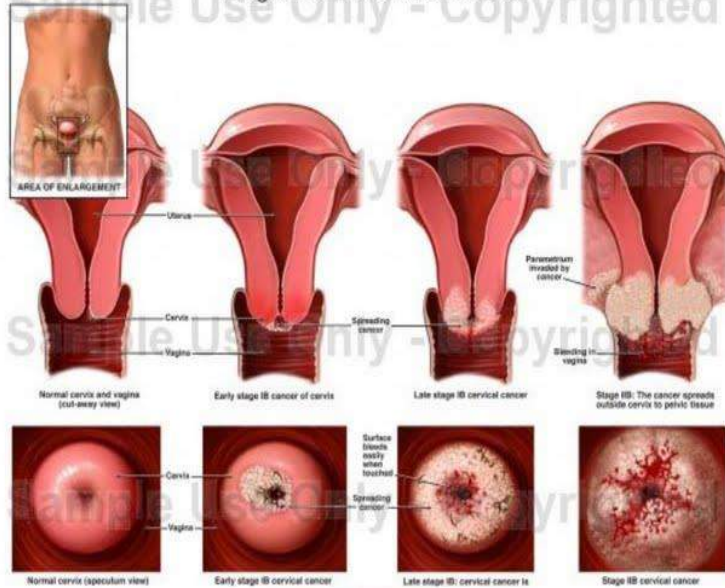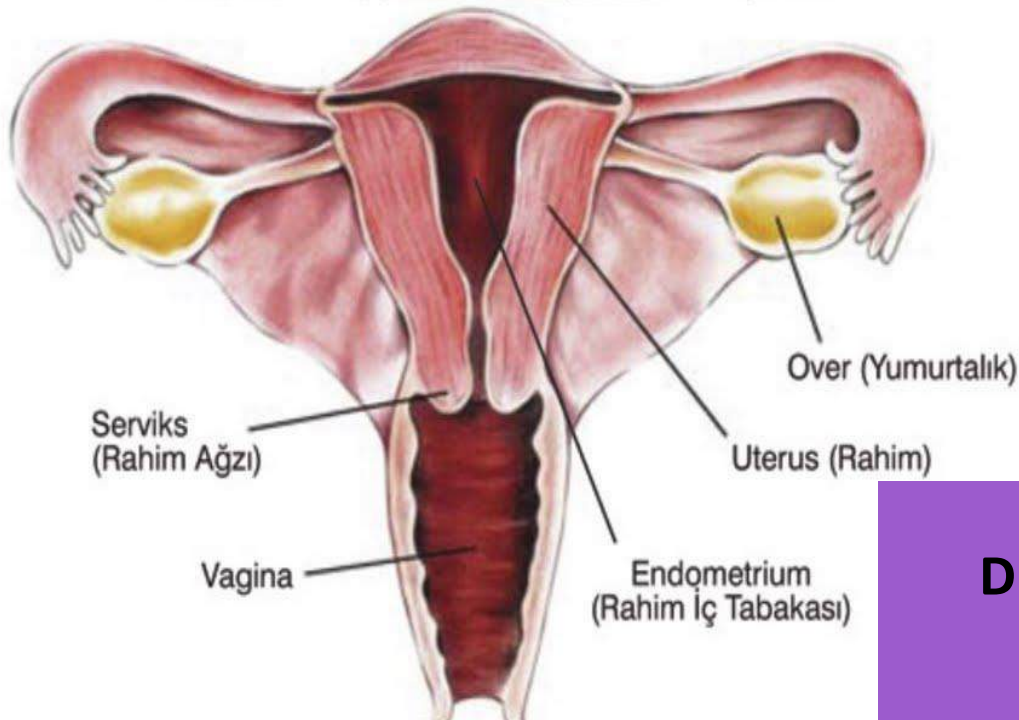


EMBRIOLOGI DAN UROGENITAL WANITA



OLEH:
Dr. Thontowi Djauhari NS, Mkes
Laboratorium Anatomi
Fakultas Kedokteran
Universitas Muhammadiyah Malang

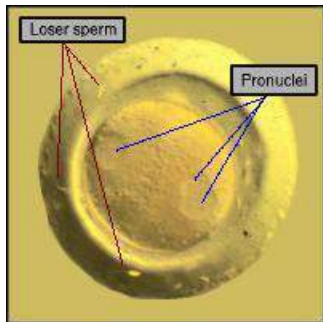
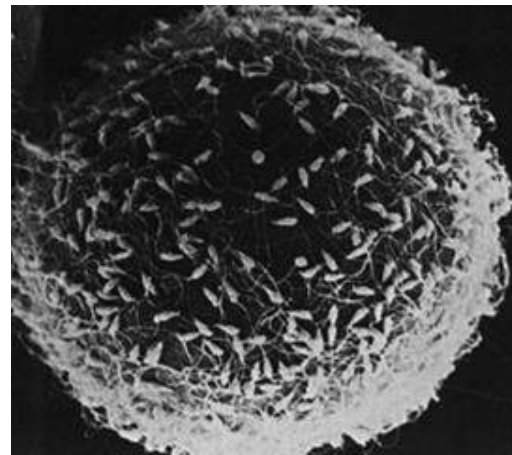
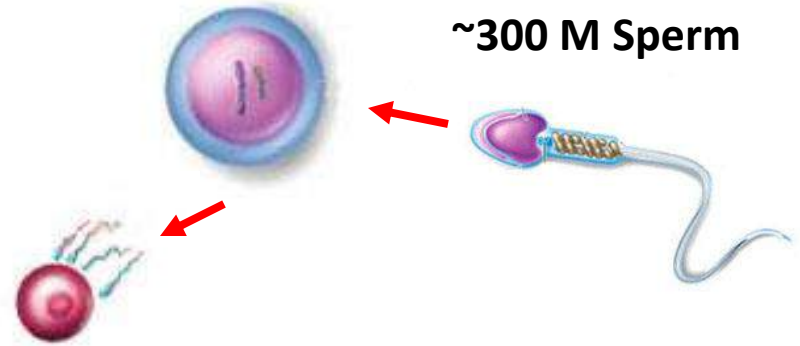
Sexual Reproduction: Some Background...

In **sexual reproduction**, a new individual is formed by the union of two **gametes** (oocyte and sperm)

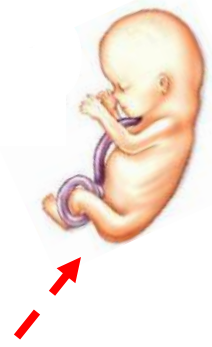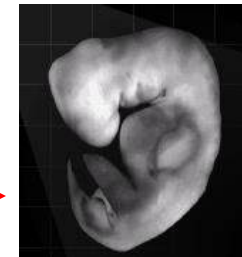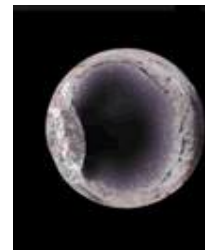
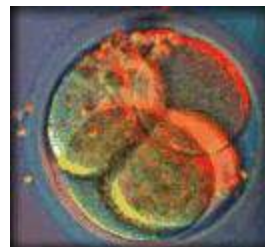
Gametes
(haploid)

1 oocyte

~300 M Sperm



Develops by mitosis to multi-cell



A zygote is formed

2 cell
0.1-0.2 mm

Blastocyst

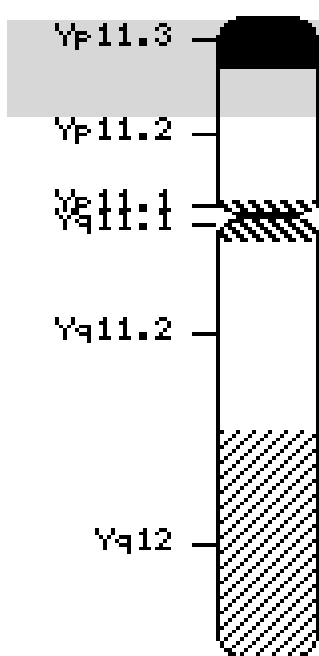
1 month
4-6 mm

Sex Determination

Deferensiasi seksual adalah proses kompleks yg melibatkan banyak gen

- Kuncinya adalah kromosom Y, mengandung faktor penentu testis
- *Gen dari kromosom Y akan menentukan jadi laki-laki atau perempuan*

Ideogram

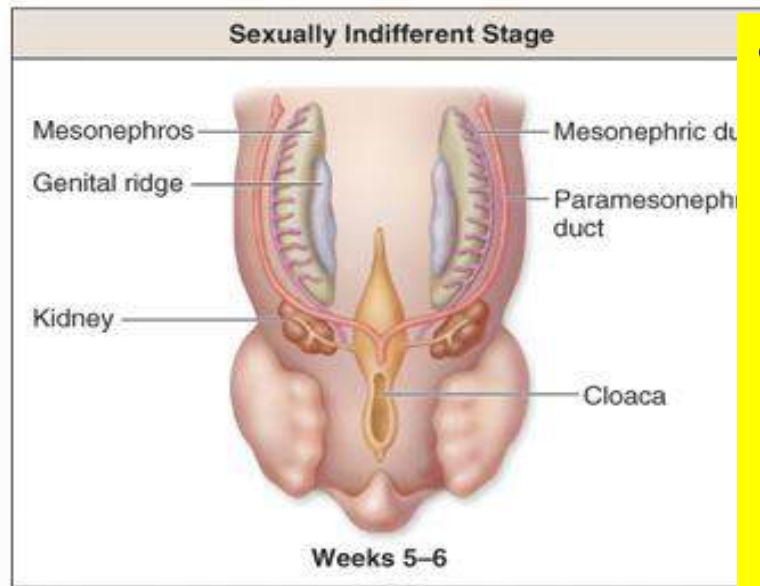


Responsible gene is *SRY*

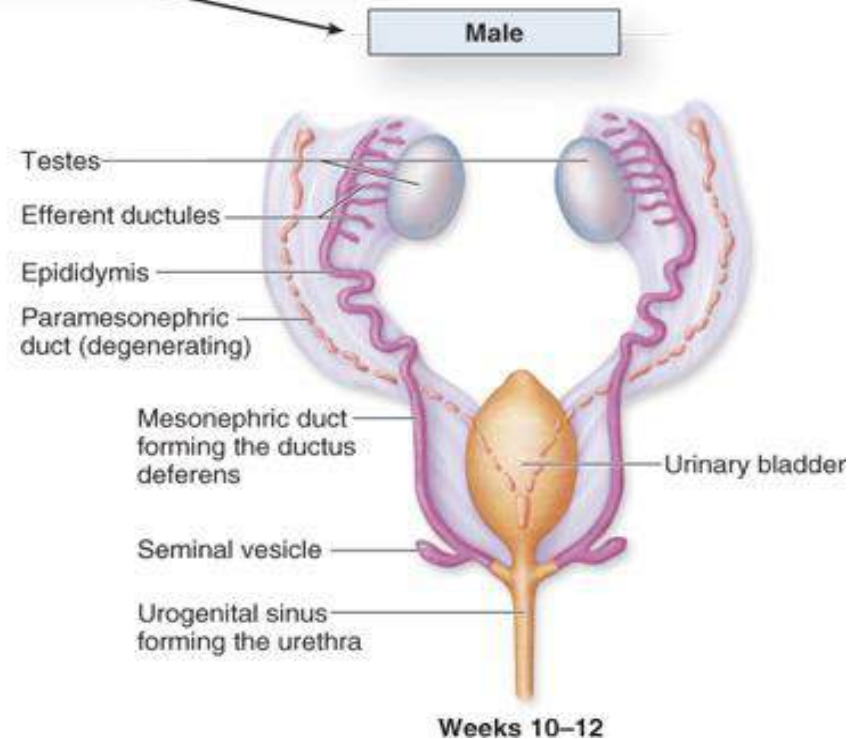
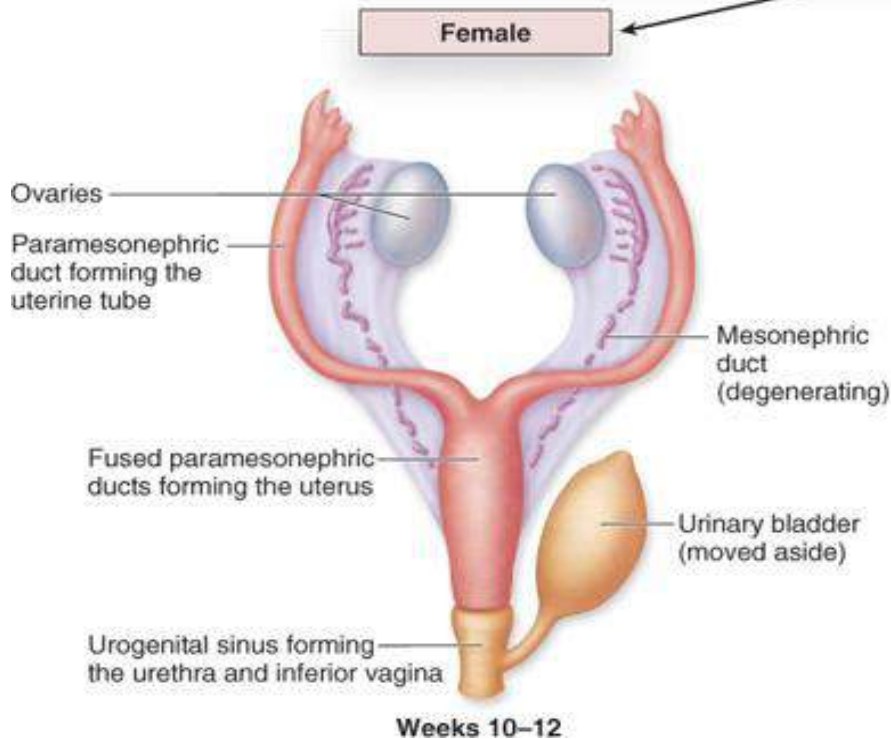
- **Sex-determining region of the Y chromosome**
- **Most famous gene: *SRY***

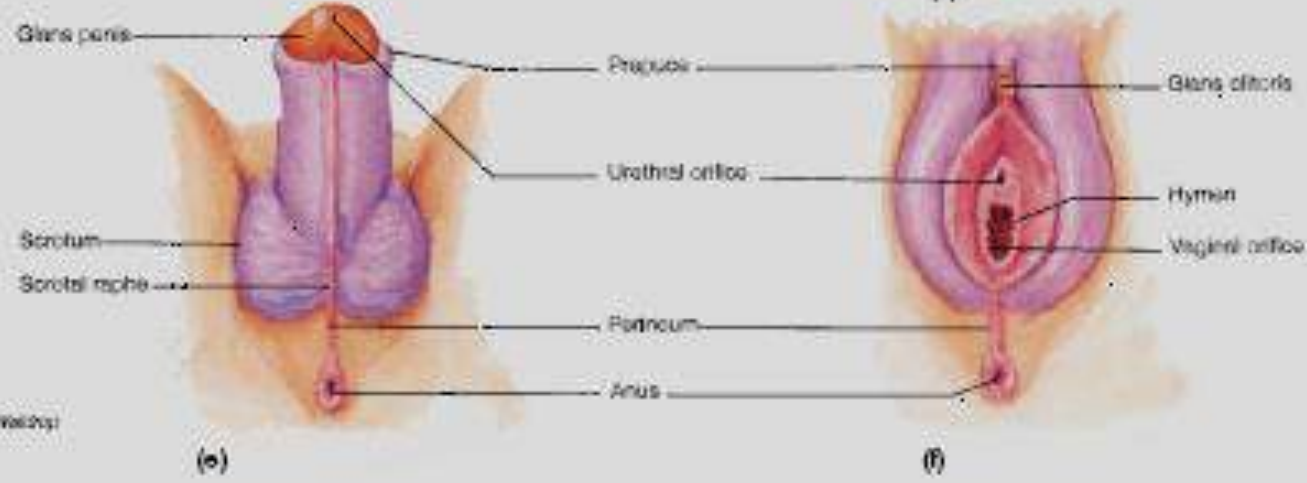
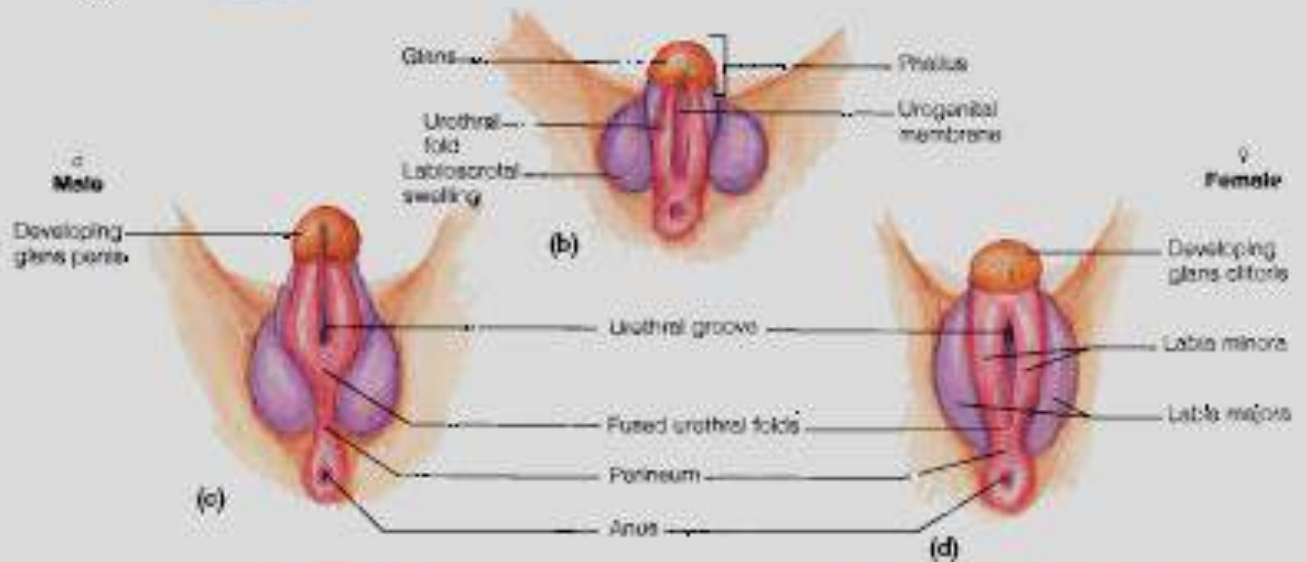
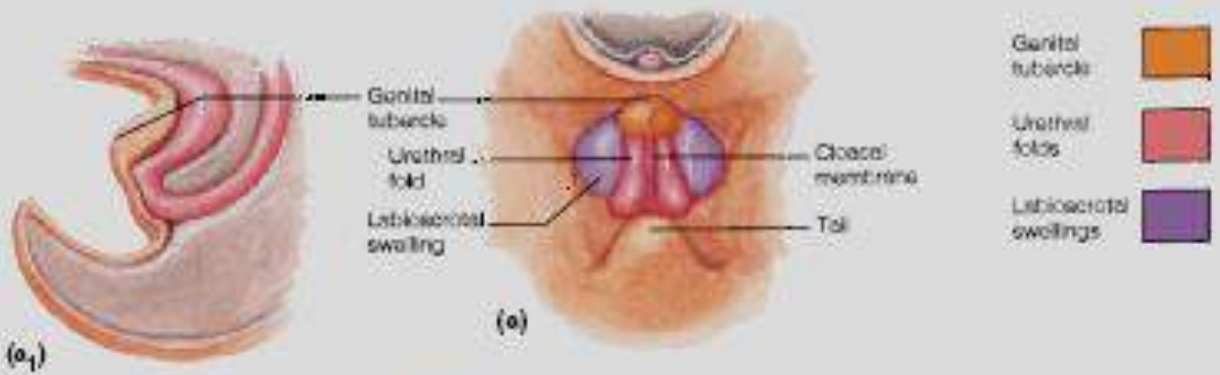
Y Chromosome

- Ridges → ovaries
- Müllerian ducts
 - Uterine tubes
 - Uterus
 - Superior vagina
- Wolffian ducts degenerate



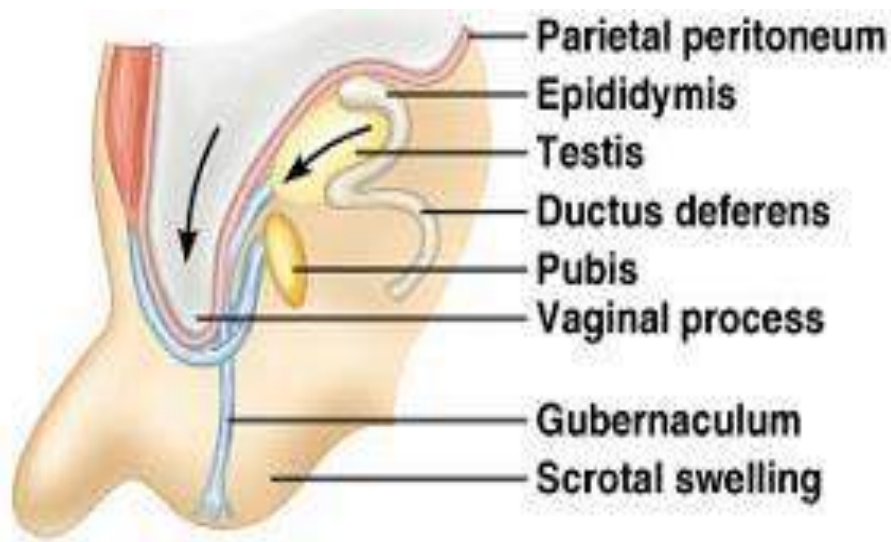
- Ridges → testes
 - Wolffian ducts
 - Epididymis
 - Ductus deferens
 - Ejaculatory duct
 - Müllerian ducts degenerate



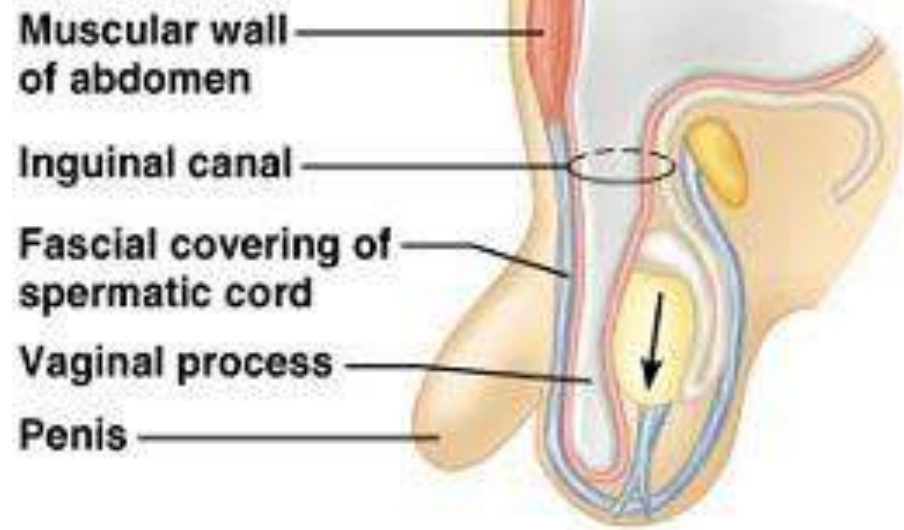


Genitalia externa

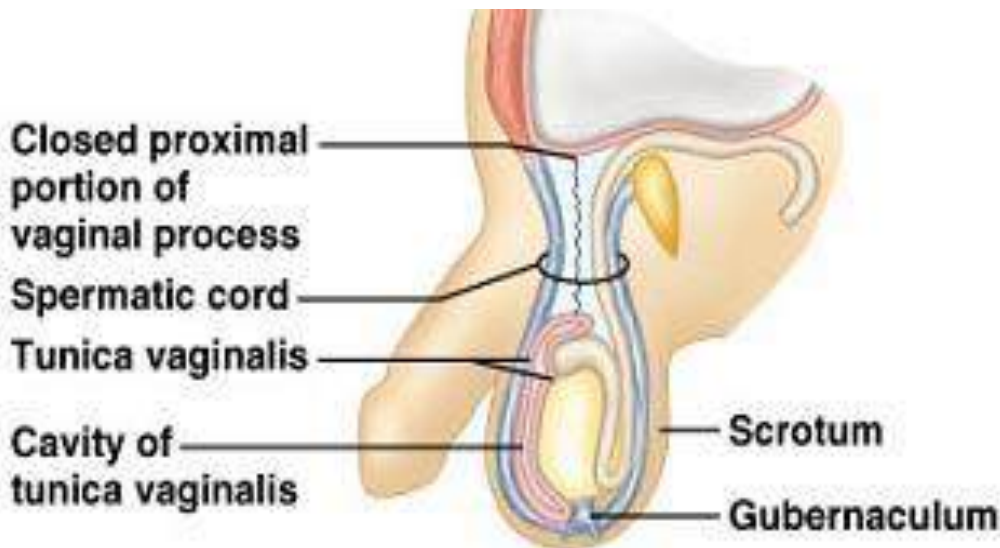- Kapan embrio berkembang menjadi laki-laki:
 - Perkembangan genitalia externa dipicu oleh dihydrotestosteron
 - Genital tubercle memanjang, disebut phallus (calon penis)
 - Phallus menarik urethral fold dan urethral groove
 - Akhir bulan ke 3 urethral groove menutup menjadi penis
 - Genital swelling menjadi scrotum



(a) 7-month fetus



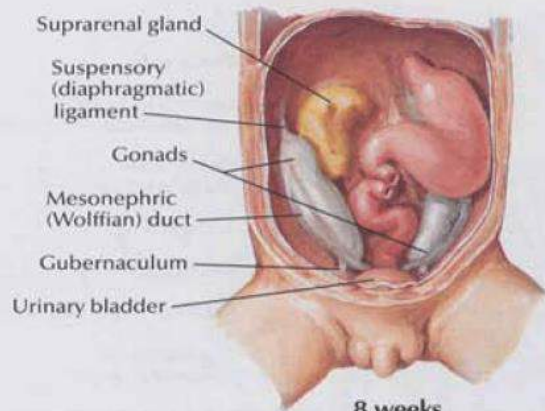
(b) 8-month fetus



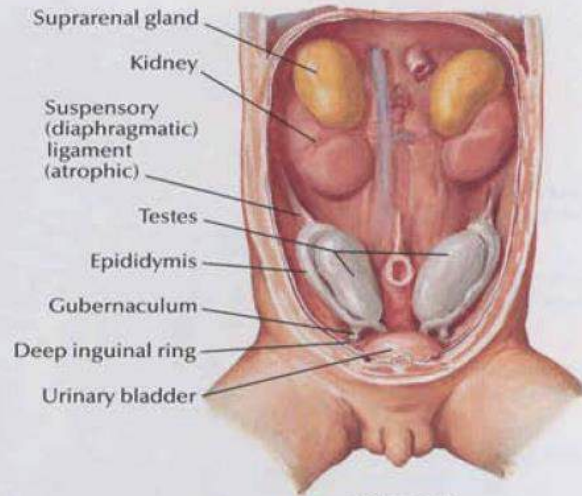
(c) 1-month old infant

- Through pelvis to scrotum
- Bring blood vessels and nerves
- Guided by gubernaculum
- Pushes through abdominal wall forming inguinal canal
- Vaginal process
 - Outpouching of peritoneum
 - Tunica vaginalis after closing off

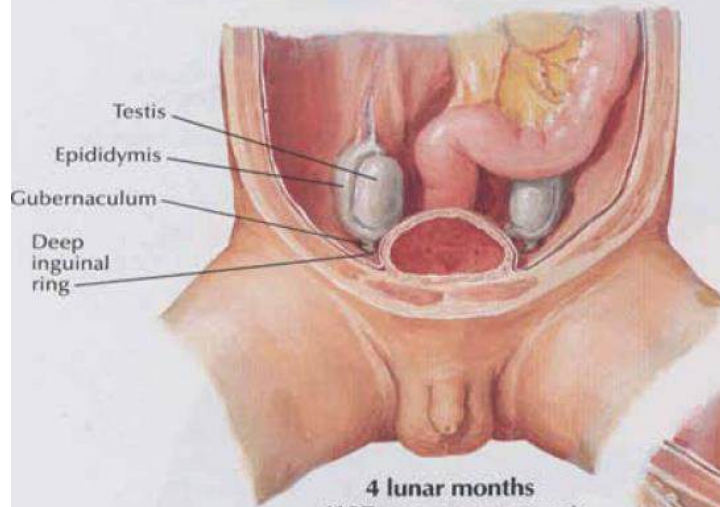
- Complete by 1 month post birth



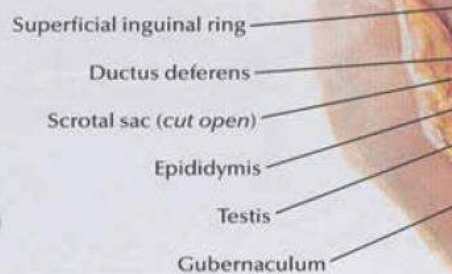
**8 weeks
 (22.5-mm crown rump)**



**11 weeks
 (43-mm crown rump)**



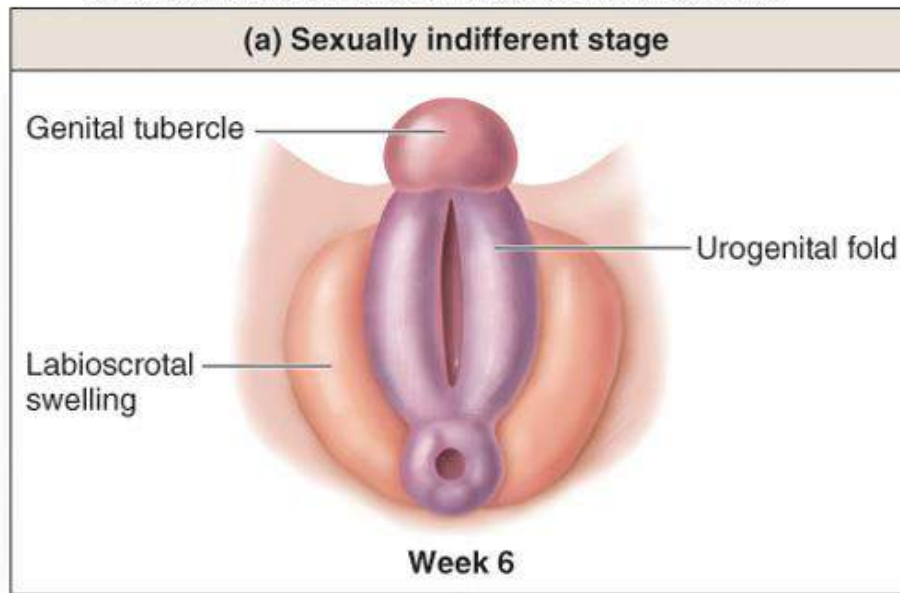
**4 lunar months
 (107-mm crown rump)**



**8 lunar months
 (26-cm crown rump)**

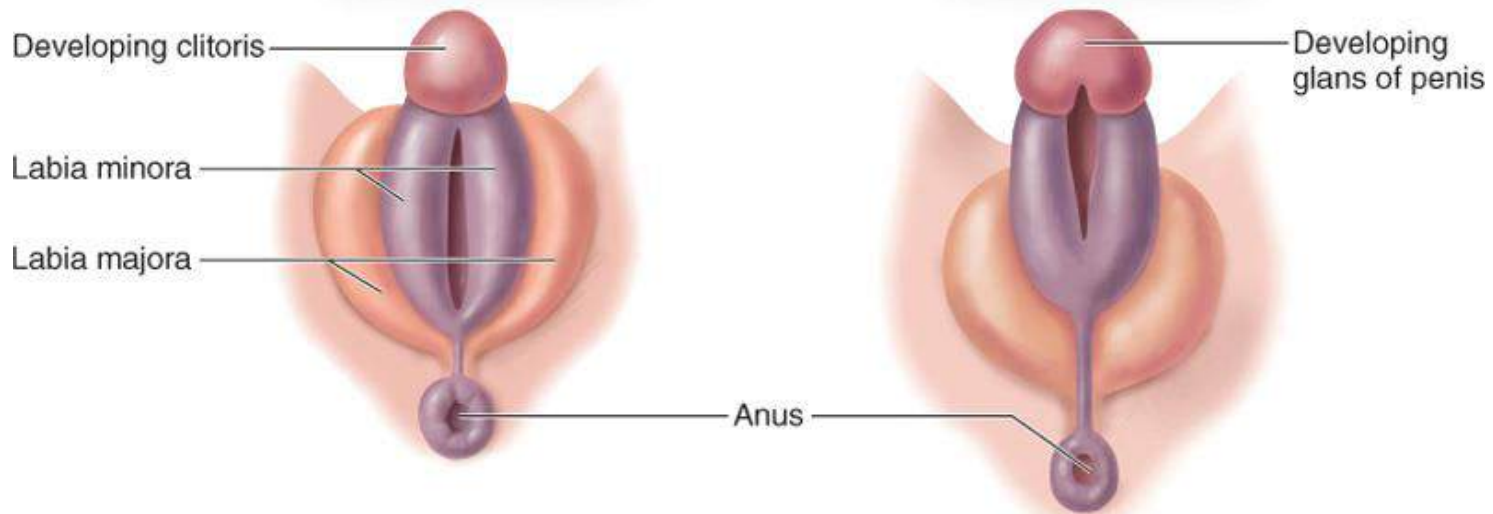
F. Netter M.D.
 © 1989

- Kapan embrio berkembang menjadi perempuan:
 - Genital tubercle memanjang hanya sedikit menjadi clitoris
 - Urethral fold tidak bersatu dan berkembang menjadi labia minora; urethral groove tidak menutup dan berkembang menjadi vestibulum vaginae



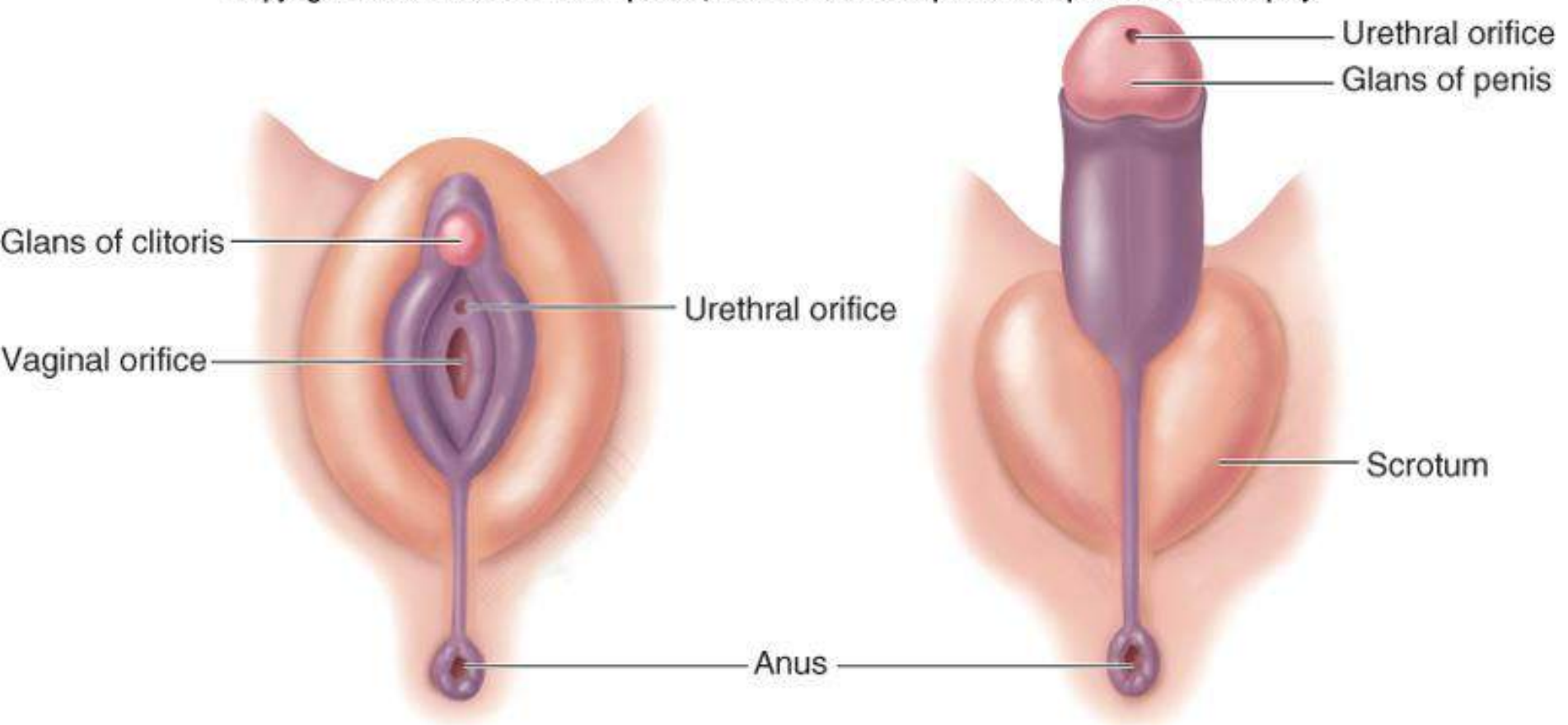
Female

Male

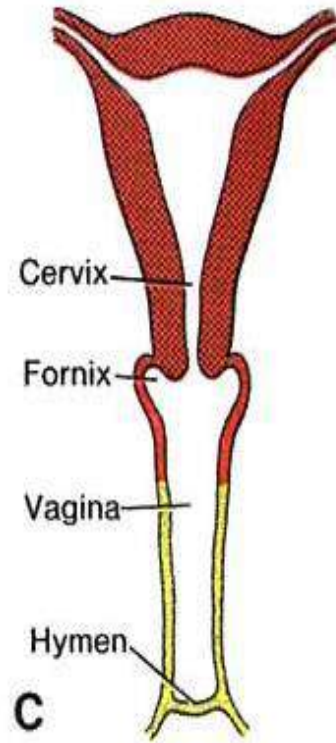
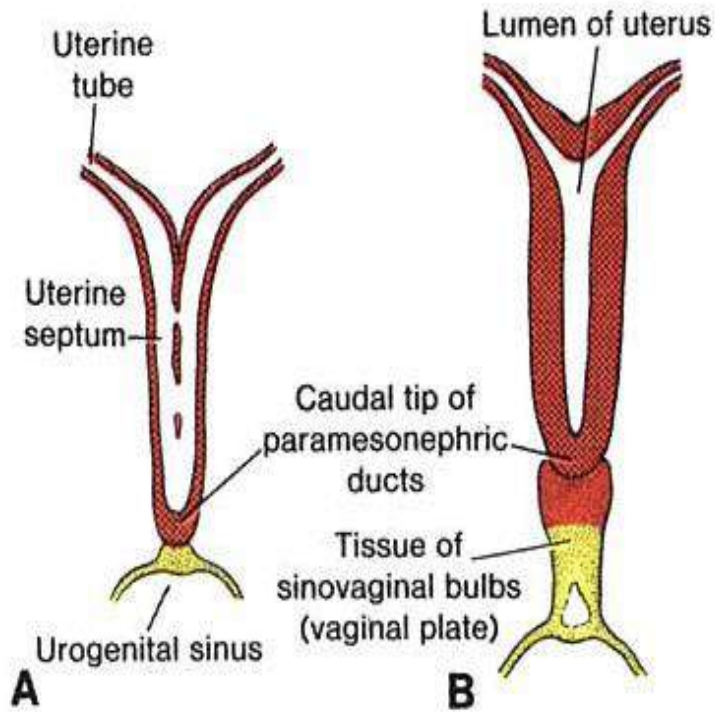


(b) Week 12: Urogenital folds begin to fuse in the male

Copyright © The McGraw-Hill Companies, Inc. Permission required for reproduction or display.



(c) Week 20: External genitalia well differentiated



Vagina

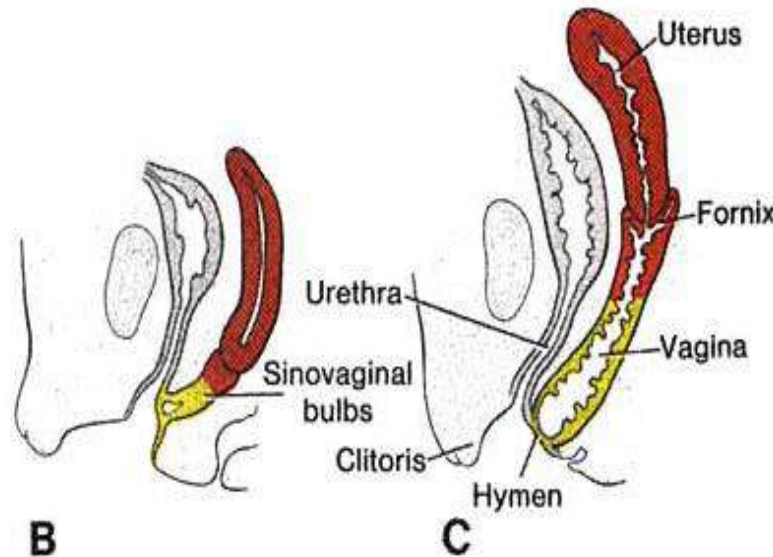
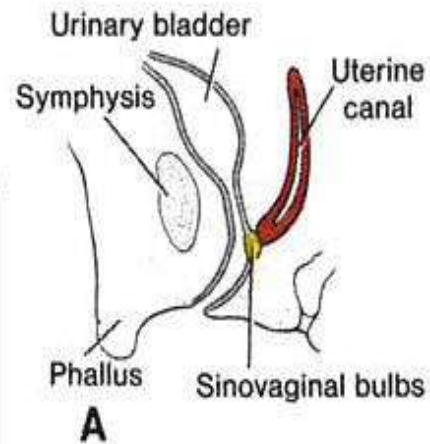
-Di tempat menempelnya duct of Muller timbul **sinovaginal bulb** membentuk vaginal plate (solid)

-**Sinovaginal bulb** memanjang di dalamnya timbul vacuole, membentuk lumen

-Diperbatasan dengan SUG masih terpisah jaringan tipis : hymen

-Bagian proximal : fornix vaginae terjadi dari Duct of Muller

-Jadi vagina terjadi dari : Duct of Muller (1/3 bagian proximal) dan SUG (2/3 bagian distal)



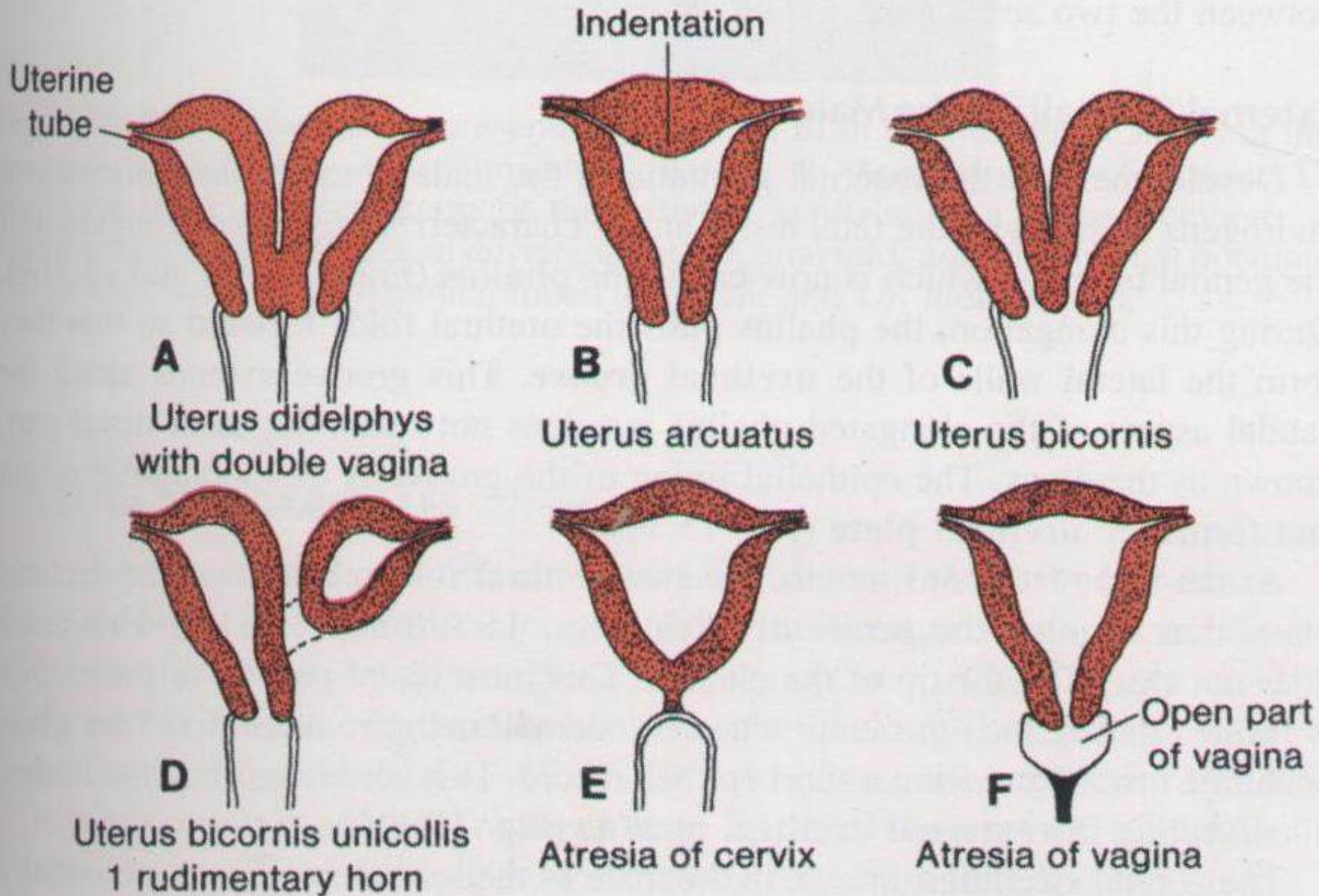
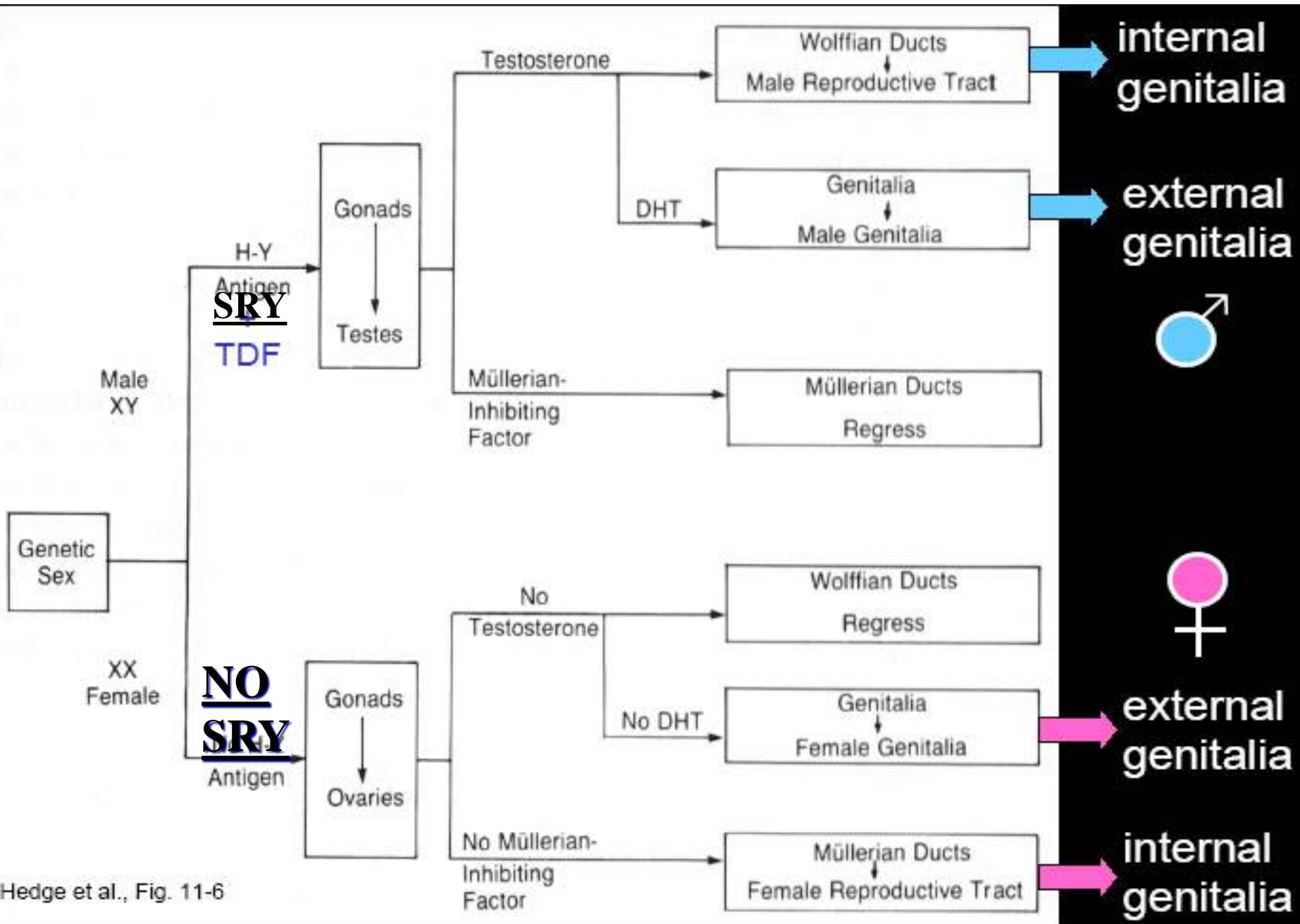


Figure 15 28 Schematic representation of the main abnormalities of the uterus and

Table 28.1

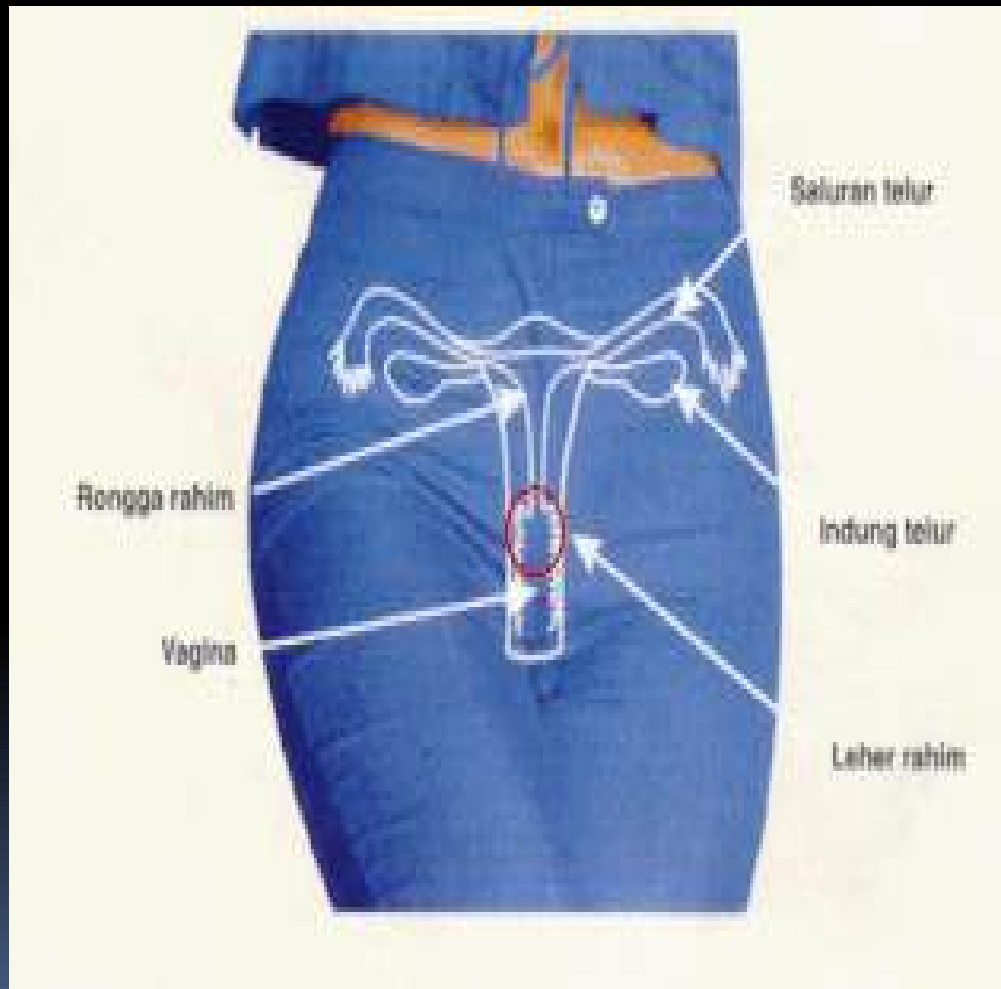
Reproductive System Homologues

Female Organ	Male Organ Homologue	Common Function
Ovary	Testis	Produce gametes and sex hormones
Clitoris	Glans of penis	Contain autonomic nervous system axons that stimulate arousal and sexual climax feelings
Labia majora	Scrotum	Protect and cover some reproductive structures
Vestibular glands	Bulbourethral glands	Secrete mucus for lubrication



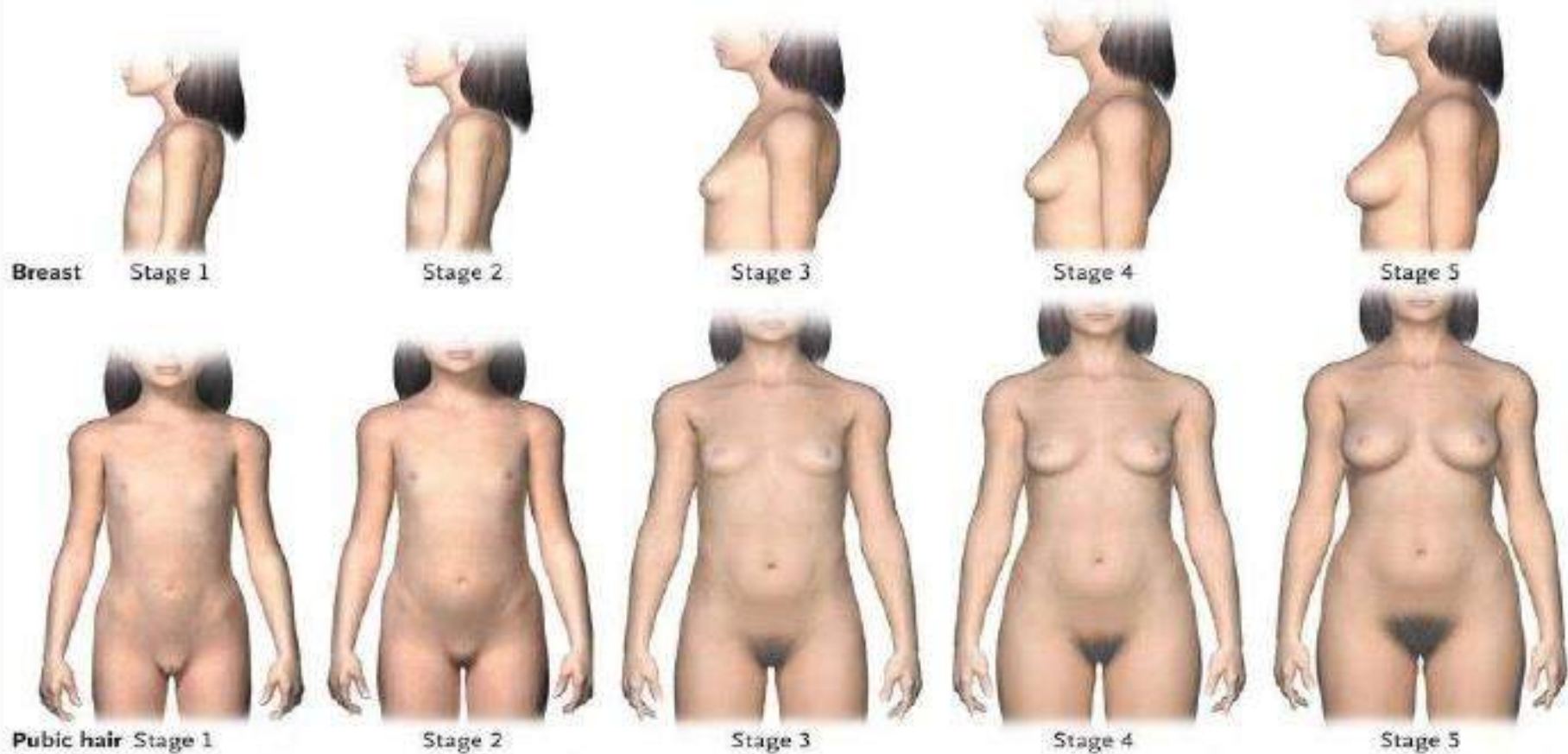
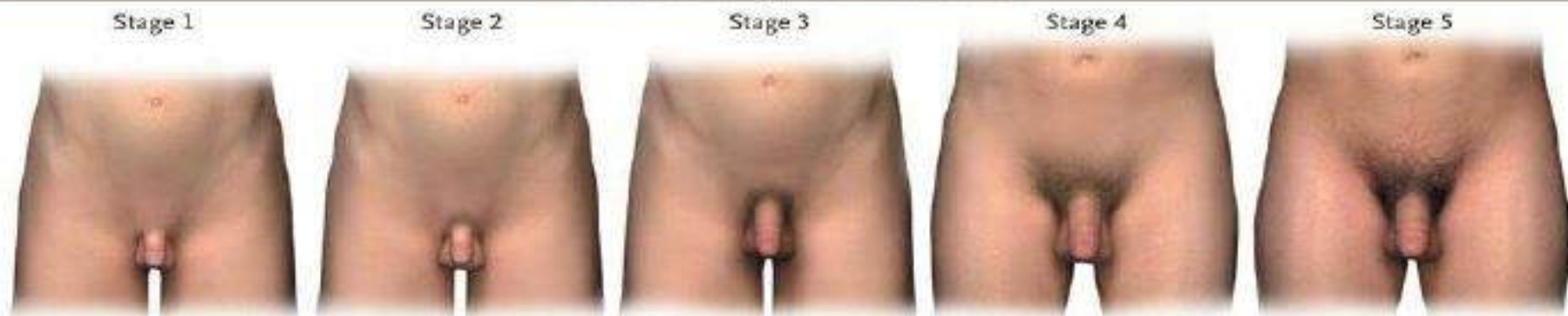
Hedge et al., Fig. 11-6

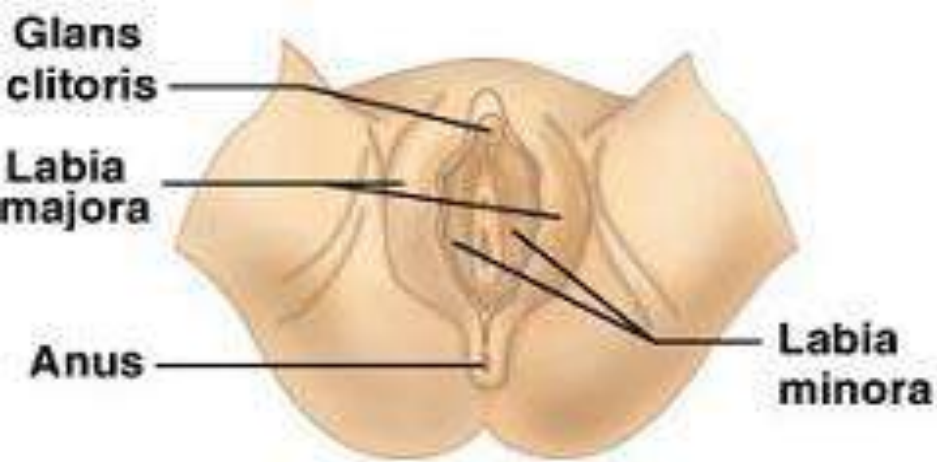
Organa Genitalia Femina



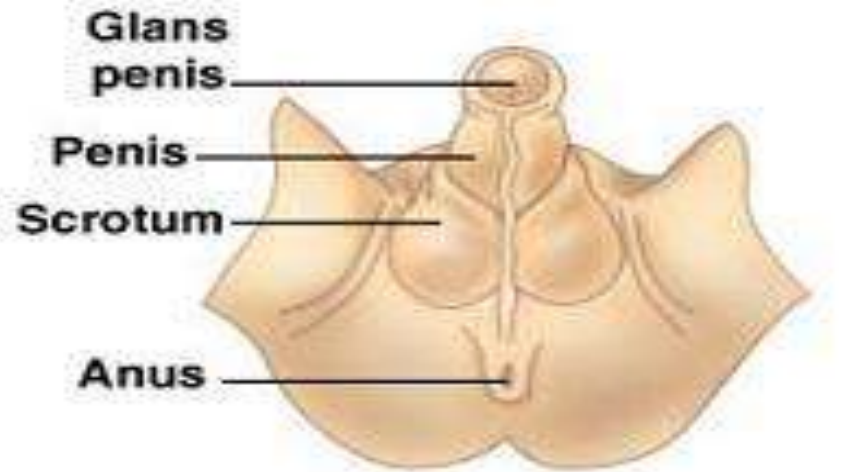
Female Reproductive Organs

- Primary sex organ
 - Ovary
- Secondary or accessory sex organs
 - External genitalia or vulva
 - Labia majora
 - Labia minora
 - Clitoris
 - Mons pubis
- Secondary or accessory sex organs
 - Internal genitalia
 - Ducts
 - Oviducts
 - Uterus
 - Vagina
 - Glands
 - Greater vestibular gland

A**Breast Development and Pubic Hair****B****Genital Development and Pubic Hair**

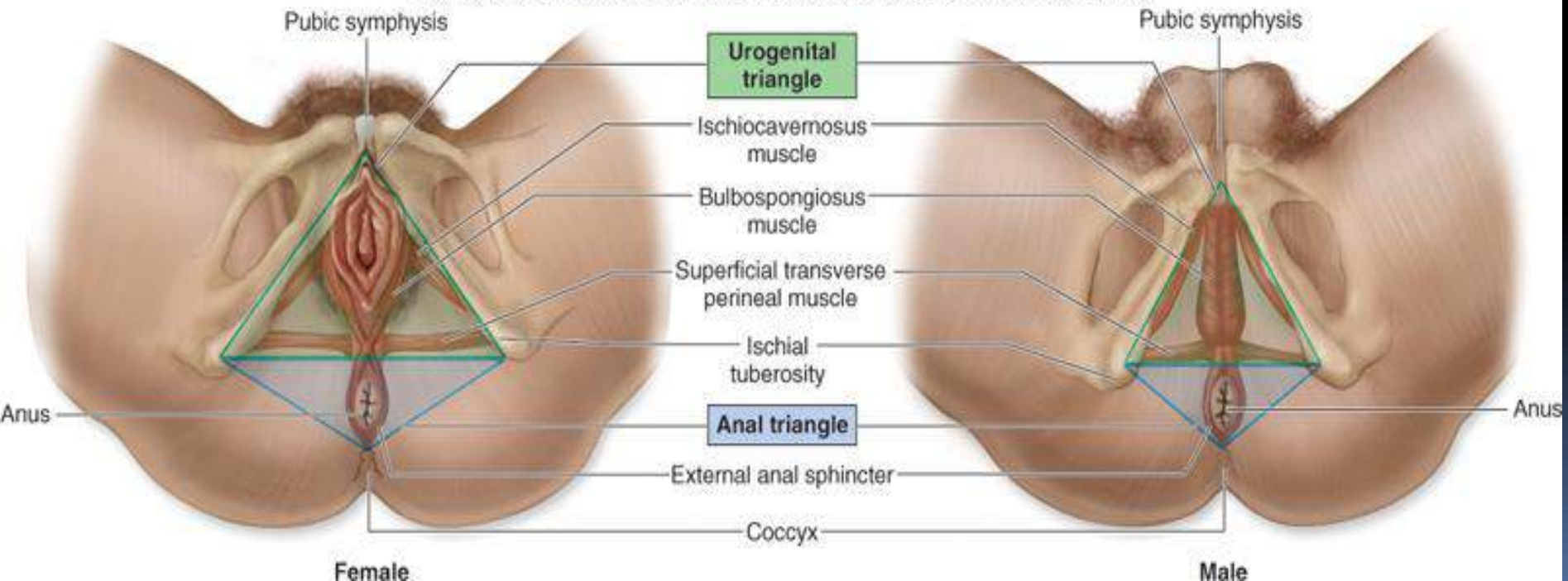


Female development

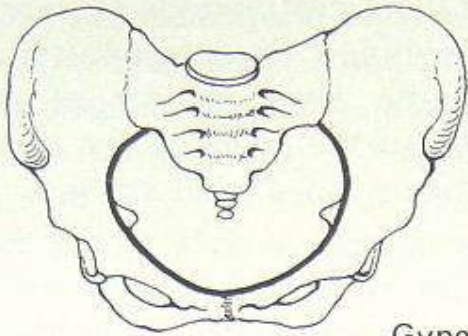


Male development

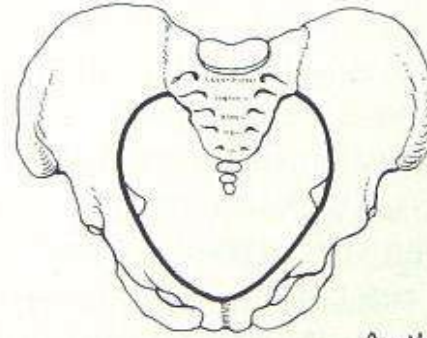

Copyright © The McGraw-Hill Companies, Inc. Permission required for reproduction or display.



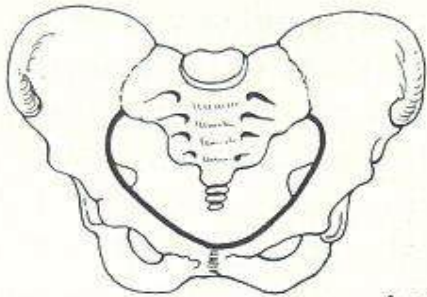

Bentuk Panggul perempuan



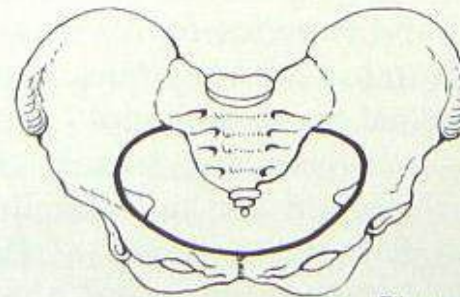
Gynecoid




Anthropoid



Android

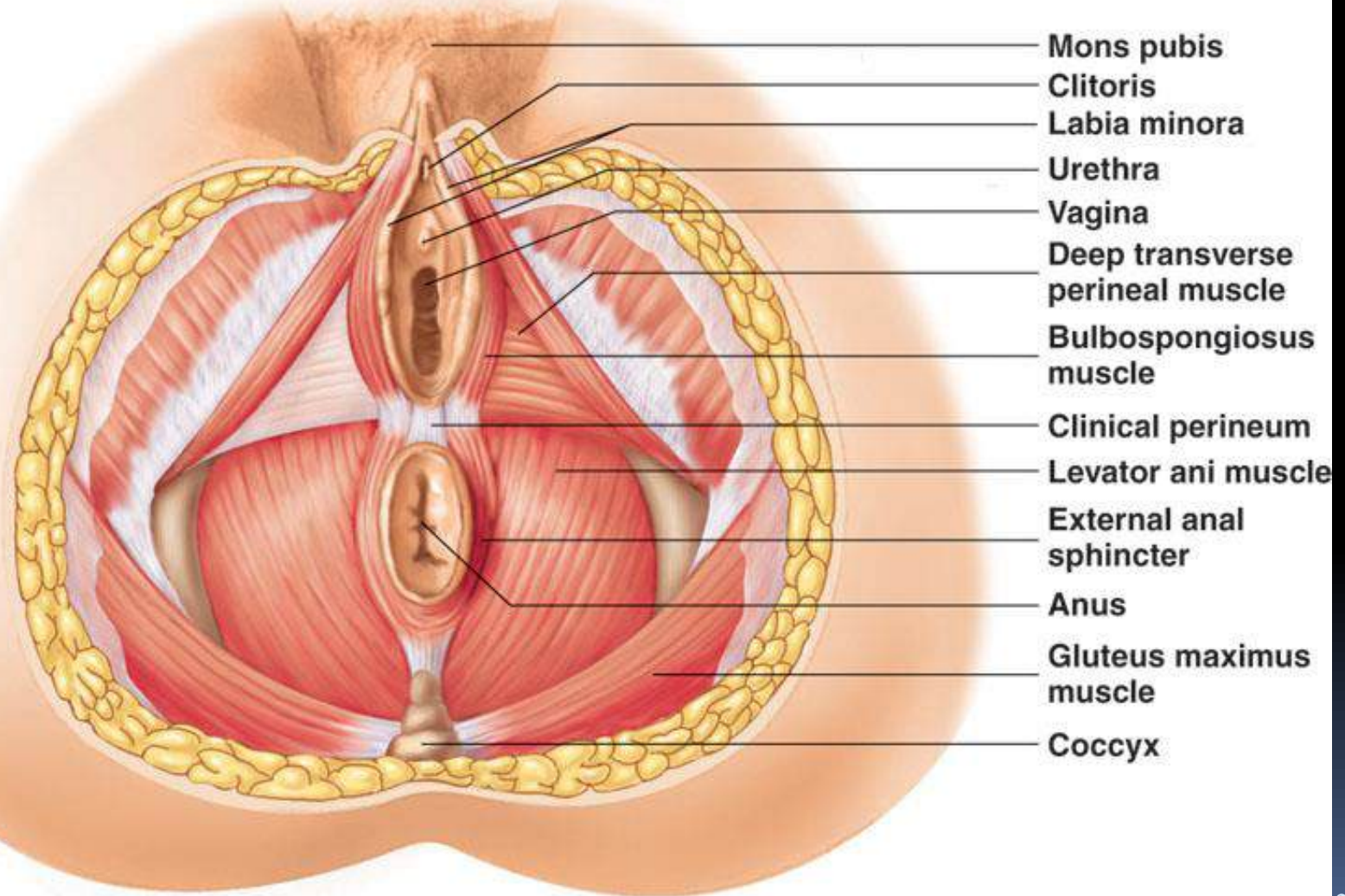


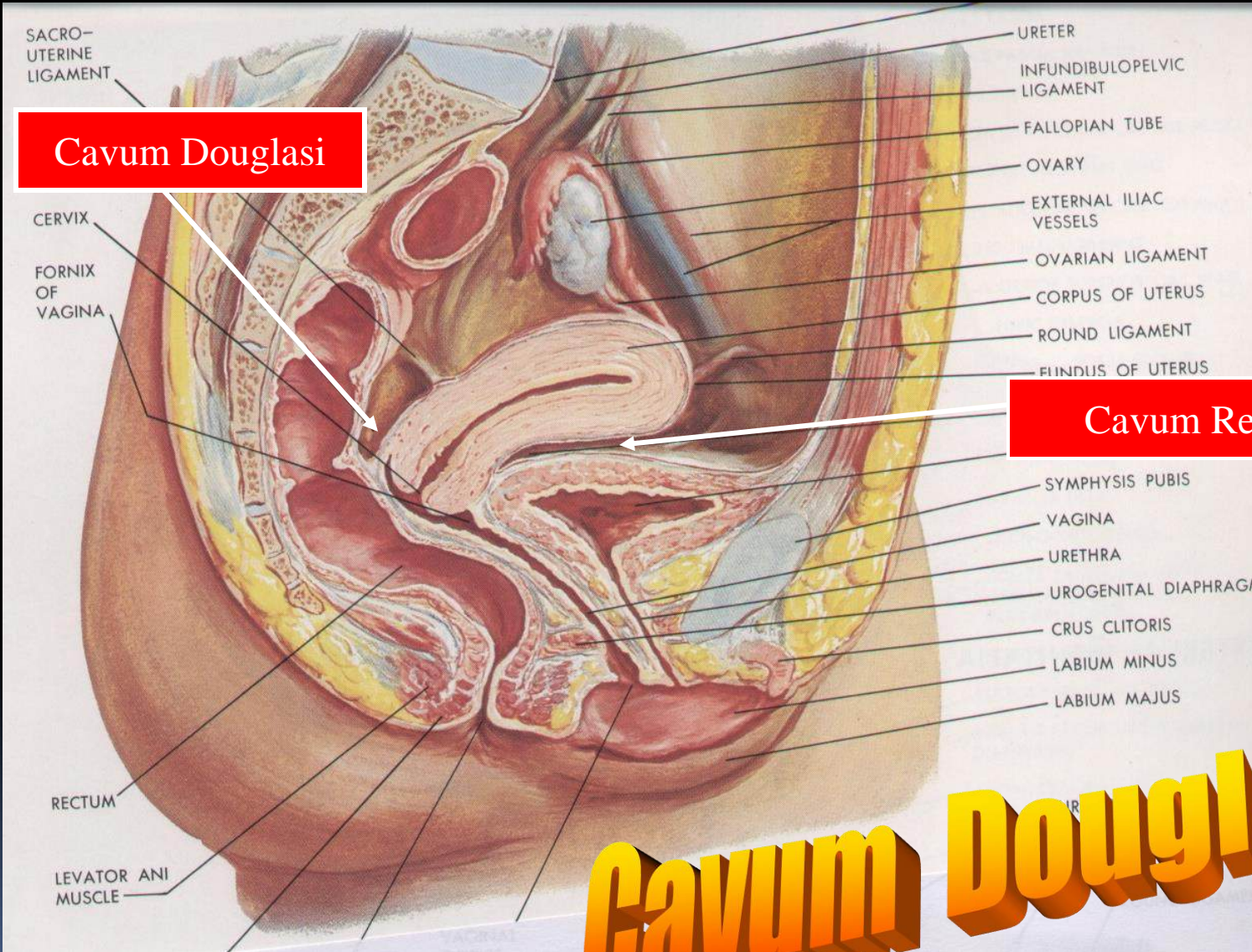
Platypelloid



Perineum

Copyright © The McGraw-Hill Companies, Inc. Permission required for reproduction or display.

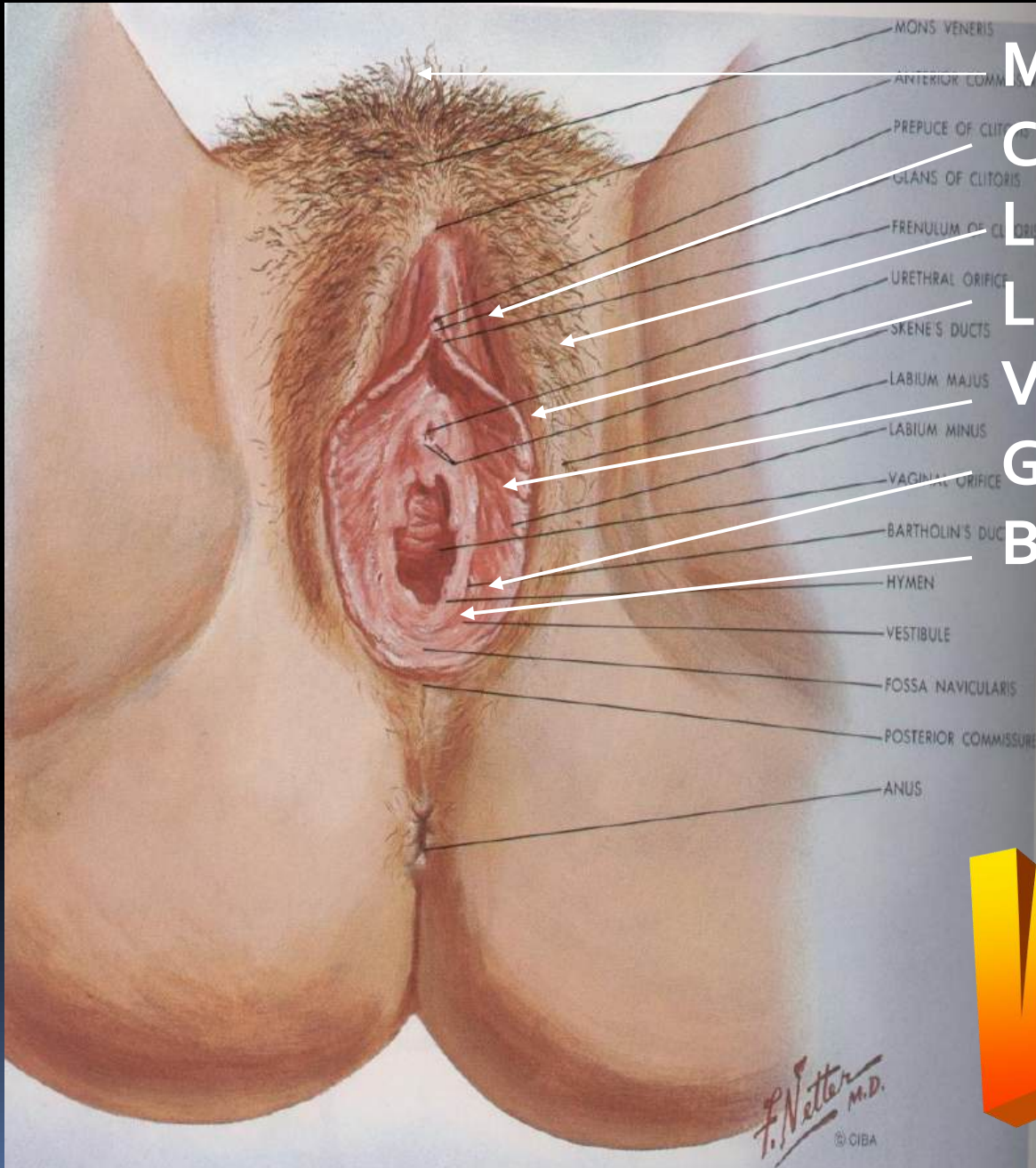



Cavum Douglasii

Cavum Retzii

Cavum Douglasii



Mons Pubis

Clitoris

Labia majora

Labia minora

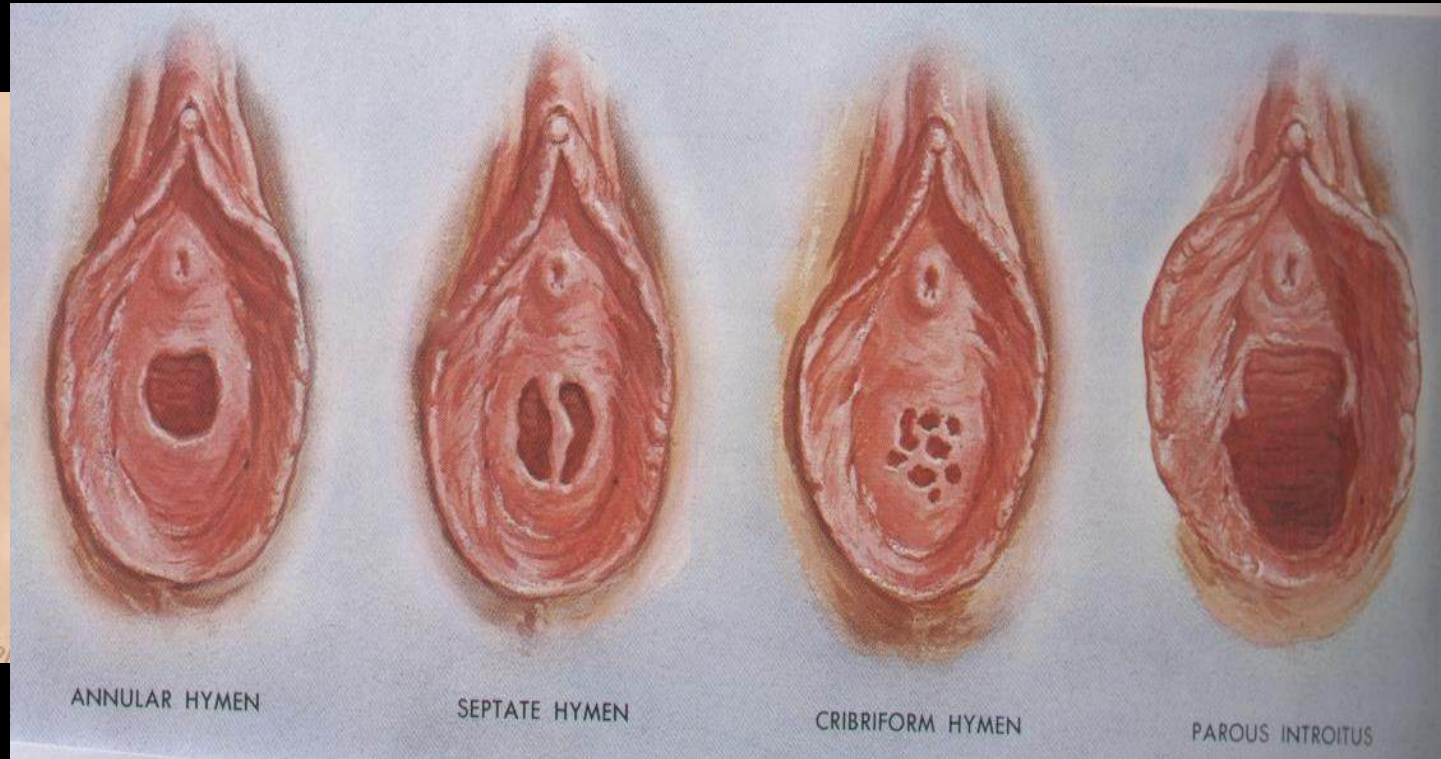
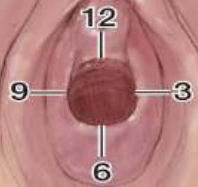Vestibulum vaginae

Gld. vestib. major

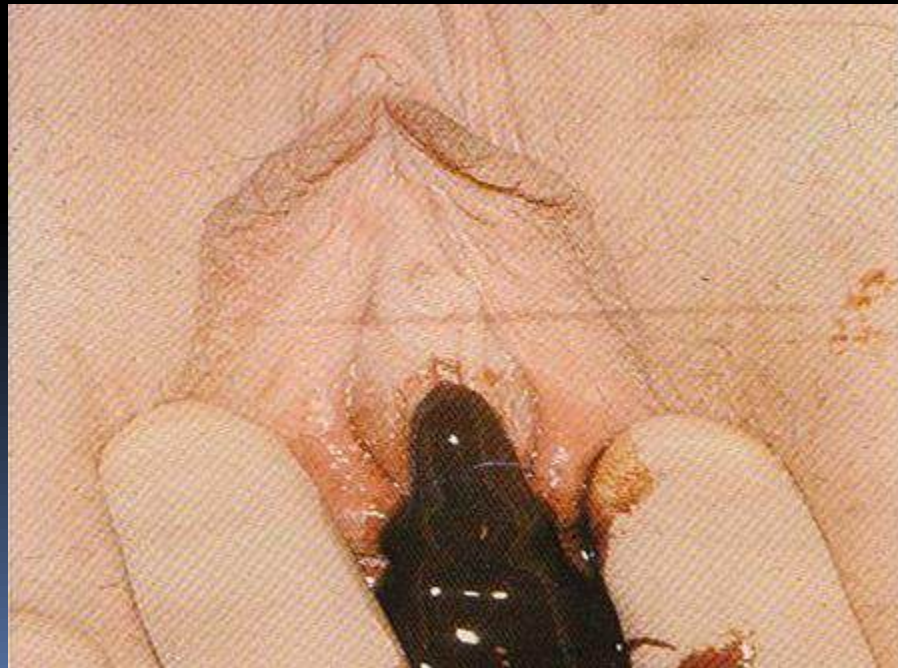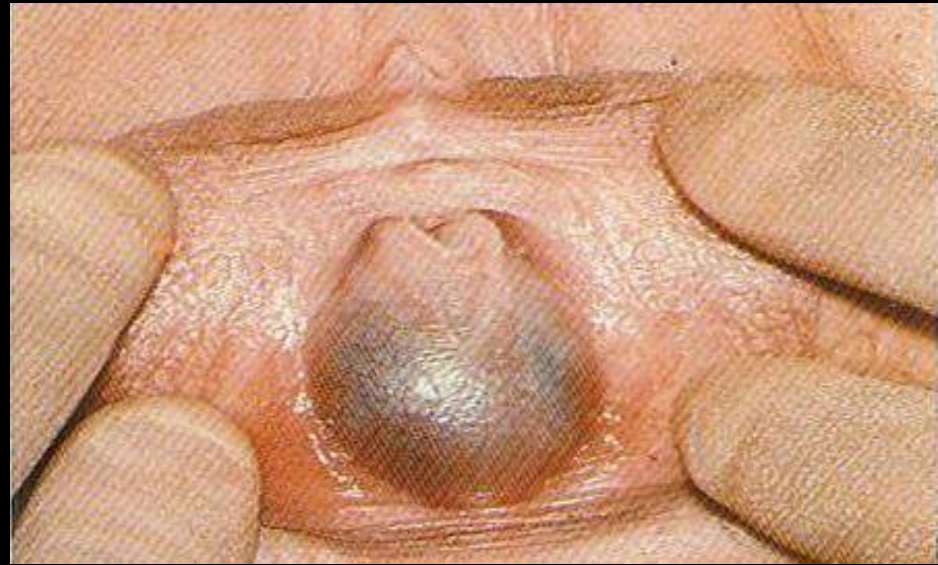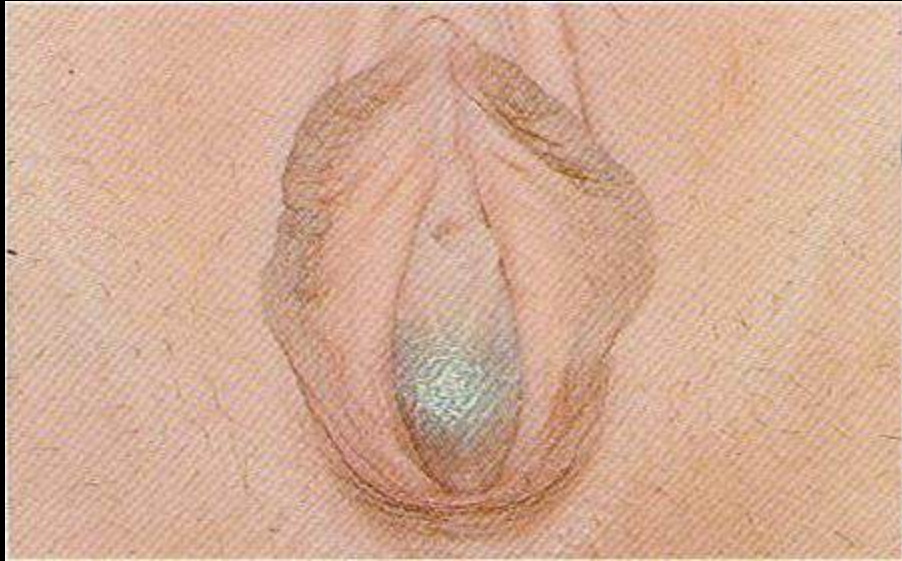
Bulbus vestibuli

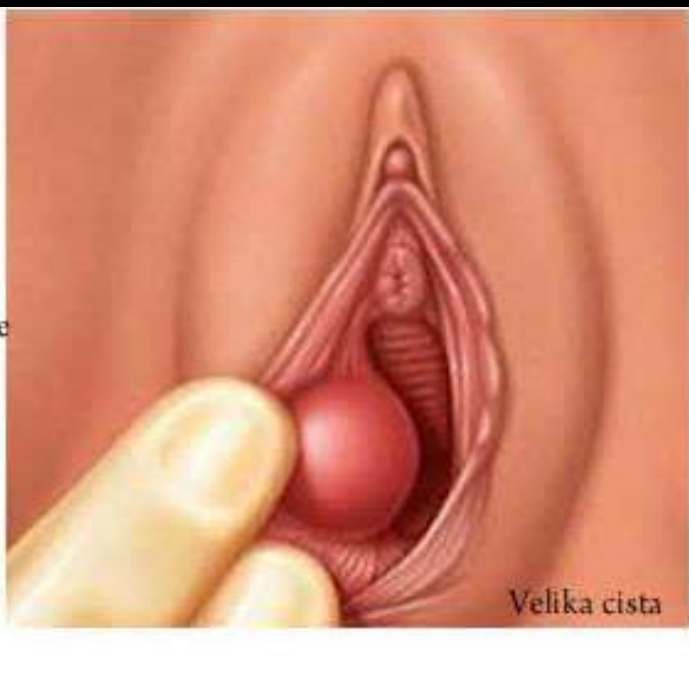
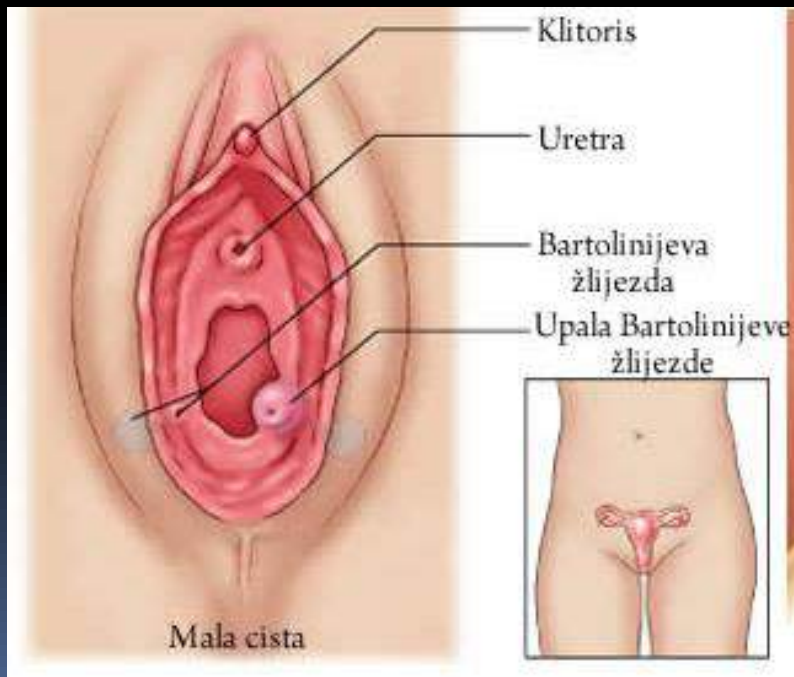
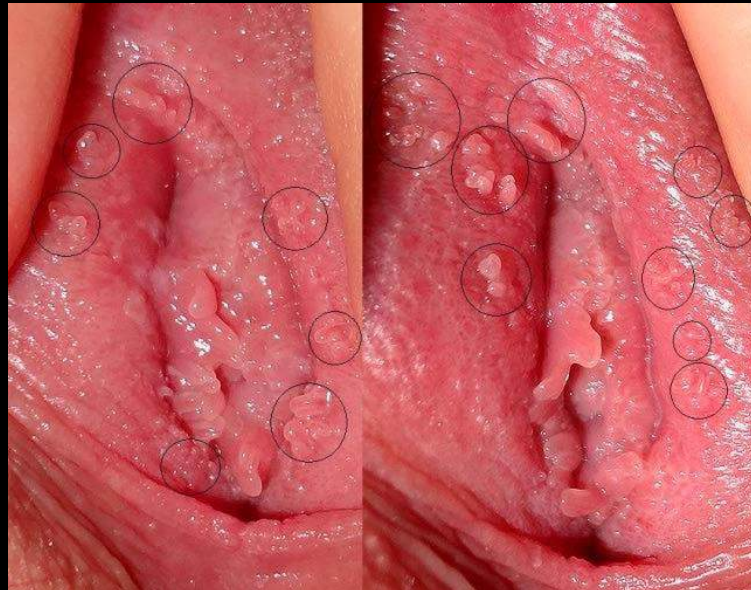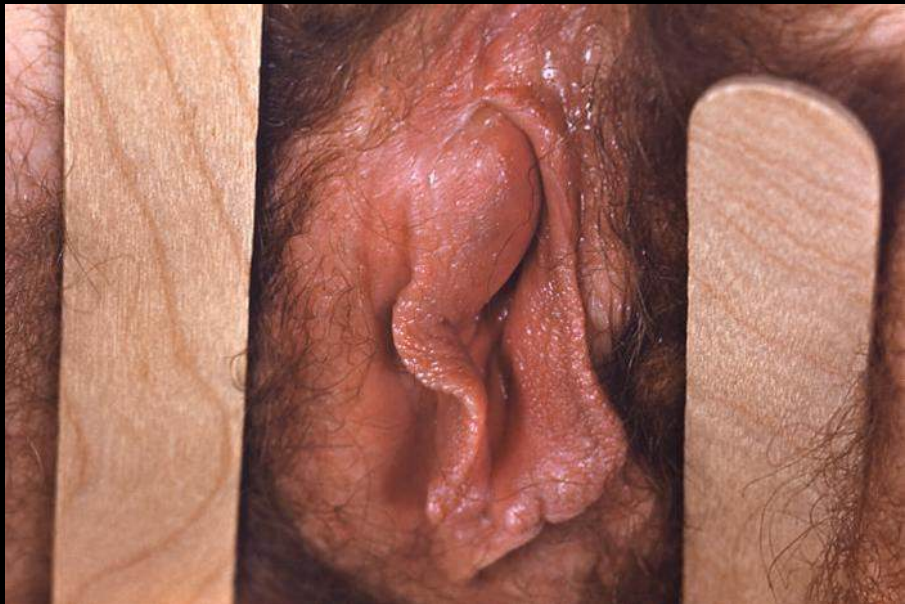Vulva

Clock-face diagram



HYMEN





Vagina (1): Bagian

- **Fornix vaginalis**
 - Anterior
 - Posterior → terdalam, berhubungan dgn.cavum douglasi
 - Lateralis
- **Hymen :**
 - Lipatan tempat masuk vagina kedlm vestibulum vaginae
 - Bentuk : annulare, crescent, cribriformis, imperforata, septata,
 - Sesudah partus : introitus parous
 - Caruncula hymenalis pada multipara
- Pada partus, bersama uterus berfungsi sebagai “ birth canal “

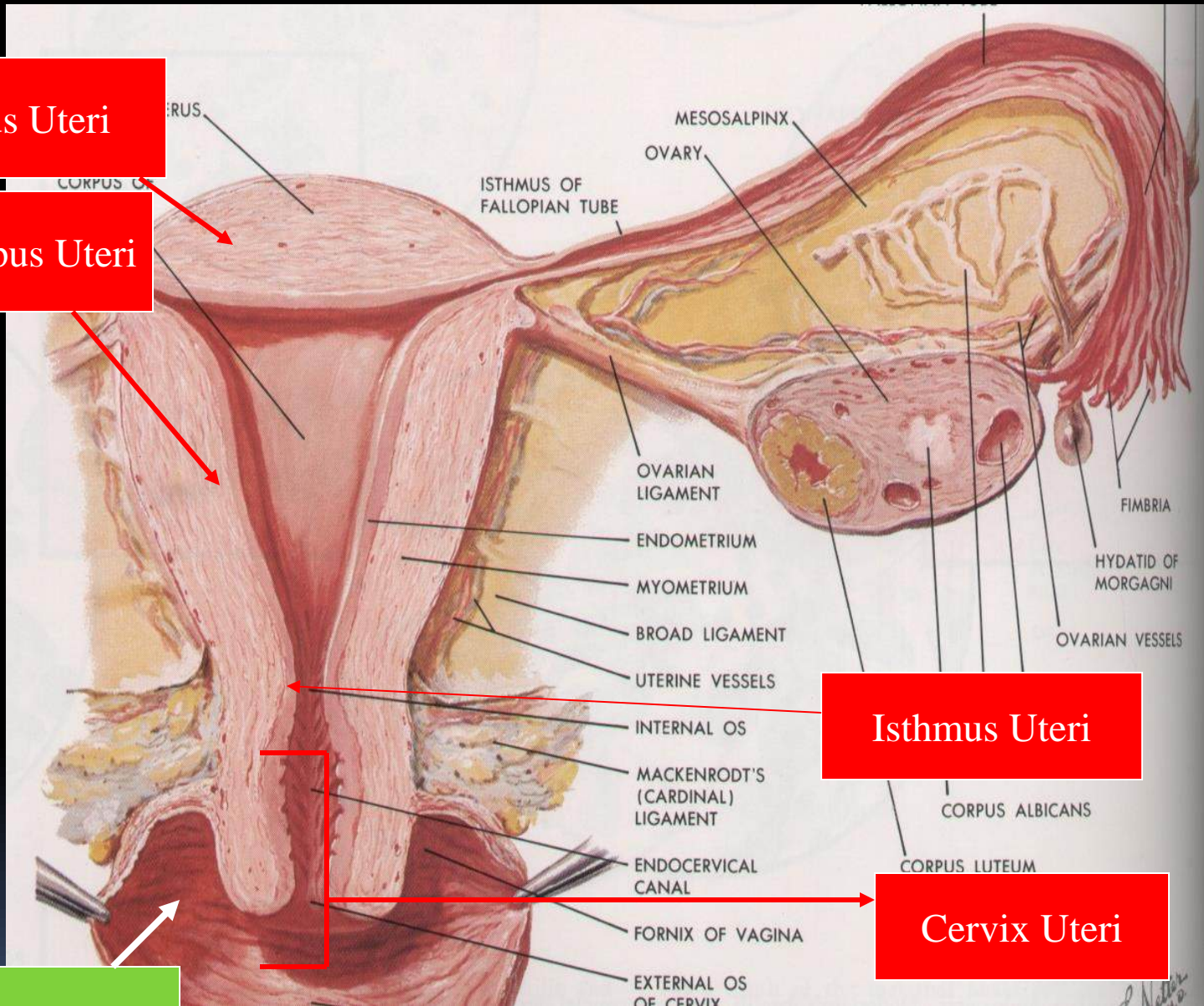
Fundus Uteri

Corpus Uteri

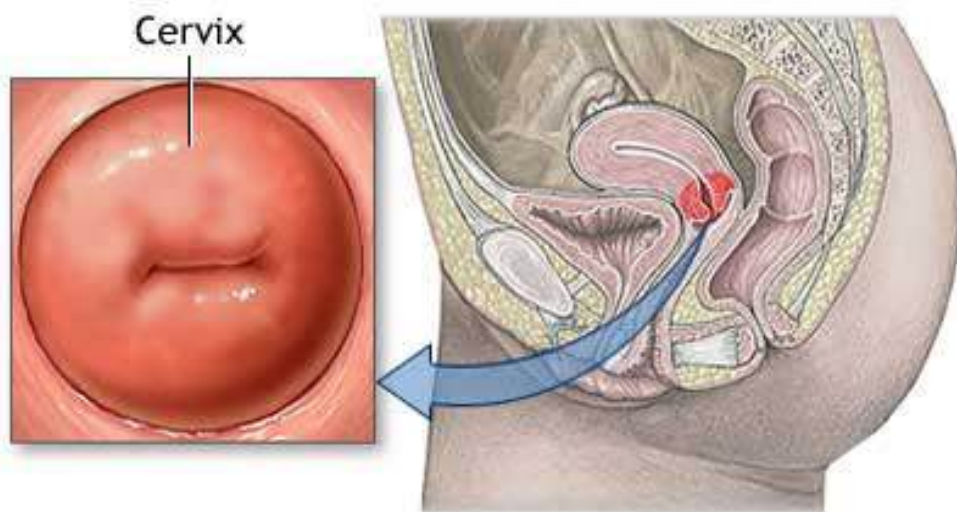
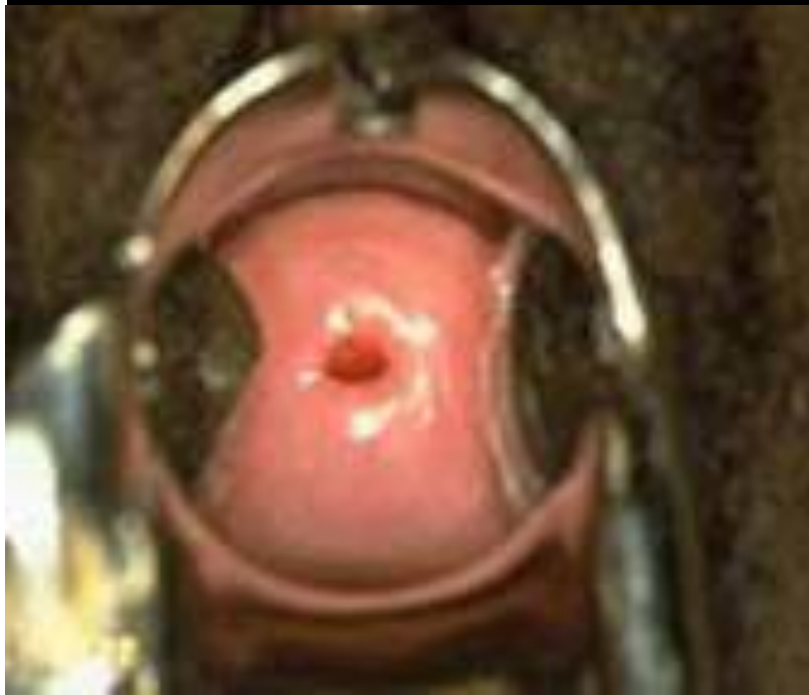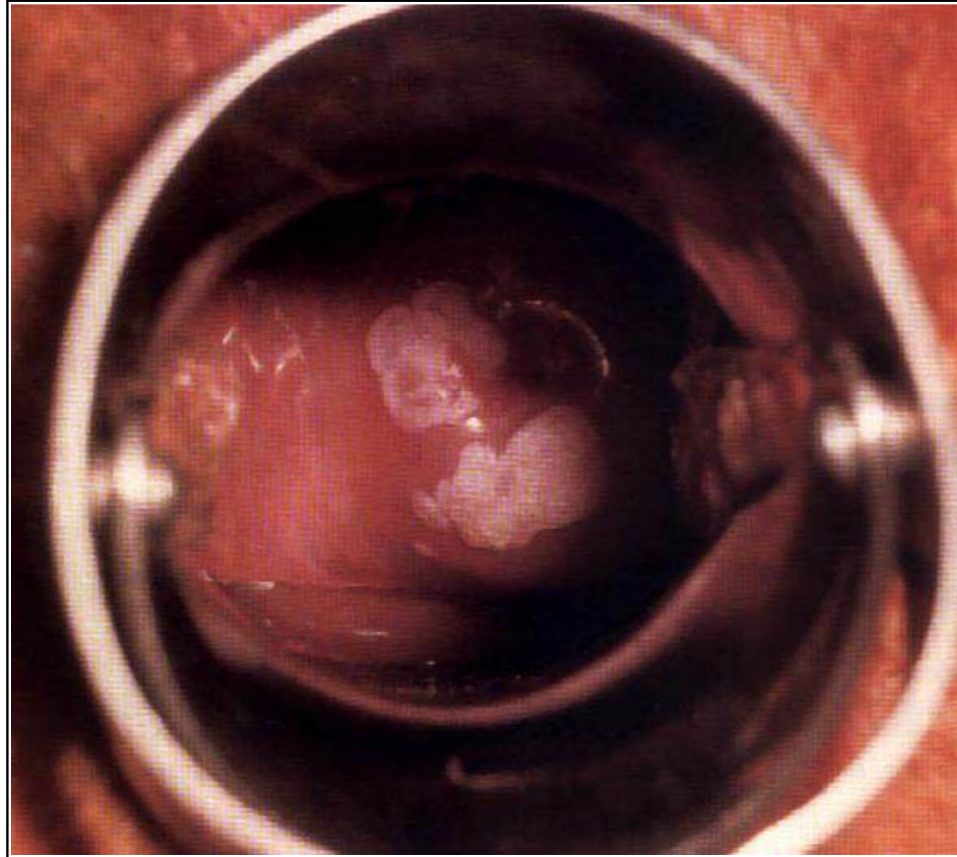
Isthmus Uteri

Cervix Uteri

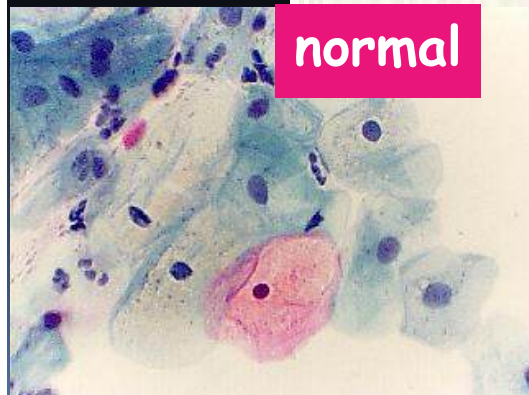
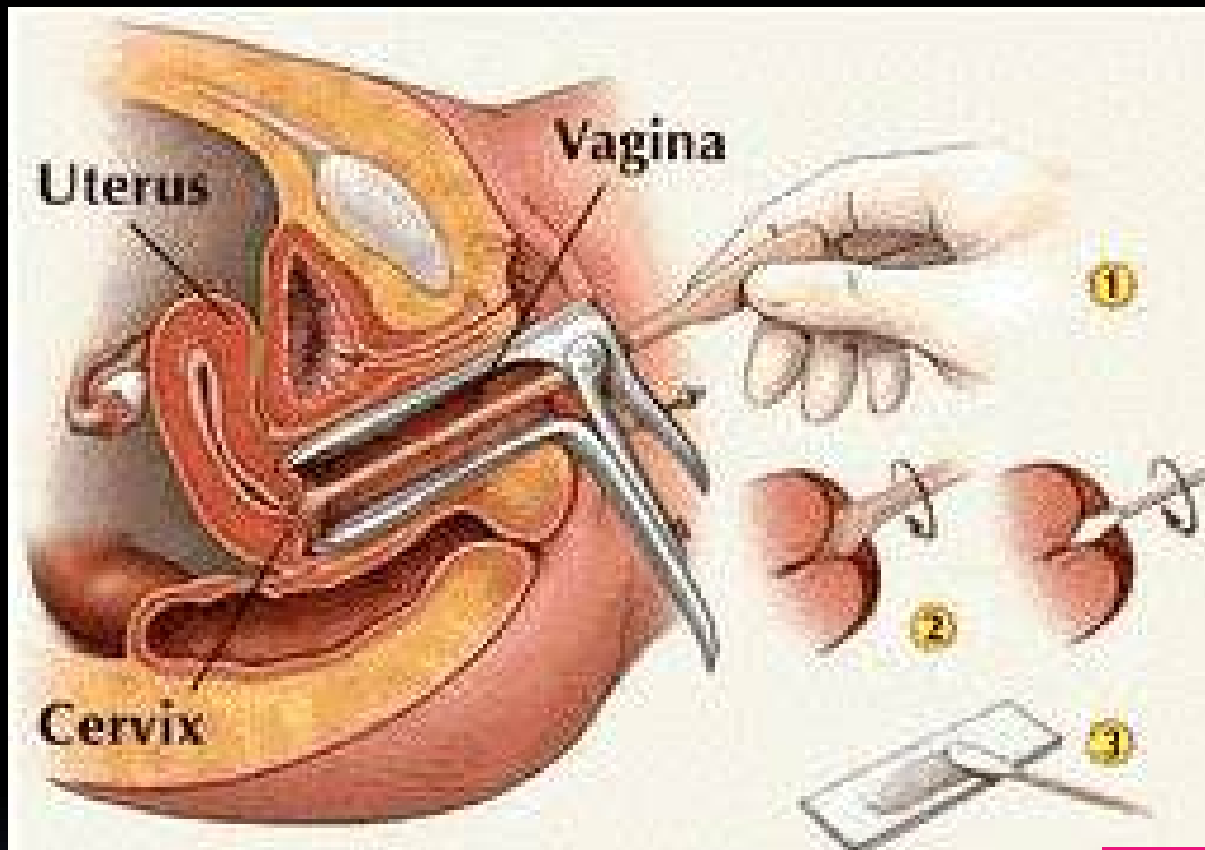
VAGINA



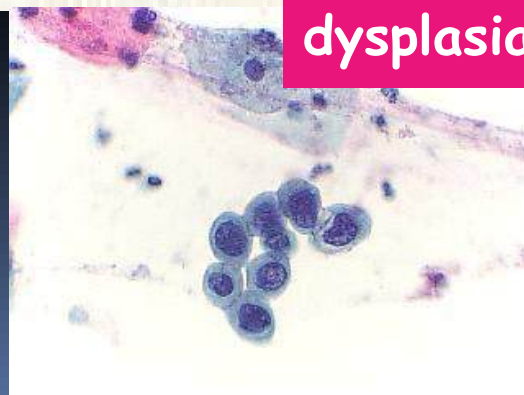The Cervix



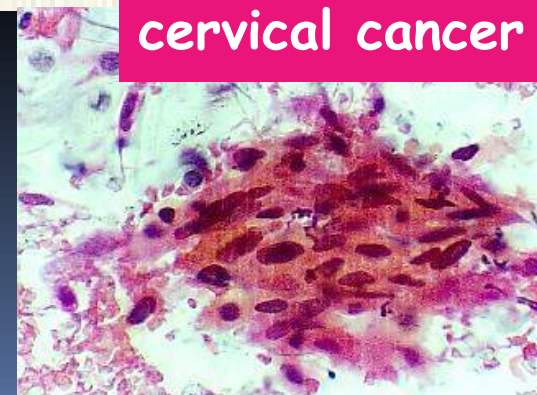
The Pap Smear



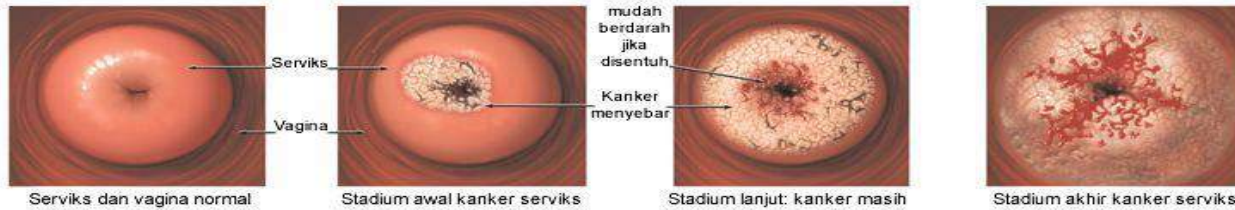
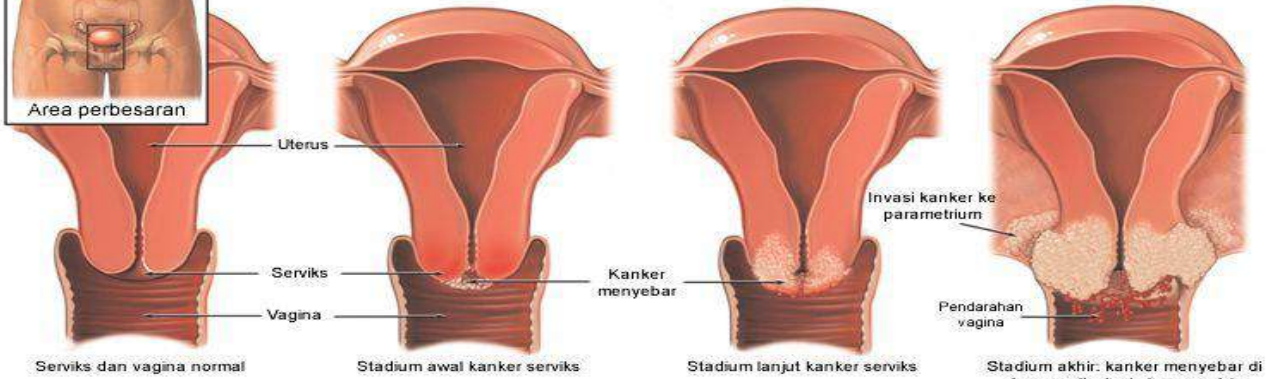
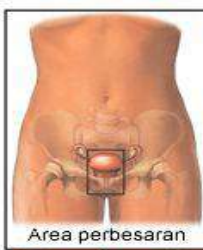
normal



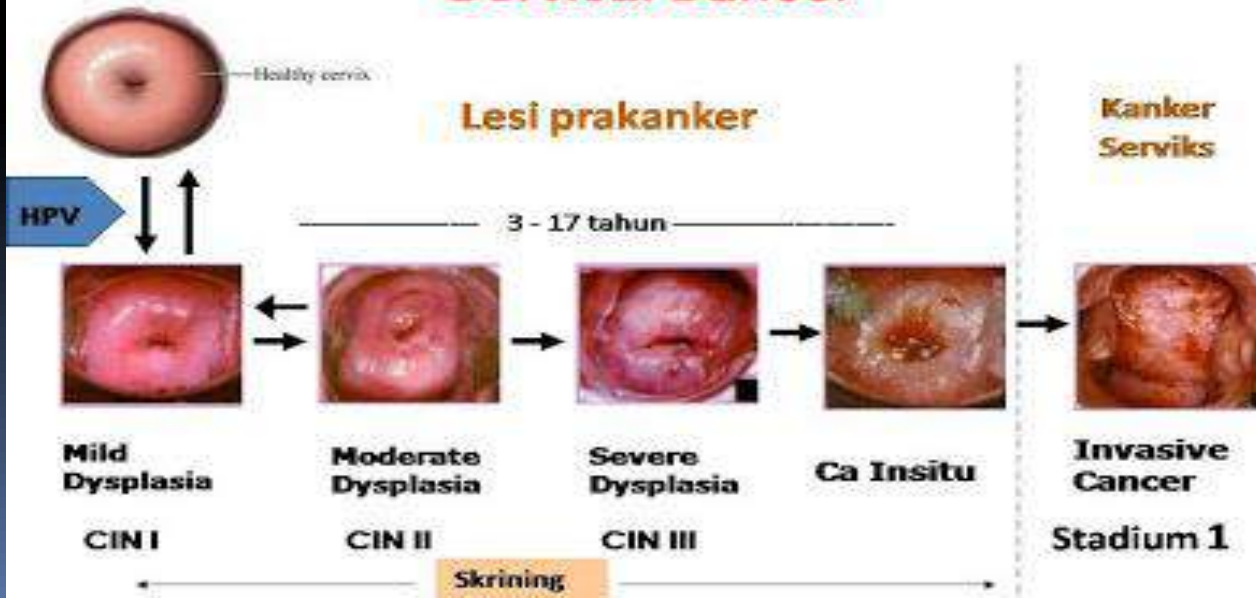dysplasia



cervical cancer

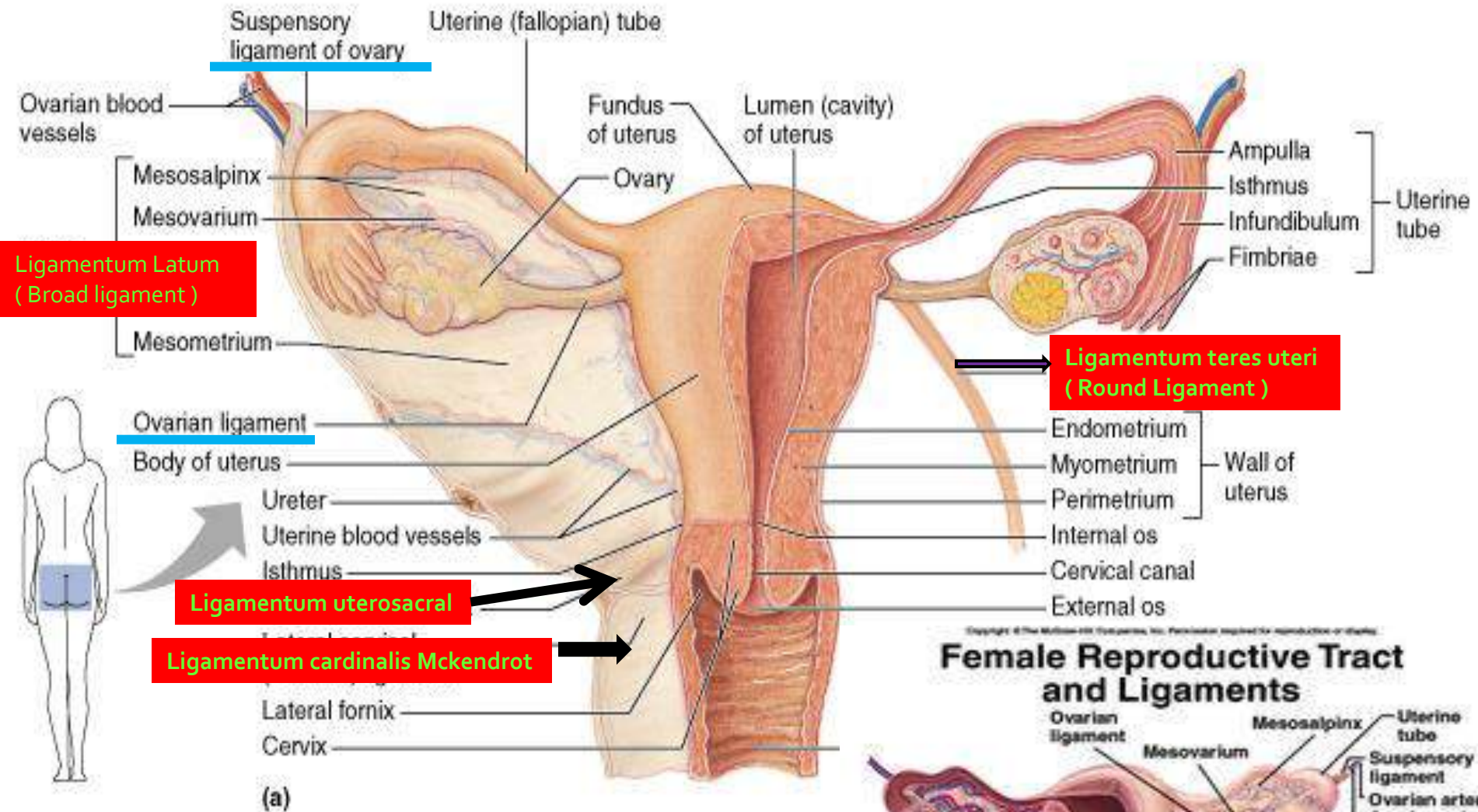


Natural History of Cervical Cancer



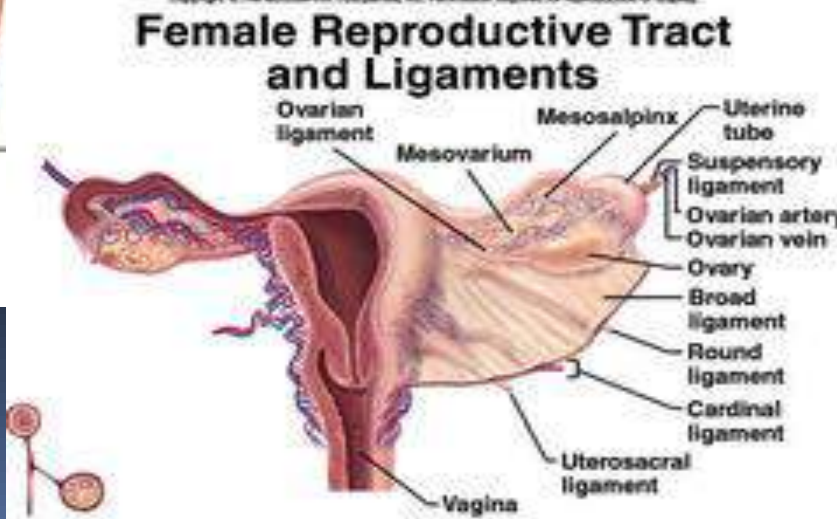
Uterus

- **Fundus**
- **Corpus**
- **Isthmus** → saat hamil menyatu dgn corpus →
→ Tembereng Rahim Bawah
- **Cervix Uteri**
 - Lanjutan isthmus dari OUI sampai vagina
 - **Canalis Cervicalis :**
 - Antara OUI & OUE, bermuara pada vagina
 - Lipatan vertikal → rugae palmatae → menutup canalis cervicalis
 - **Osteum Uteri Externum** → merapat pada Nullipara



Copyright © Pearson Education, Inc., publishing as Benjamin Cummings.

Ligament



1. Ligamentum Latum (Broad ligament)

- Dibentuk oleh 2 lapis peritoneum
- Bagian : plica rectouterina, mesovarium, mesosalpinx mesometrium , parametrium
- Isi :
 - tuba uterina, lig.ovarii, sebagian lig.teres
 - A. uterina, plexus saraf, sebagian ureter

2. Ligamentum teres uteri (Round Ligament)

- Batas uterus-tuba → canalis inguinalis → jaringan subkutan labia majora

3. Ligamentum cardinalis Mckendrot

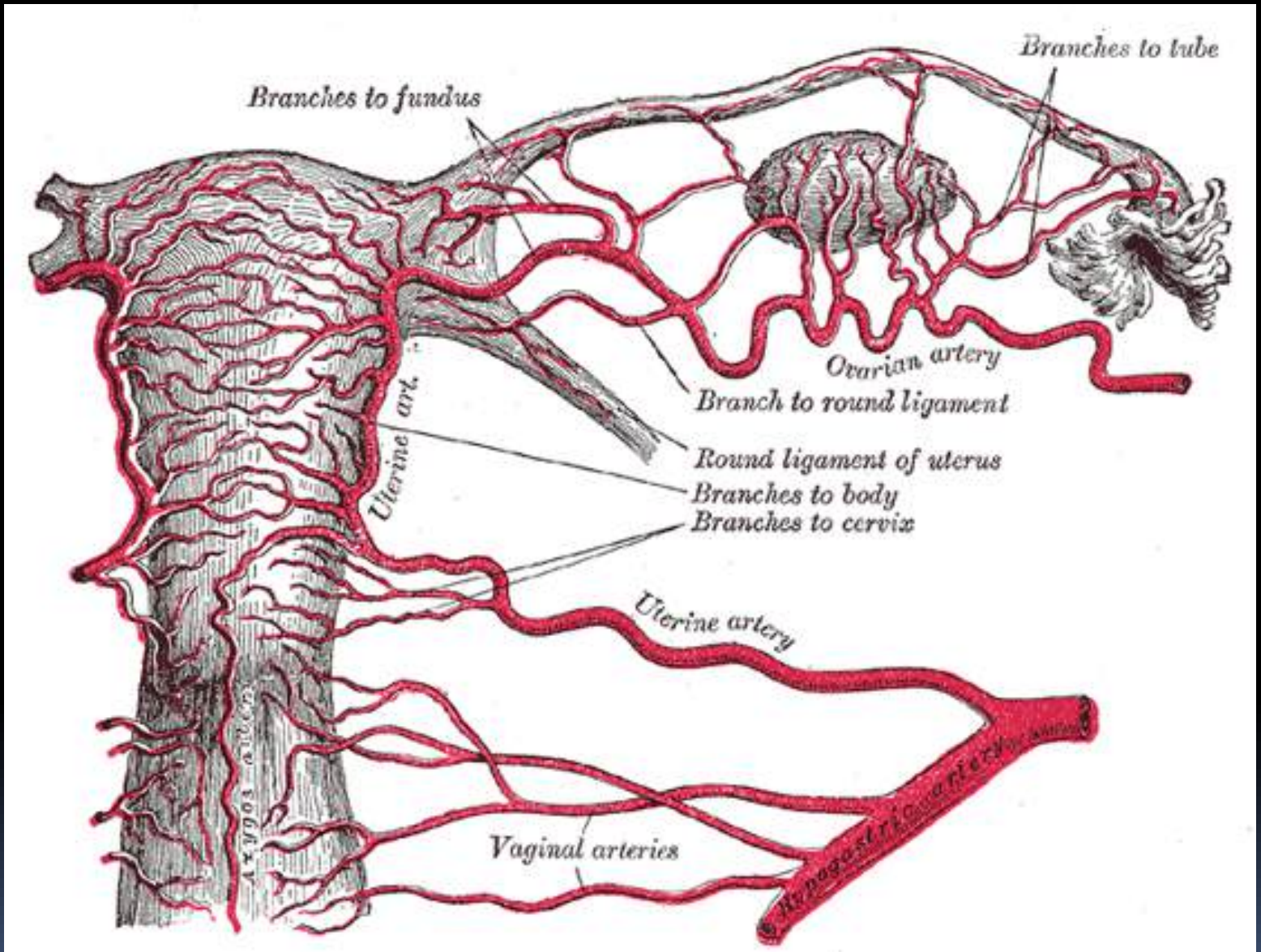
- Disebut juga : Ligamentum lateralis / transversalis cervicalis
- Dilewati A. Uterina

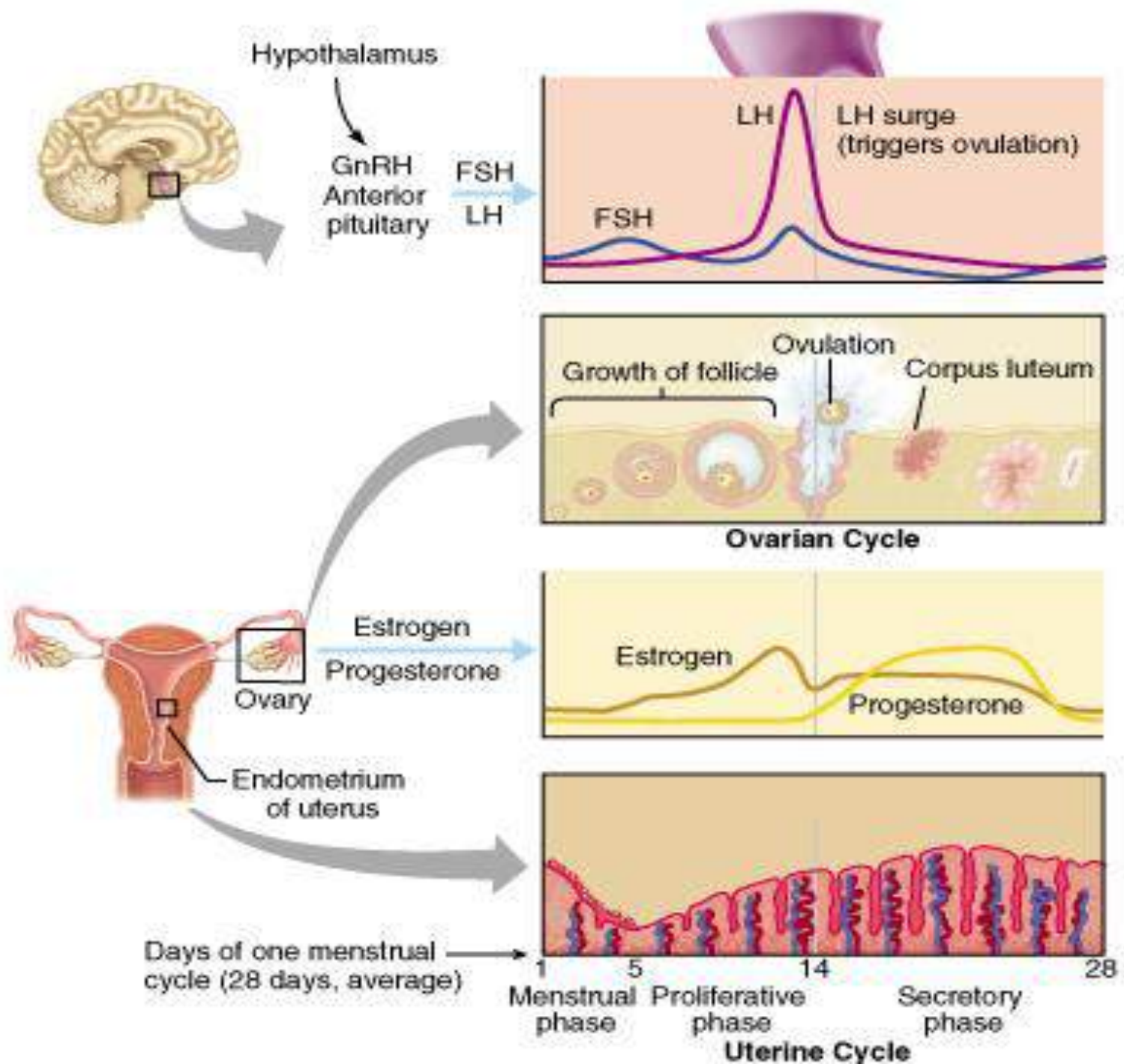
4. Ligamentum uterosacral

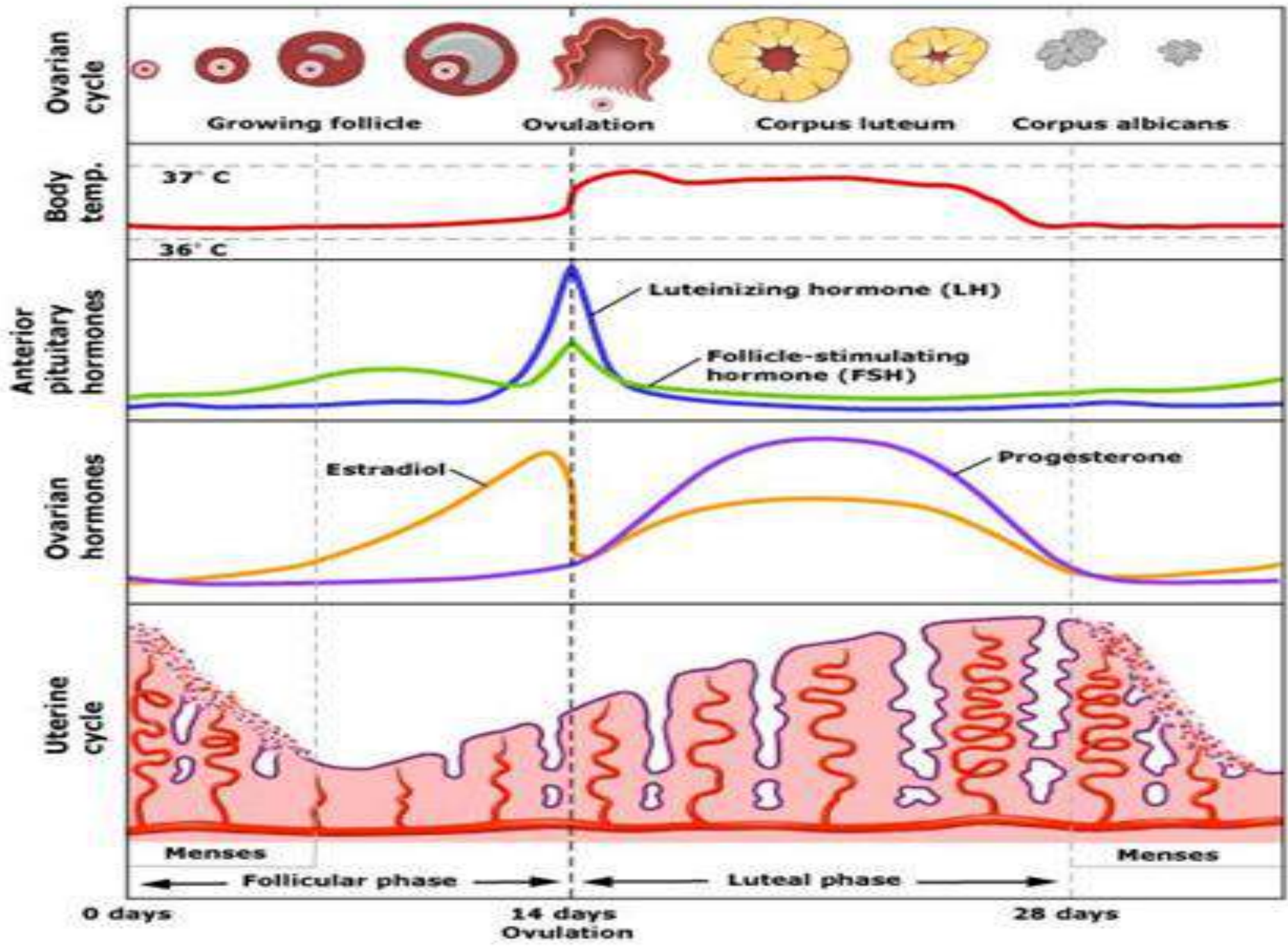
Uterus

Vaskularisasi, Inervasi, Limfe

- **Vaskularisasi :**
 - A. Uterina
- **Limfe :**
 - Fundus & bag.atas corpus uteri → **Lnn.lumbalis/aorticus**
 - Bag.bawah corpus uteri → **Lnn.iliaca externa**
 - Cervix uteri → **Lnn. Iliaca externa, interna, sacralis**
 - Masuknya tuba ke uterus → **Lnn. Inguinalis superficialis**
- **Inervasi :**
 - Plexus uterovaginalis

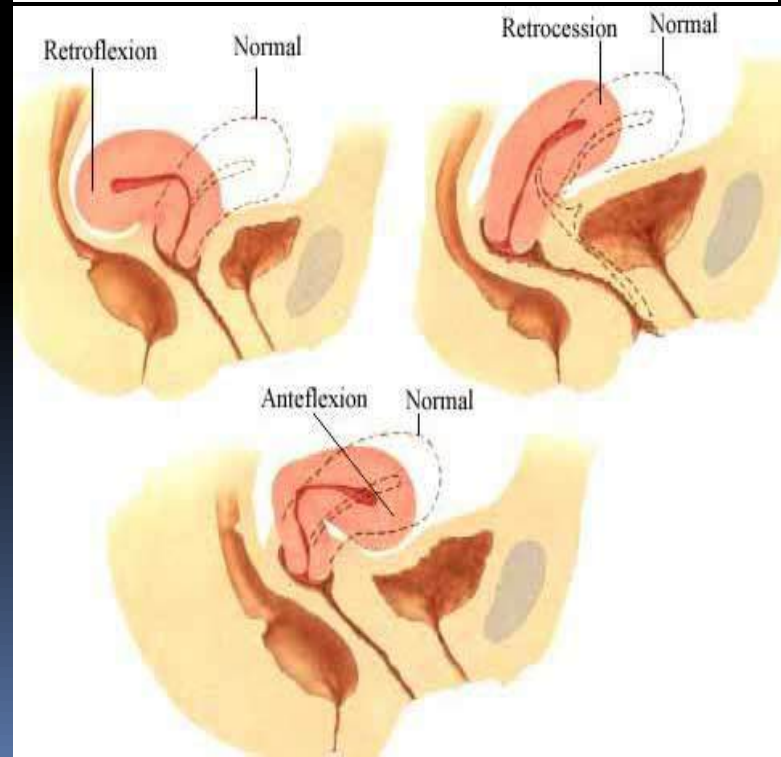
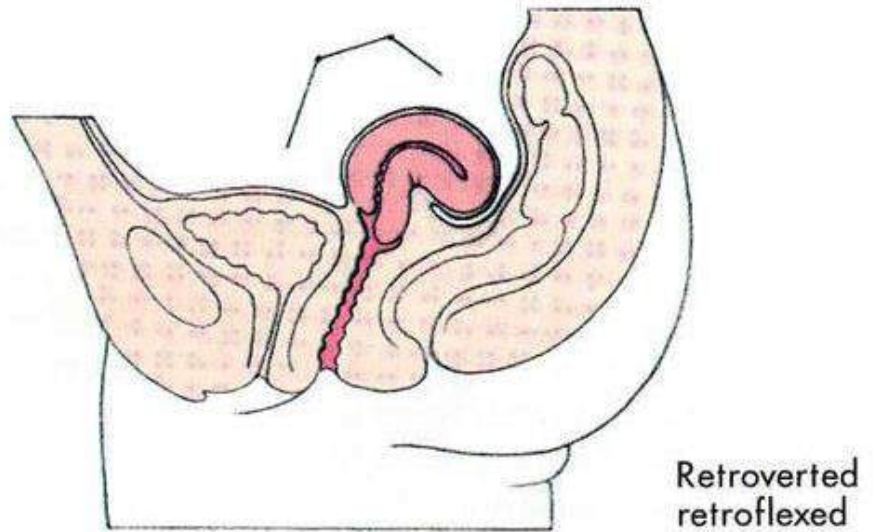
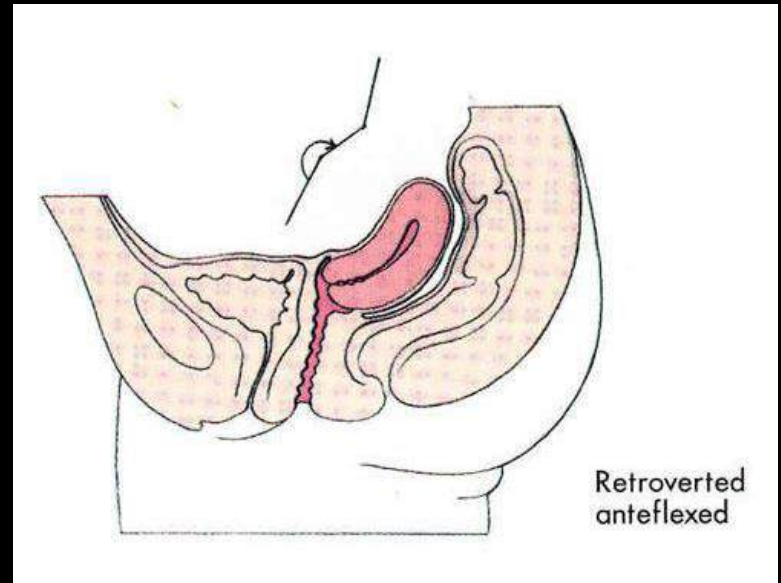
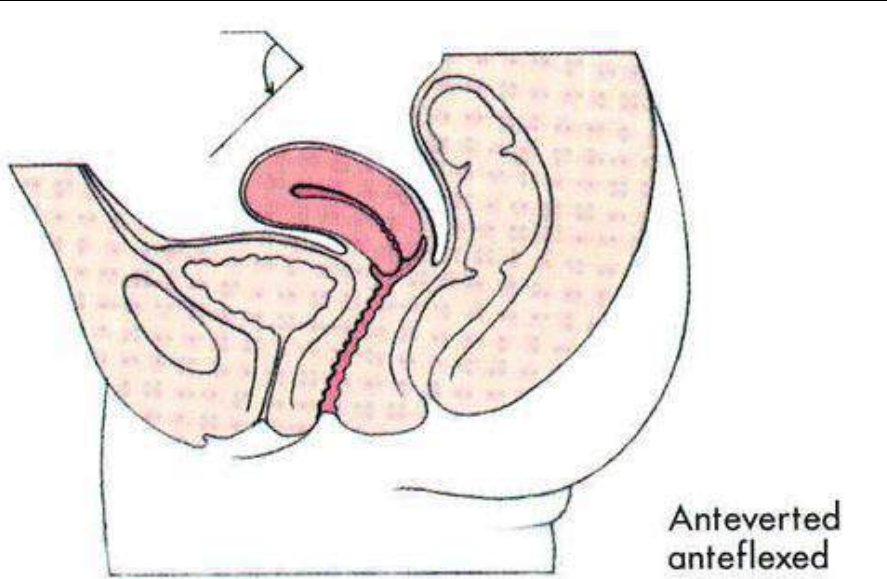




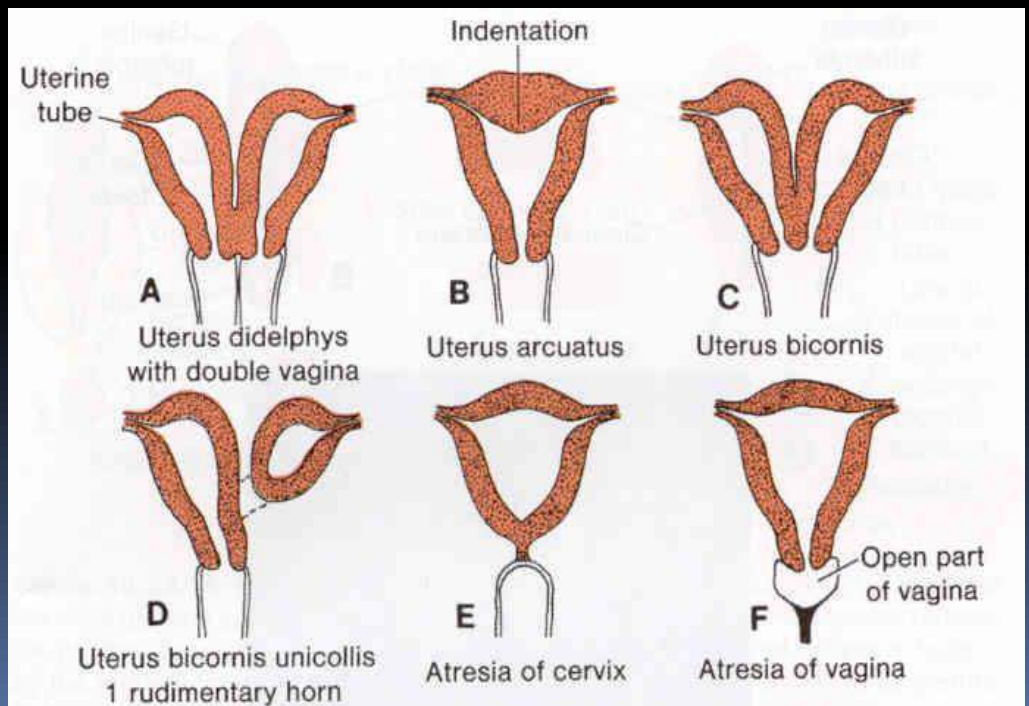
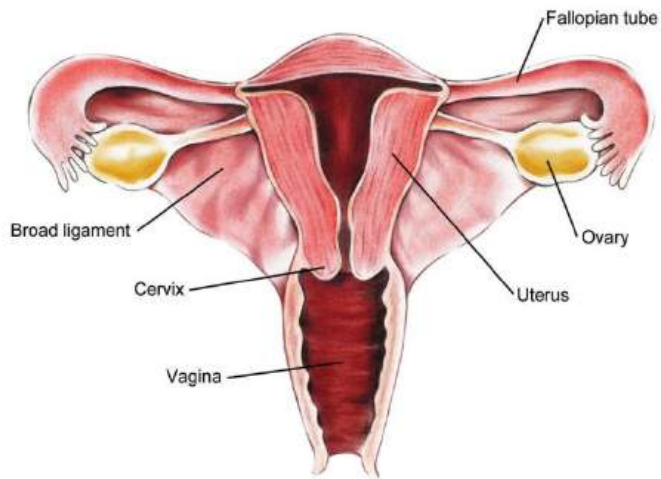
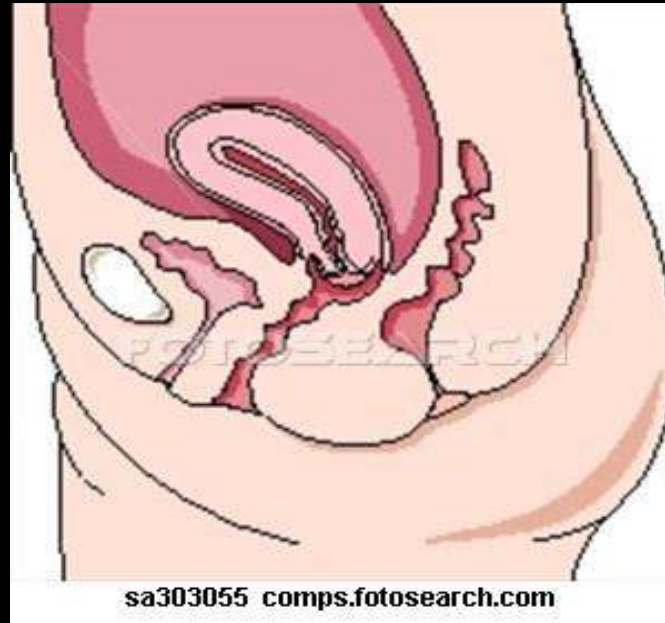

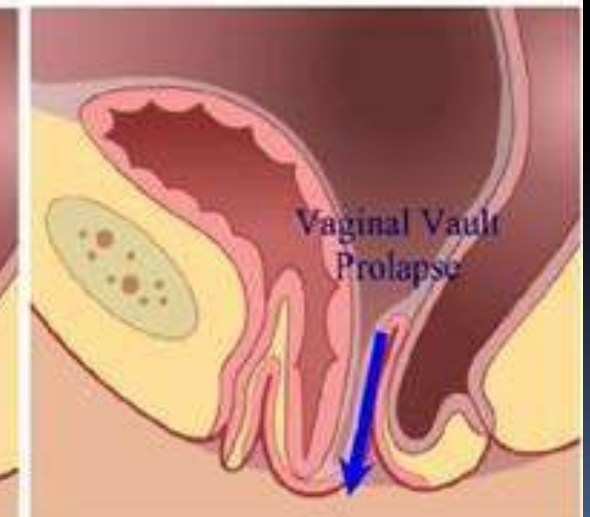
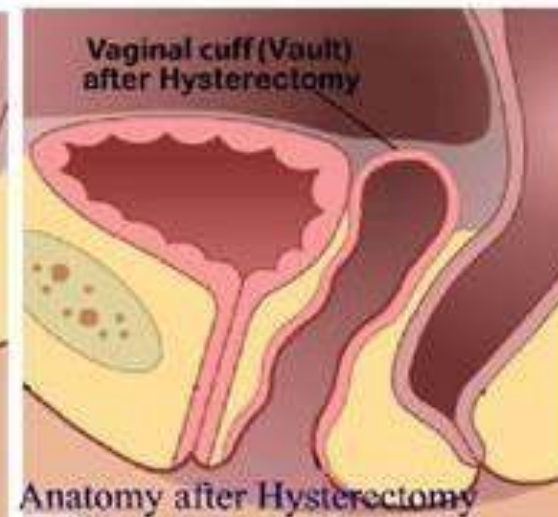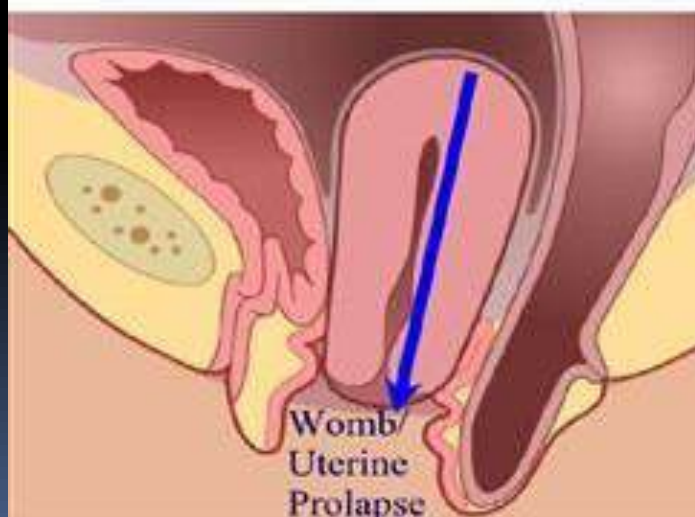
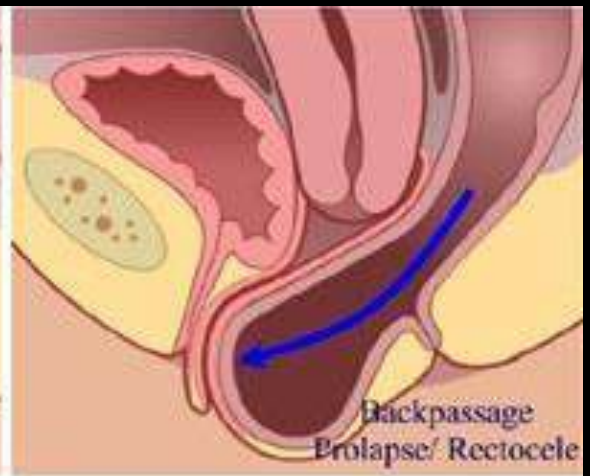
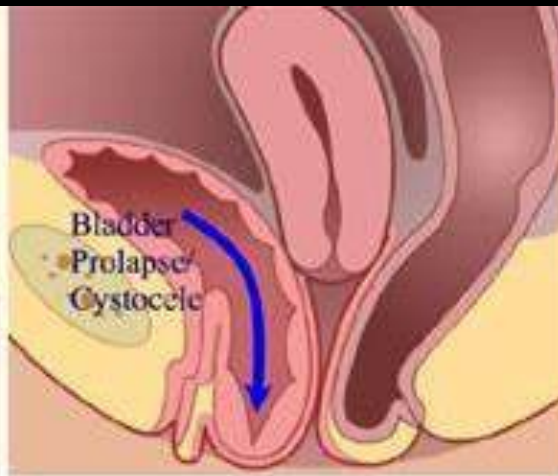
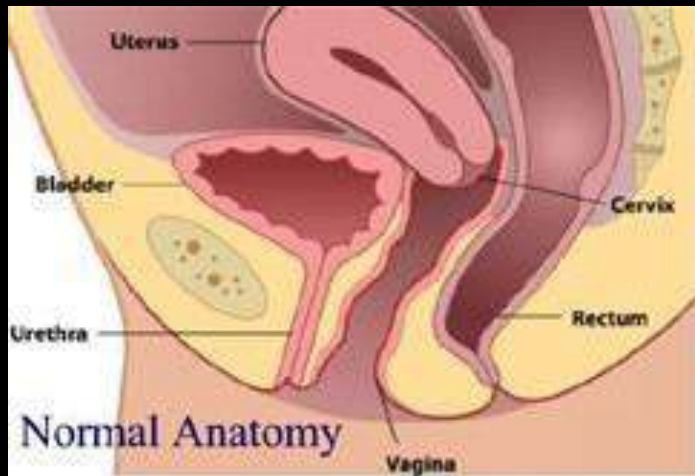
Siklus menstruasi	Ovulasi	Masa subur
22	Hari ke-8	Hari ke-7 sampai 9
23	Hari ke-9	Hari ke-8 sampai 10
24	Hari ke-10	hari ke-9 sampai 11
25	Hari ke-11	Hari ke-10 sampai 12
26	Hari ke-12	Hari ke-11 sampai 13
27	Hari ke-13	Hari ke-12 sampai 14
28	Hari ke-14	Hari ke-13 sampai 15
29	Hari ke-15	Hari ke-14 sampai 16
30	Hari ke-16	Hari ke-15 sampai 17
31	Hari ke-17	Hari ke-16 sampai 18
32	Hari ke-18	Hari ke-17 sampai 19
33	Hari ke-19	Hari ke-18 sampai 20
34	Hari ke-20	Hari ke-19 sampai 21
35	Hari ke-21	Hari ke-20 sampai 22
36	Hari ke-22	Hari ke-21 sampai 23

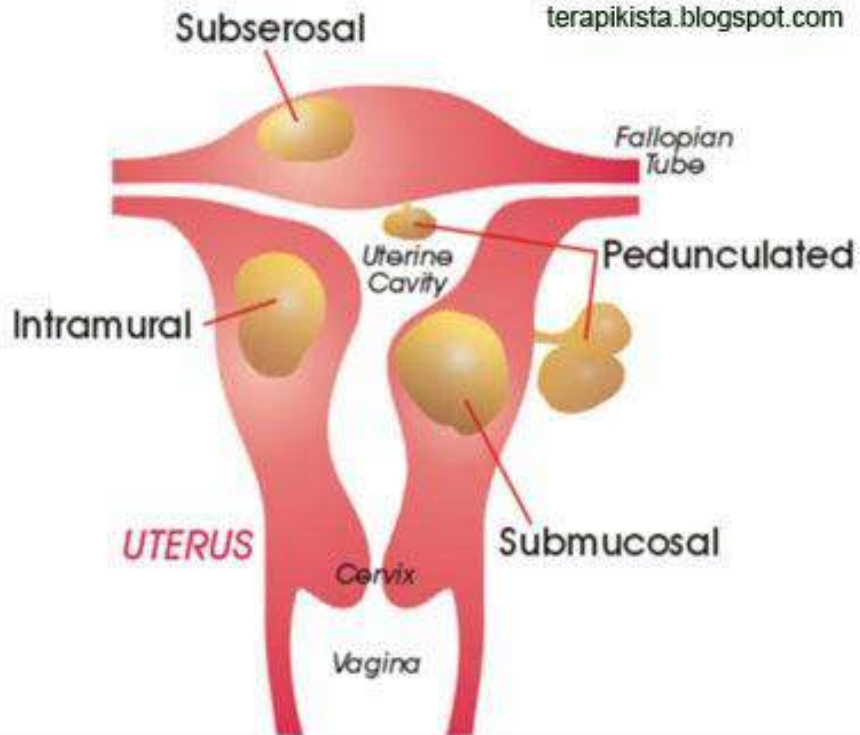
Uterus (Hystera)



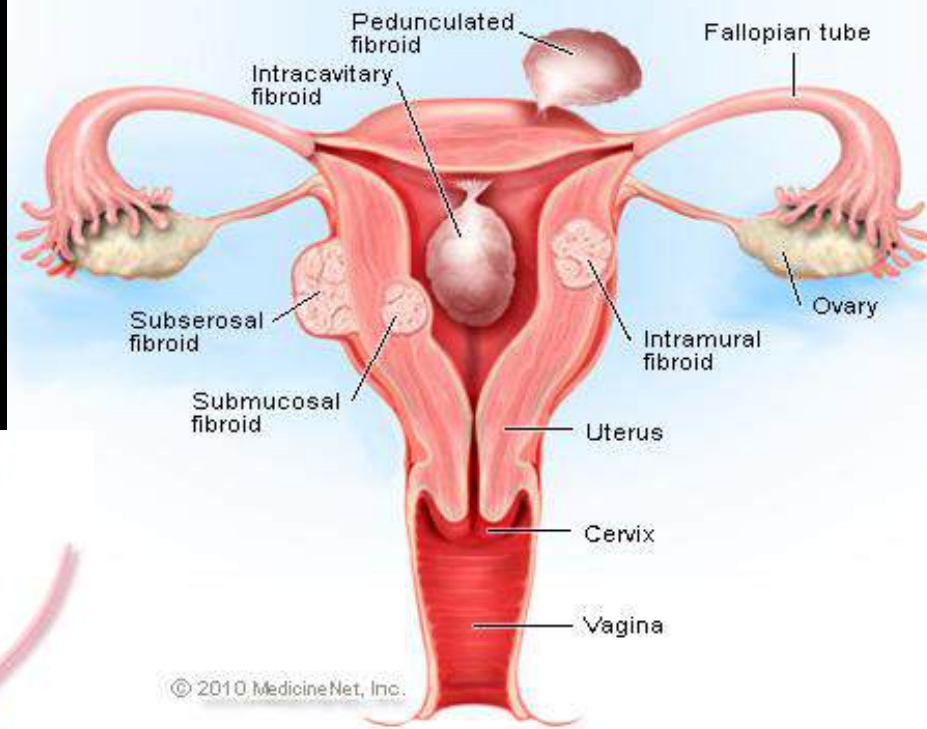
Uterus





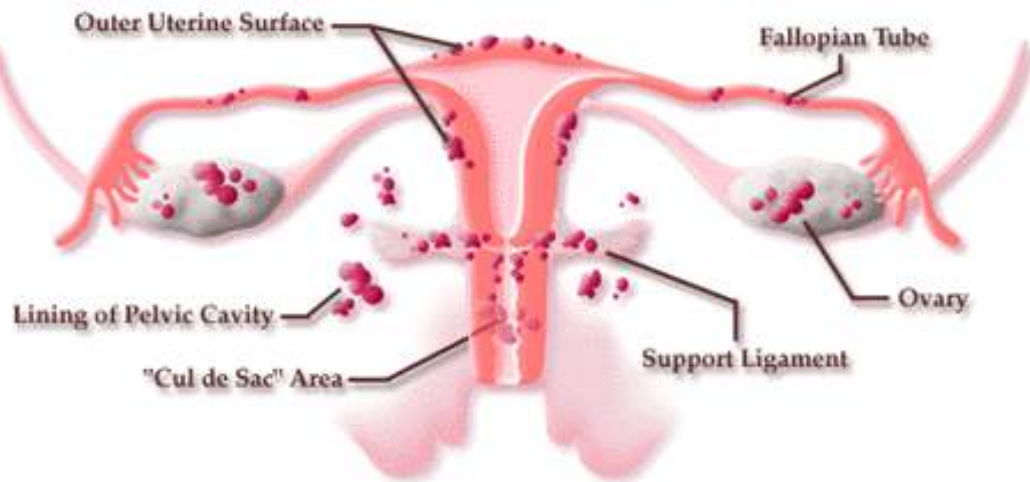


Uterine Fibroids



© 2010 MedicineNet, Inc.

COMMON LOCATIONS FOR ENDOMETRIOSIS IMPLANTS



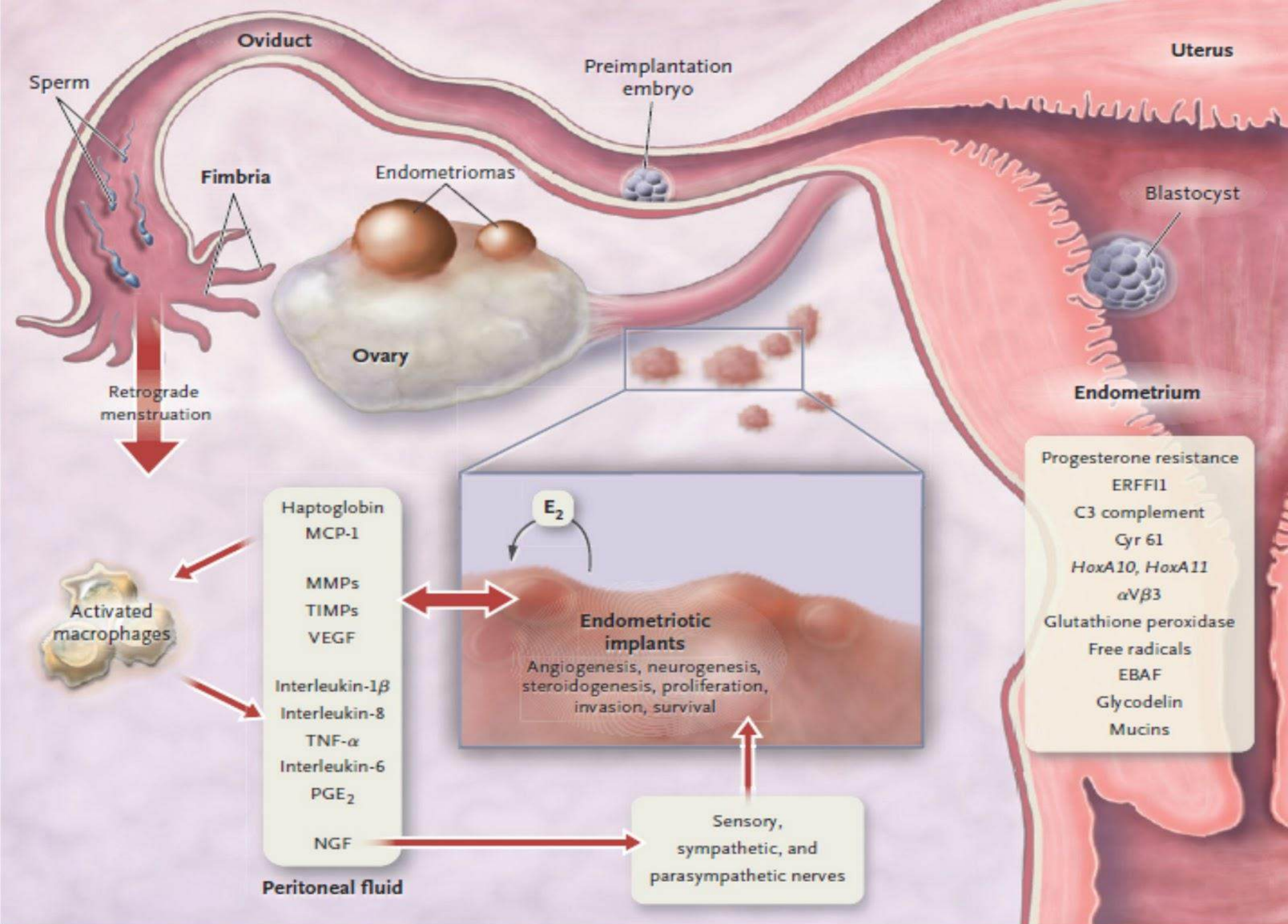
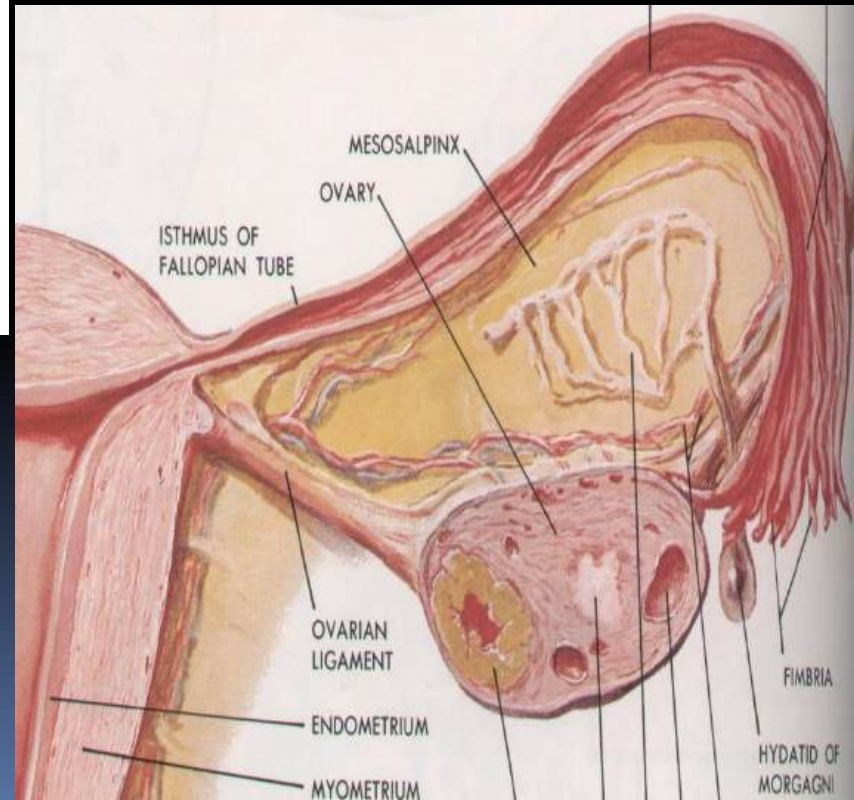
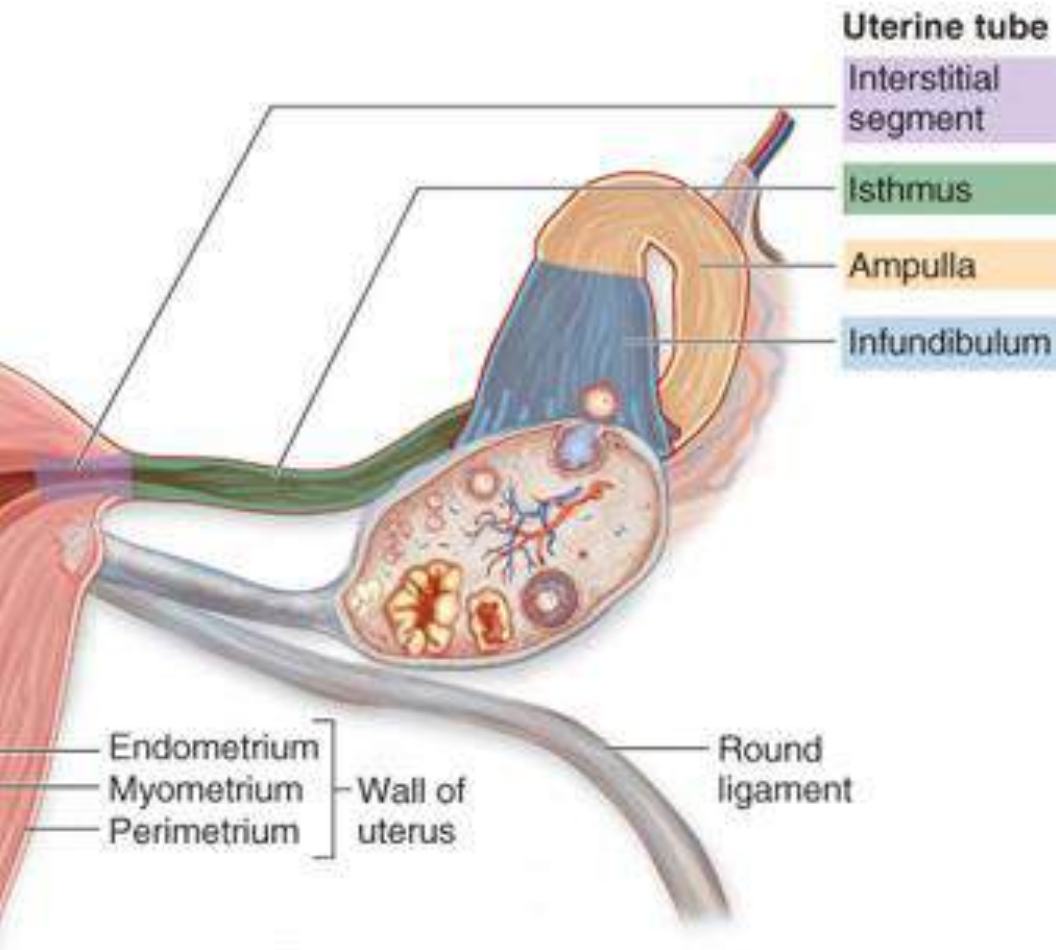


Figure 2. Pathophysiology of Pain and Infertility Associated with Endometriosis.

OVARIUM dan TUBA UTERINA

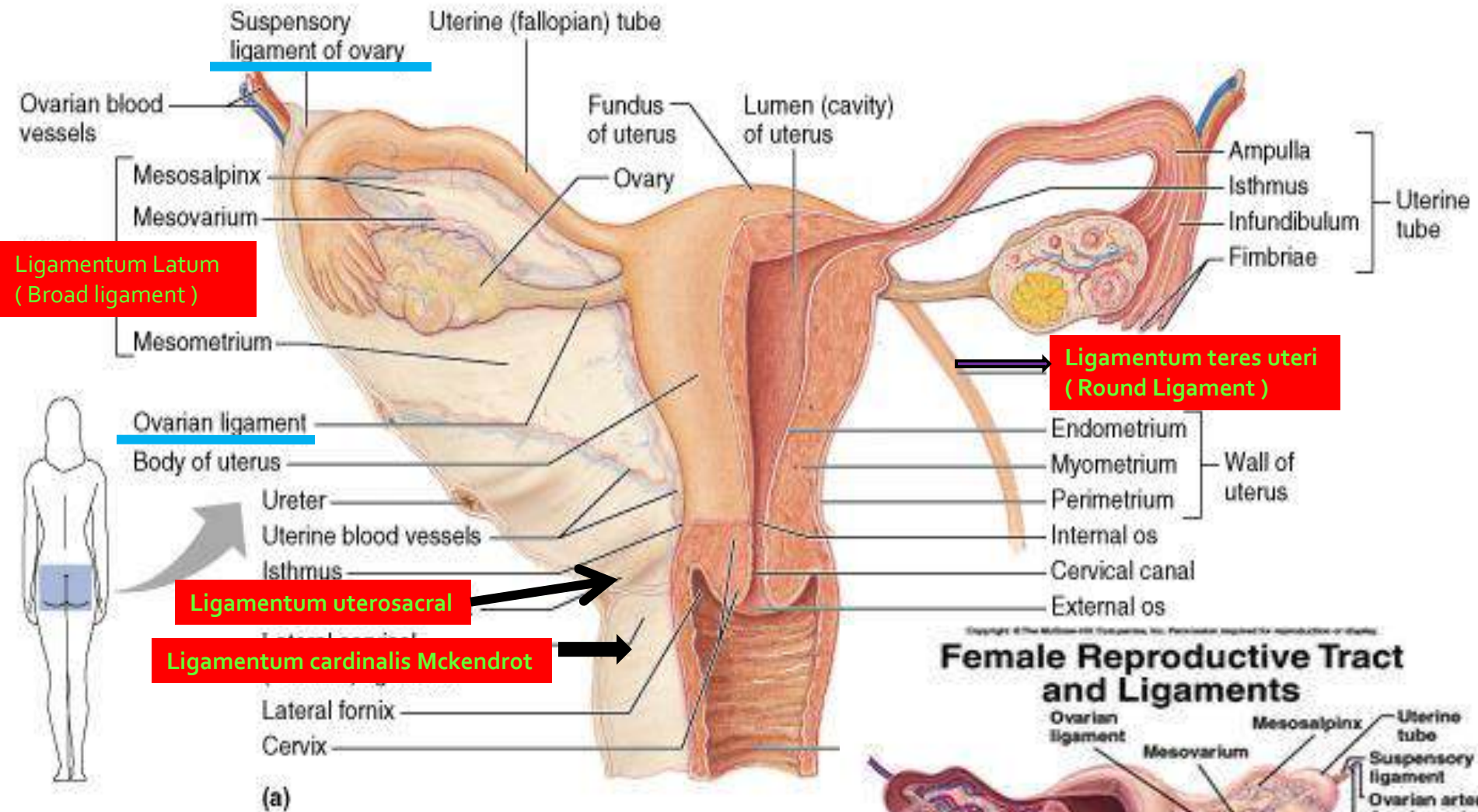


Fungsi :

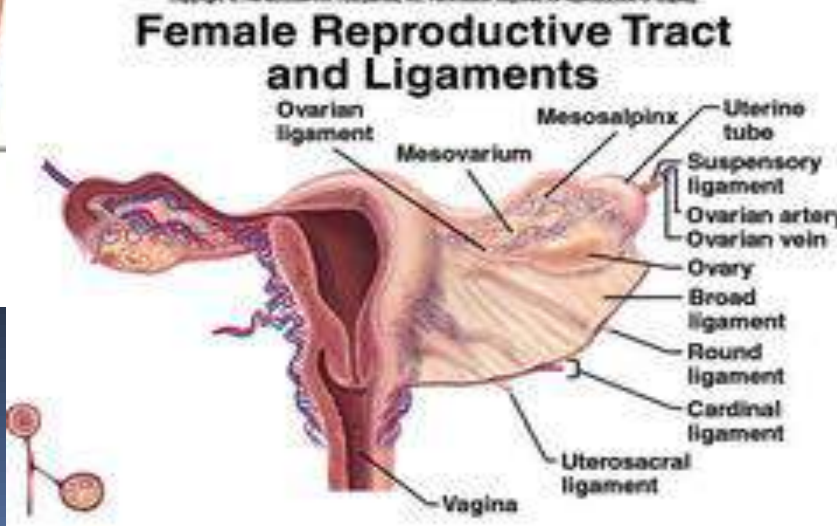
Penghasil Oocyte

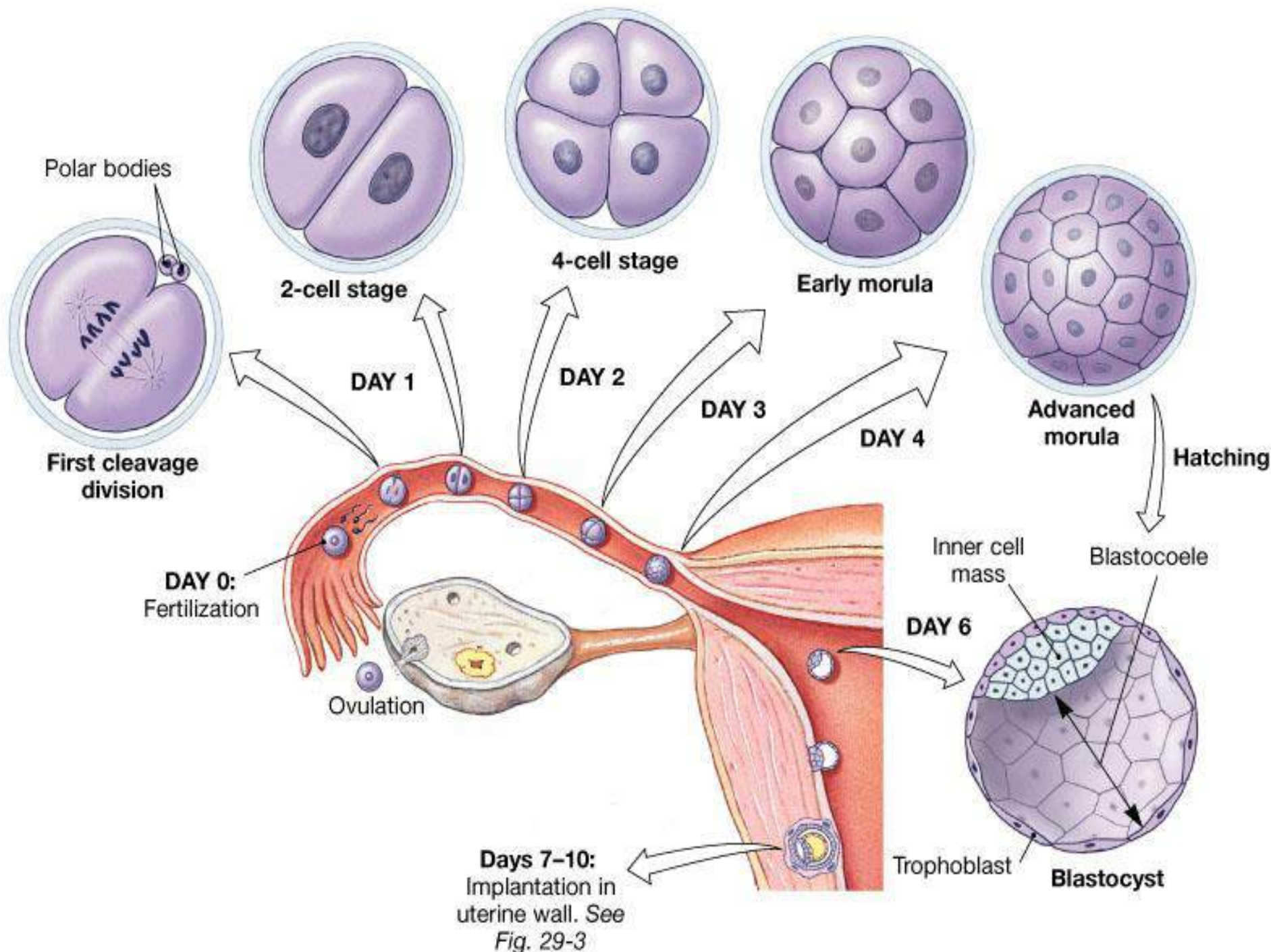
Kelenjar endokrin

Homolog dengan Testis

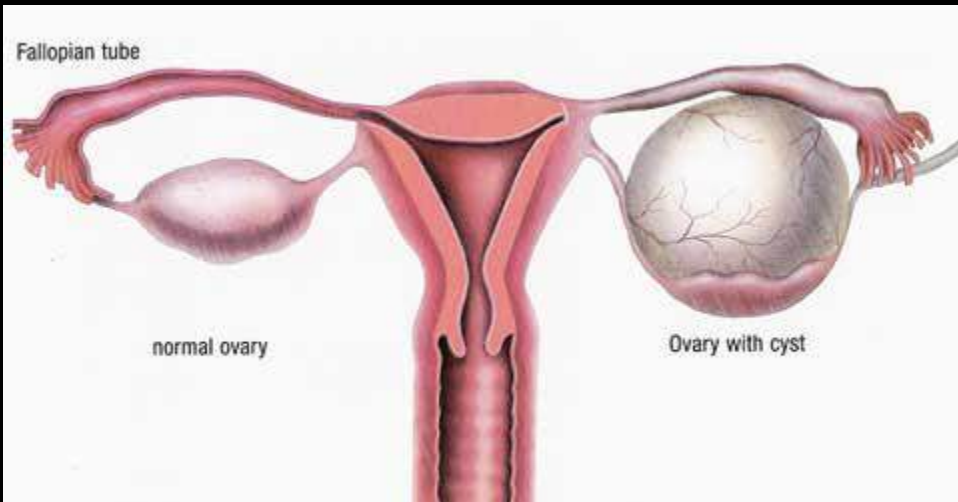


Copyright © Pearson Education, Inc., publishing as Benjamin Cummings.

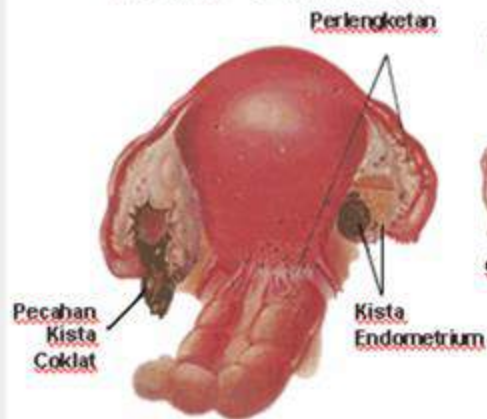




Days 7-10:
 Implantation in
 uterine wall. See
Fig. 29-3

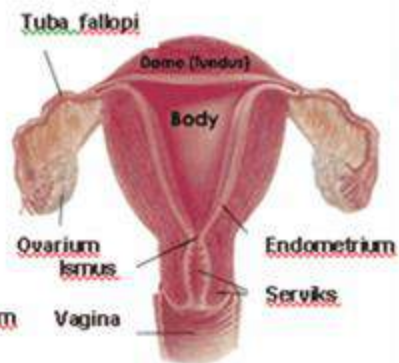


KISTA OVARIIUM

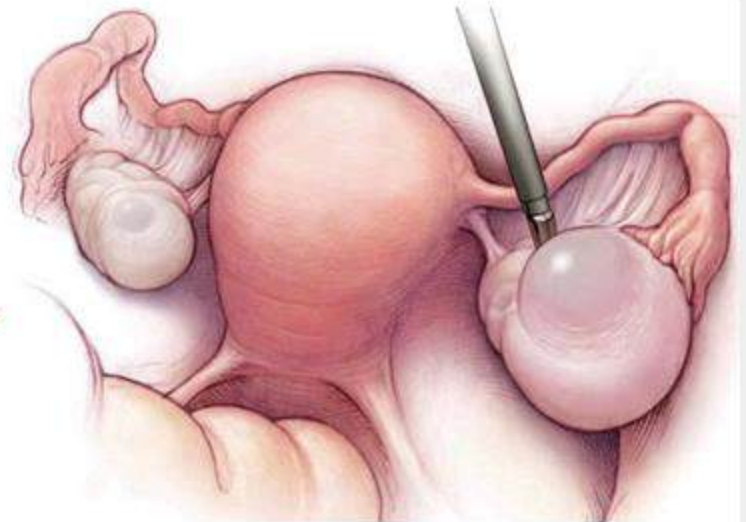

Gambar Kista Pecah

RAHIM NORMAL

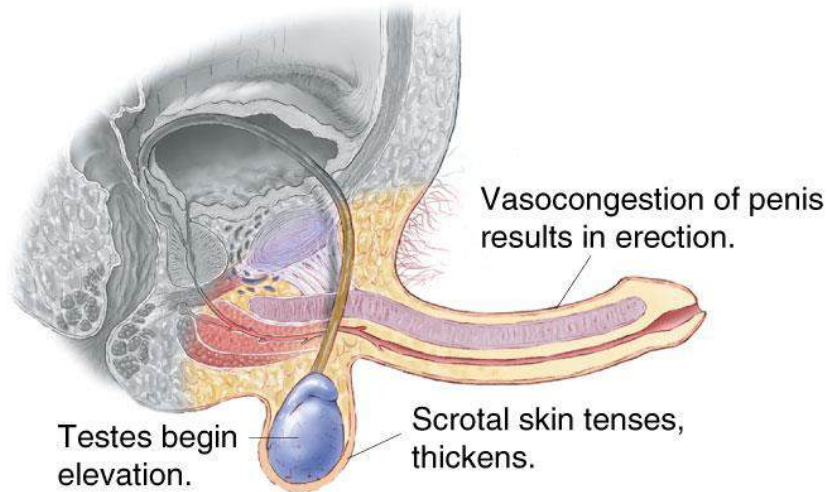


Rahim normal tampak depan

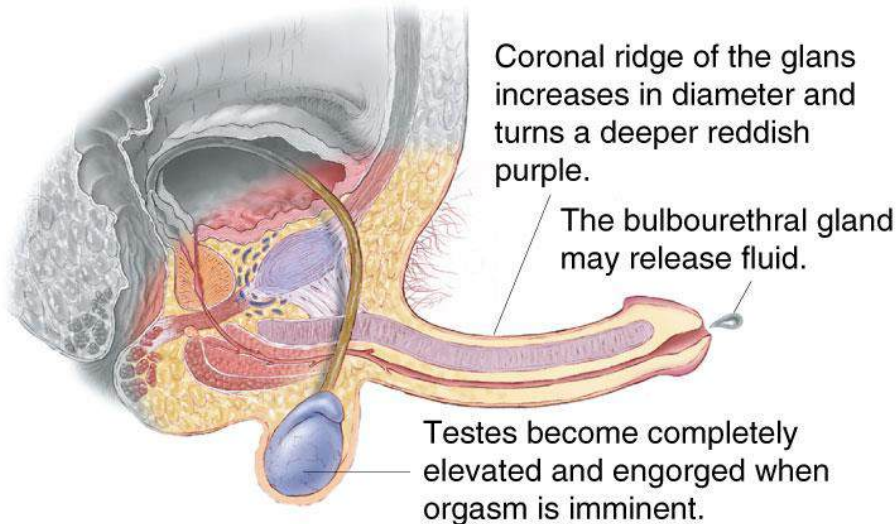


Comparison of Male and Female Sexual

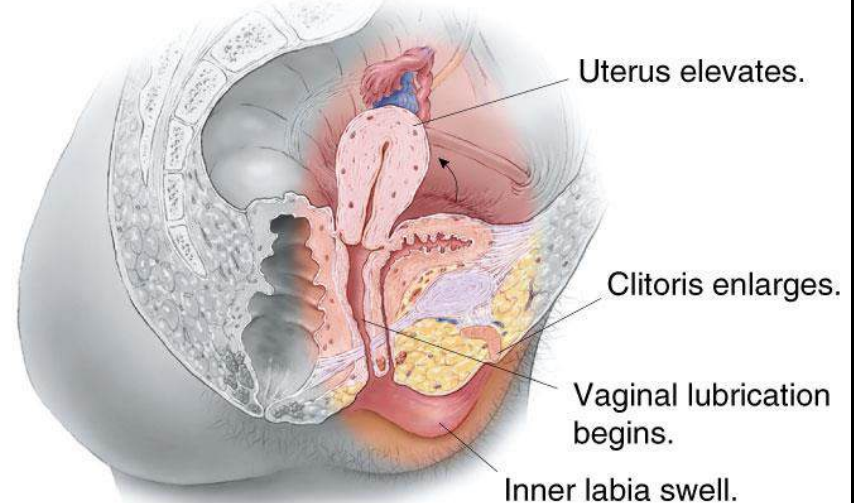
1. Excitement/Arousal Phase



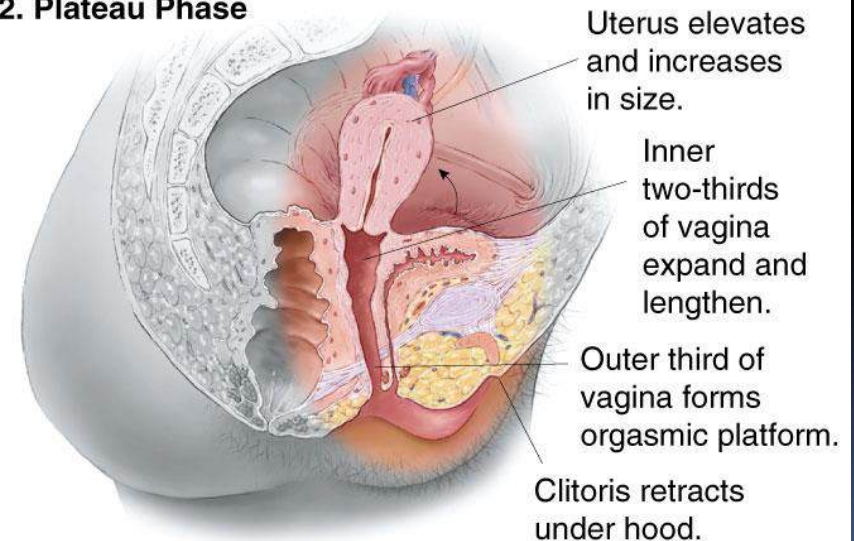
2. Plateau Phase



1. Excitement/Arousal Phase

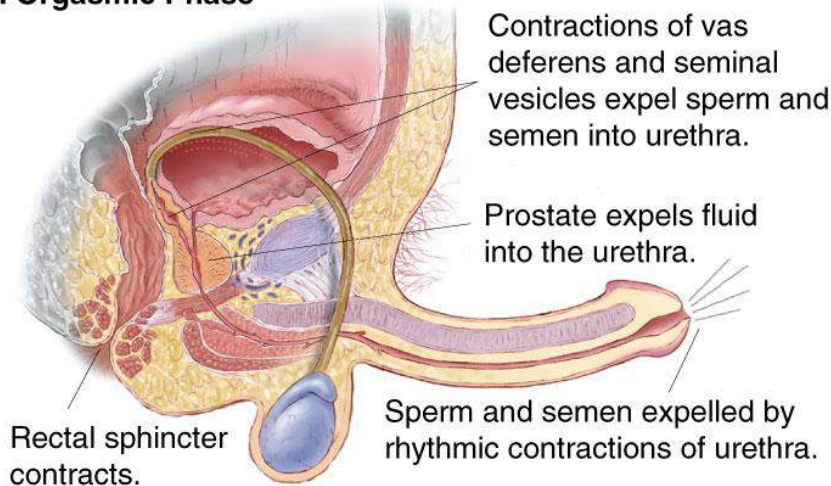


2. Plateau Phase

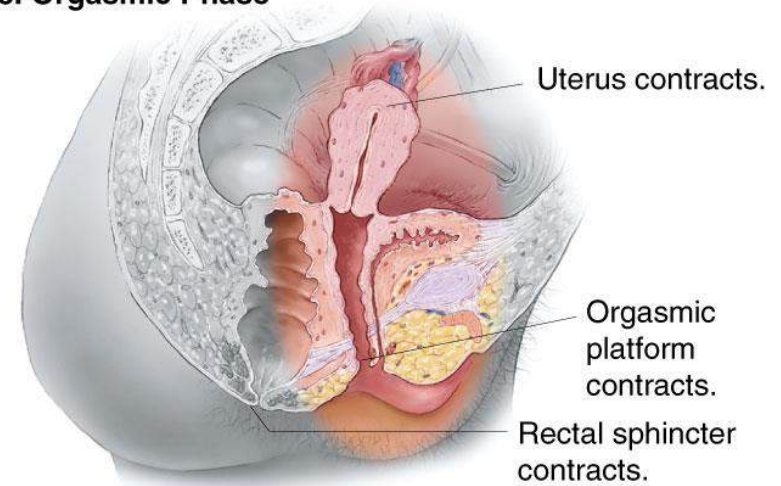


Comparison of Male and Female Sexual Response (cont.)

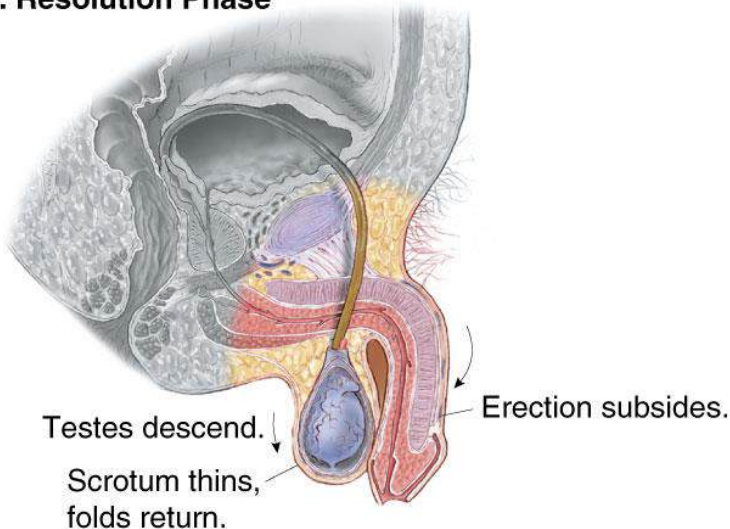
3. Orgasmic Phase



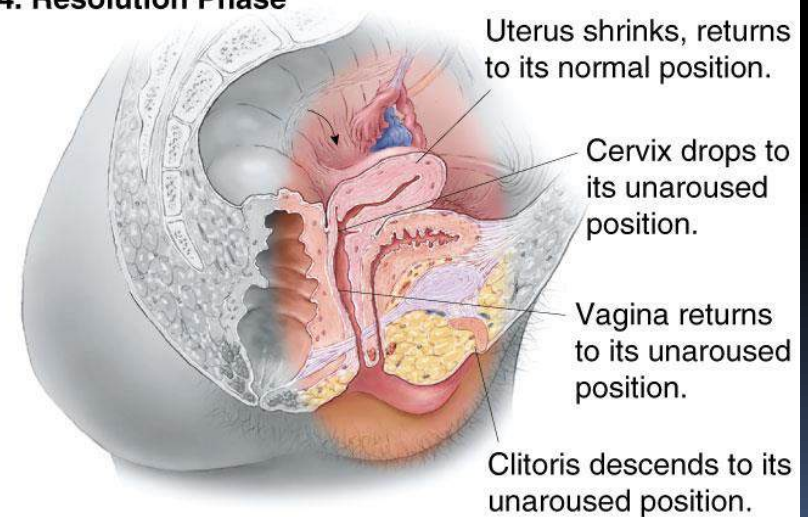
3. Orgasmic Phase



4. Resolution Phase



4. Resolution Phase



SYSTEMA UROPOETICA

DR THON

NS, MKES



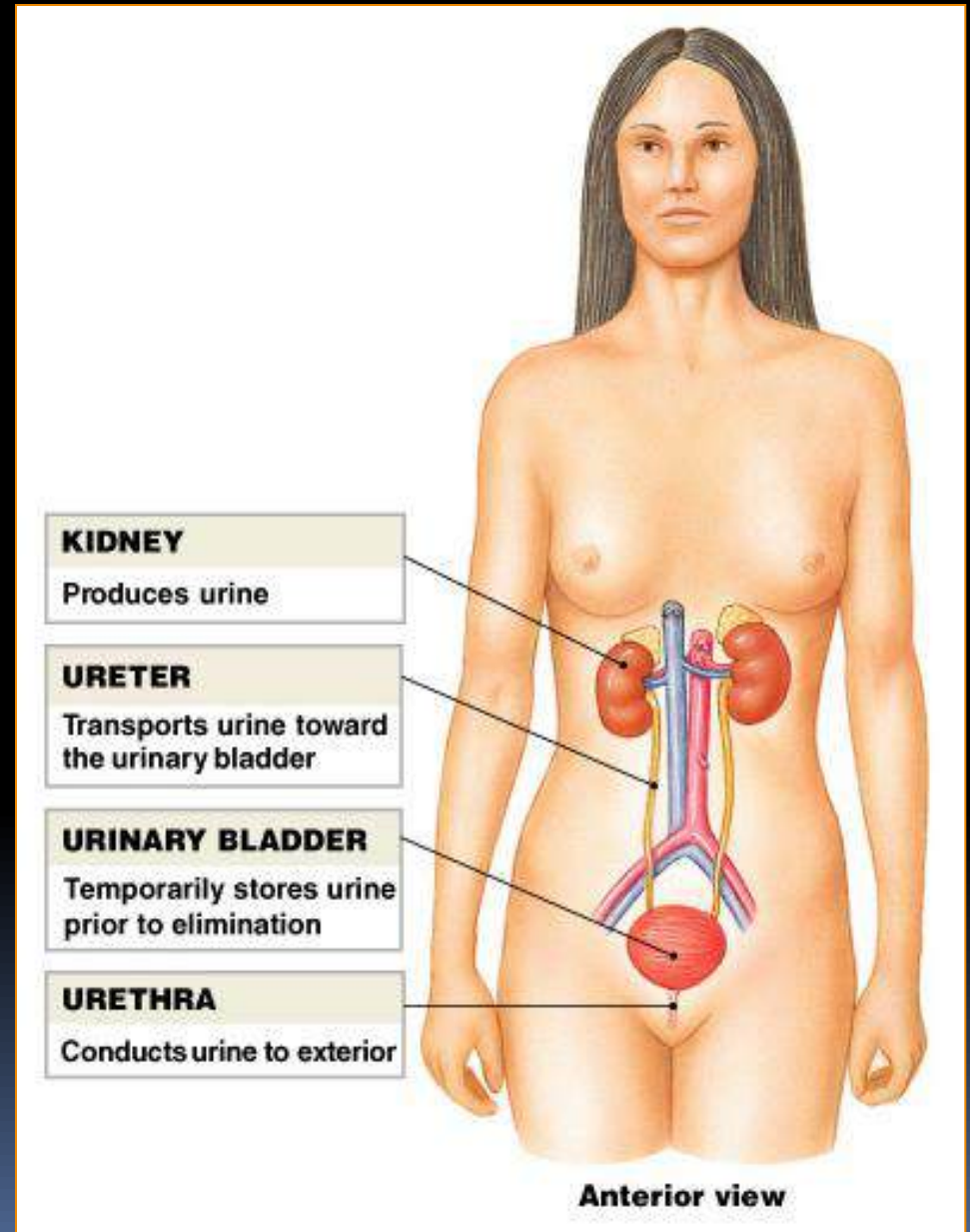
Organ Systema Urinarium

1. Ren

2. Ureter

3. Vesica urinaria.

4. Urethra.



Ren.

Bentuk. Seperti kacang kedele.

posisi :

regio abdomen posterior.

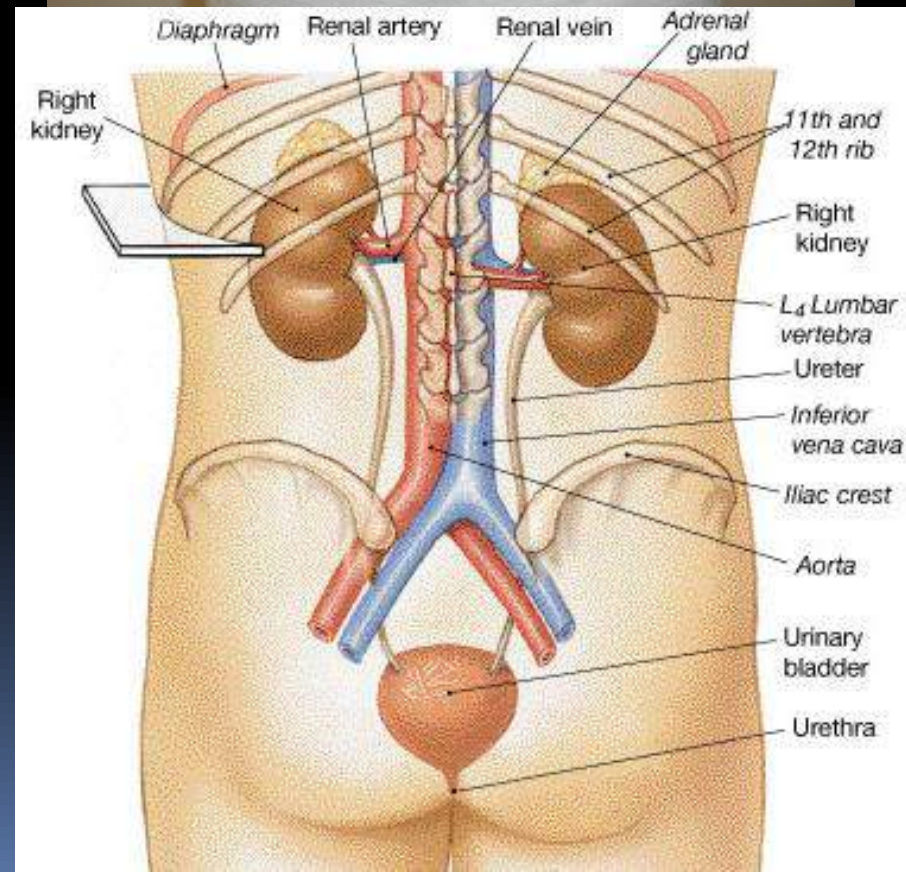
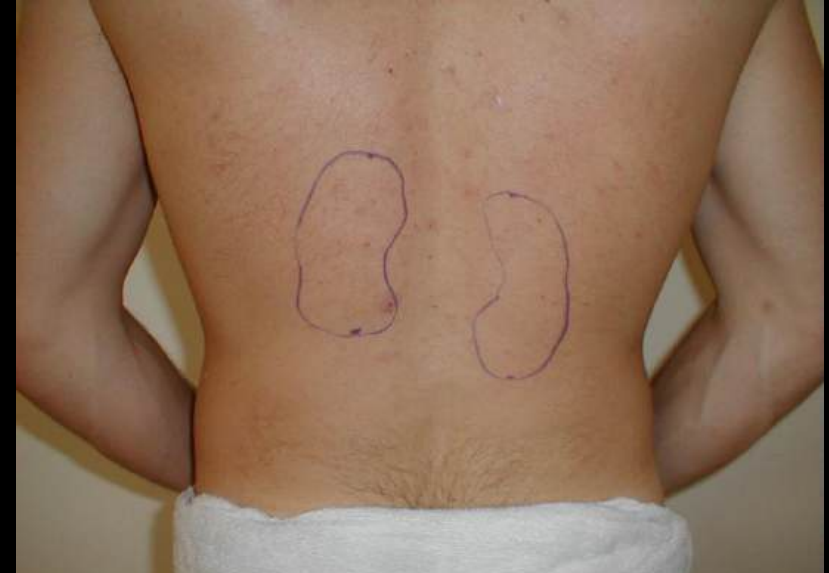sebelah lateral columna vertebra

retroperitoneal.

antara Vertebra T.XII – Vertebra L.III

Ren Dextra terletak lebih caudal dari

Ren sinistra.



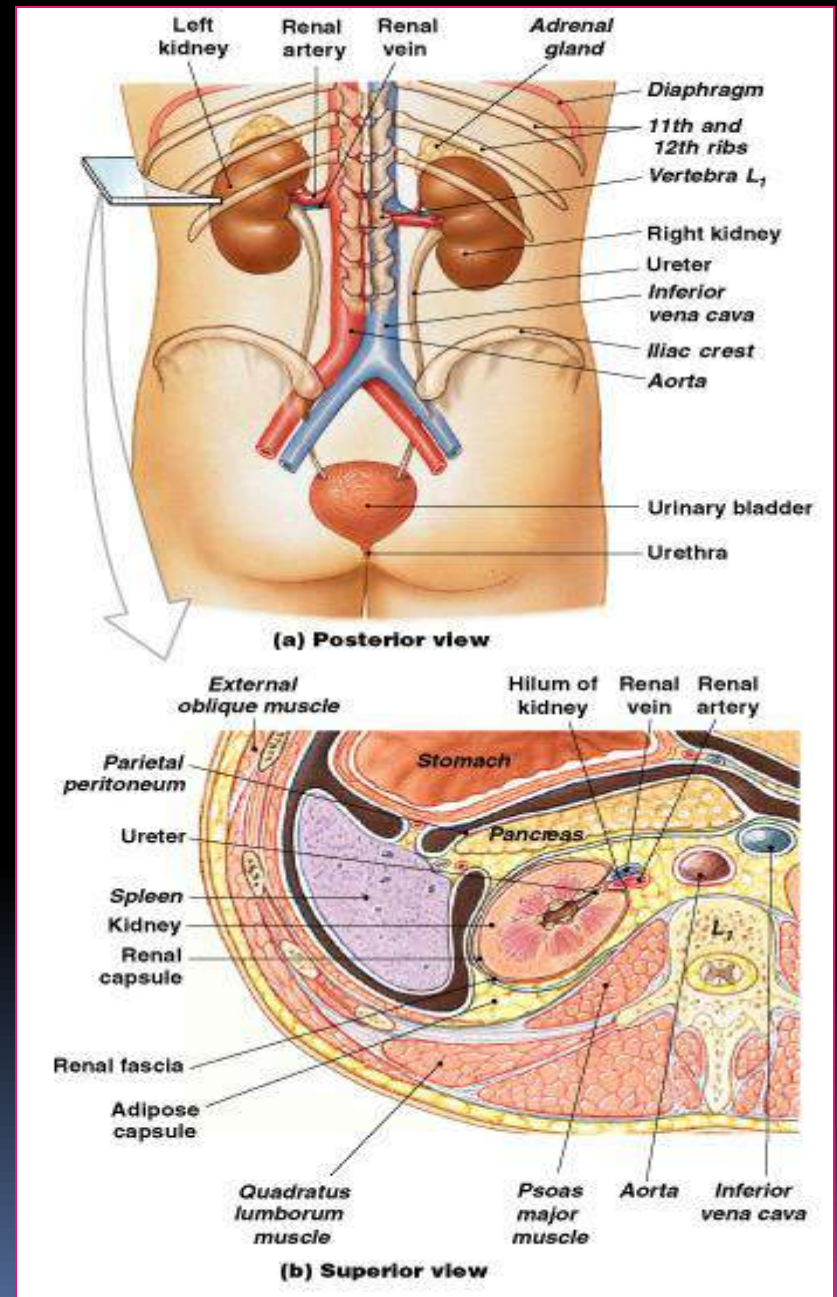
Holotomy Ren

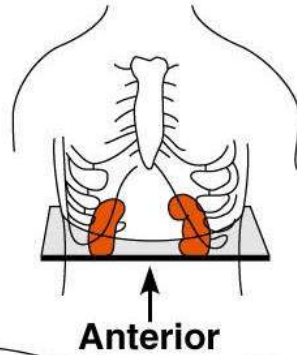
Terletak di regio posterior abdomen di sebelah kanan kiri columna vertebra (T_{12} – L_3):

- Ren kanan sedikit lebih rendah dari ren kiri oleh karena adanya hepar di sebelah kanan cavum abdomen
- Margo superior di tutupi glandula supra renalis.

Pembungkus ren:

1. capsula renal
2. capsule adiposa
3. fascia renalis.





Right side

Left side

Inferior
vena cava

Aorta

Peritoneum

*Peritoneal
cavity*

Renal
vein

Renal
artery

Anterior
renal fascia
Kidney

Perirenal
fat capsule

Fibrous
capsule

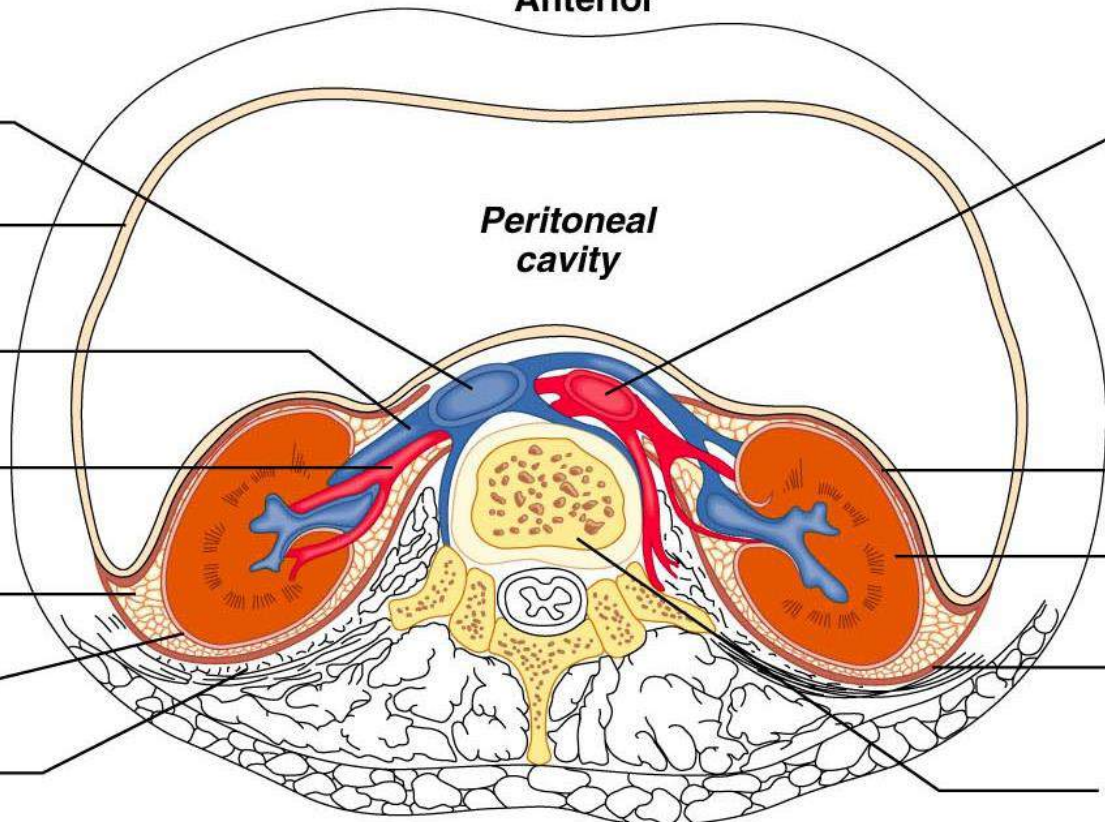
Posterior
renal fascia

Pararenal fat

Body of vertebra L₂


(a)

Posterior





Fungsi Systema Urinarius

1. Excreci:
 - Memindahkan sisa metabolisme dari cairan tubuh
 2. Eliminasi:
 - Membuang sisa metabolisme dari tubuh
 3. Mengatur homeostasis:
 - Mengatur volume plasma dan konsentrasi larutan darah
- 

Struktur Ren.

1. Hilus renalis

2. Cortex renalis

3. Medulla renalis

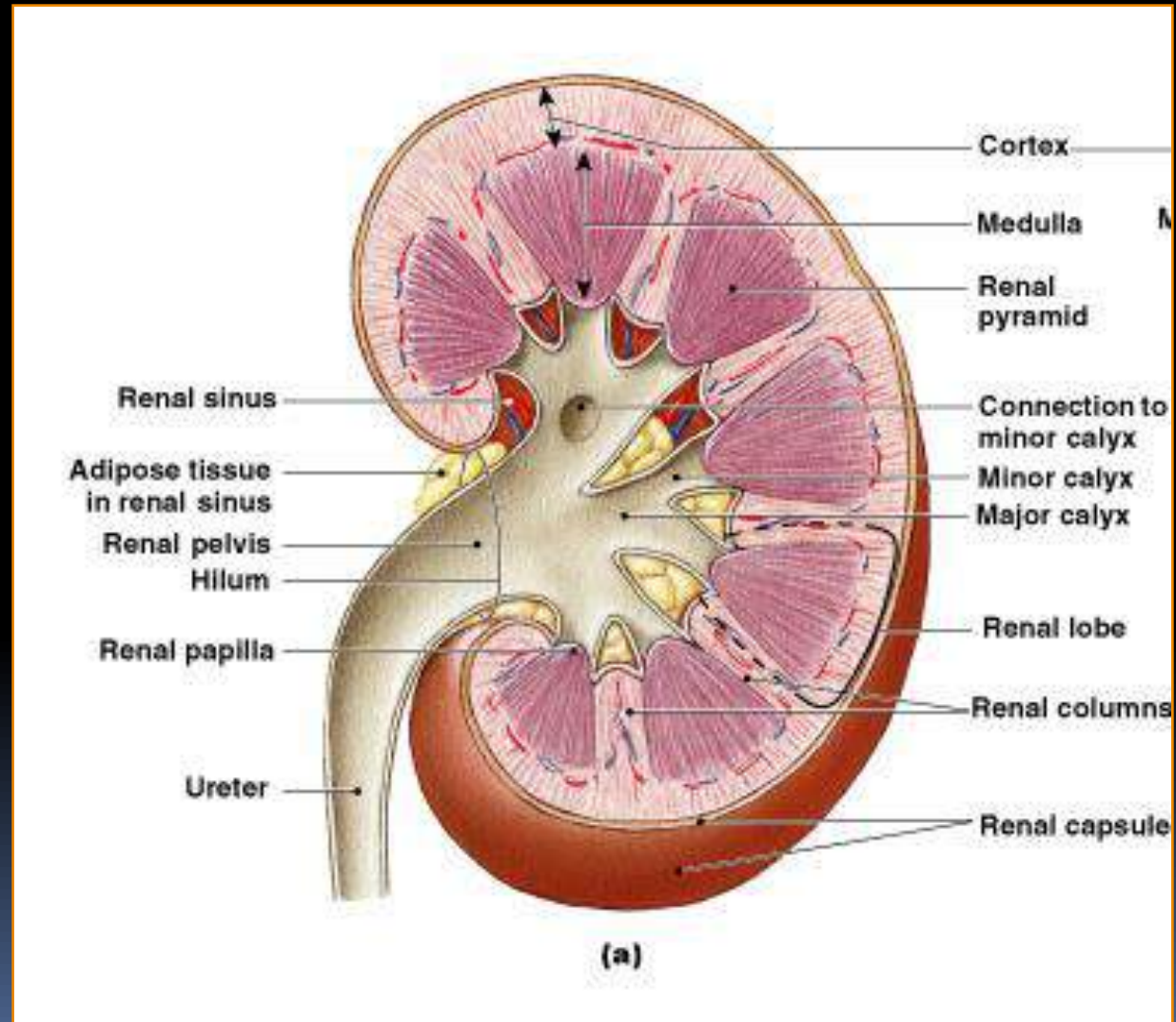
4. Columna renalis

5. Pyramida renalis

6. Papilla renalis

7. Calyx minor

8. Calyx major



Gross Anatomy

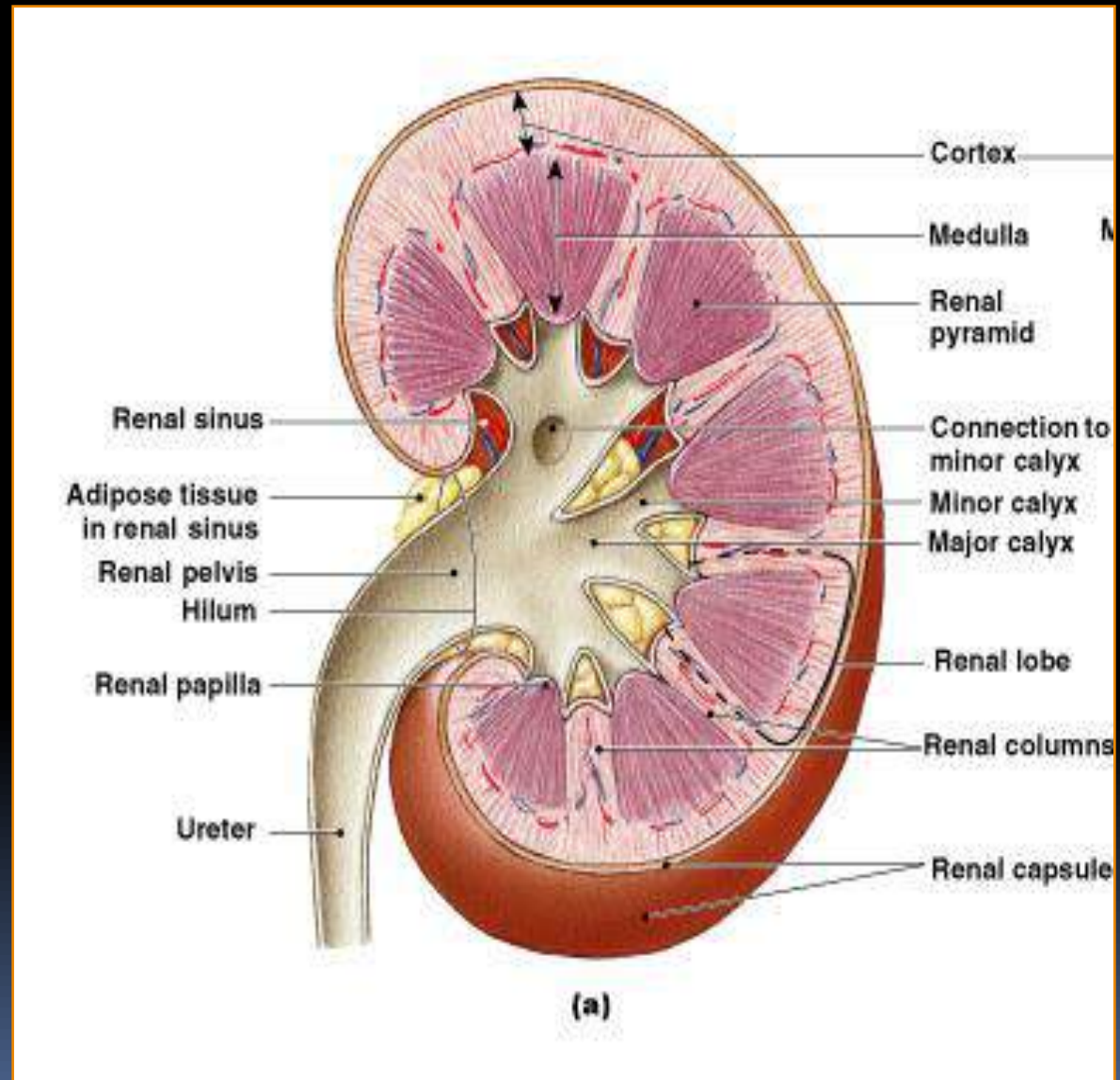
Cortex Renal

Bagian superficial dari ren yang melekat dengan capsula renalis

- Warna merah coklat dan granuler

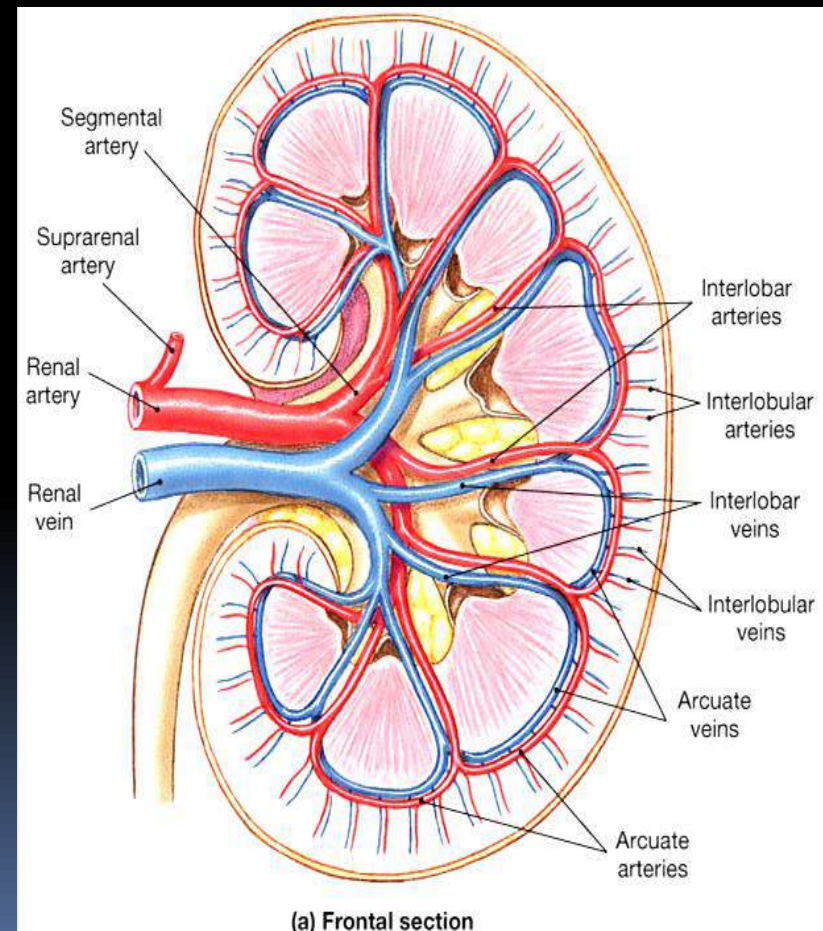
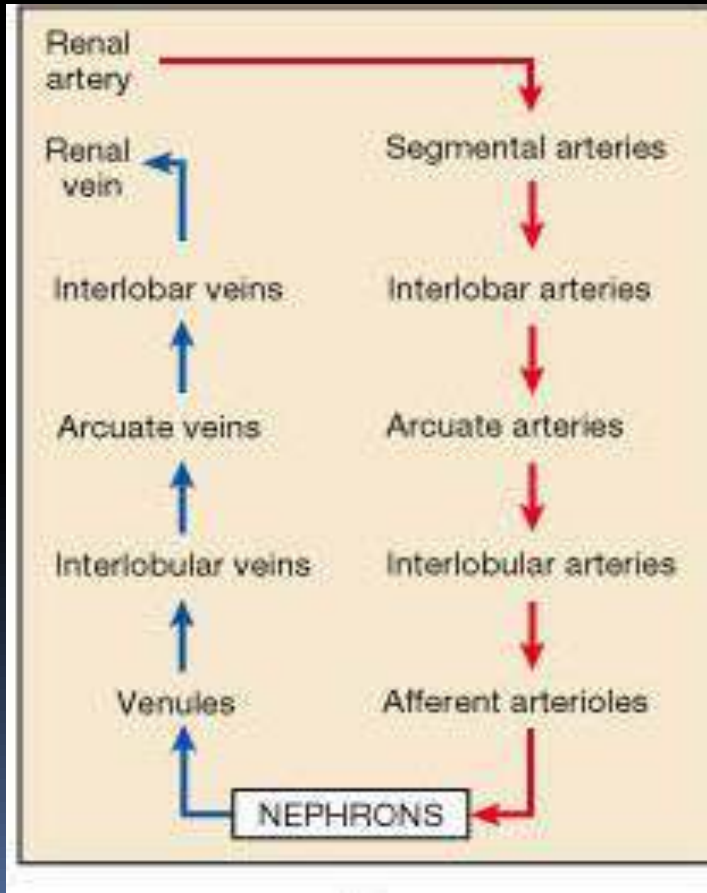
Medulla Renal

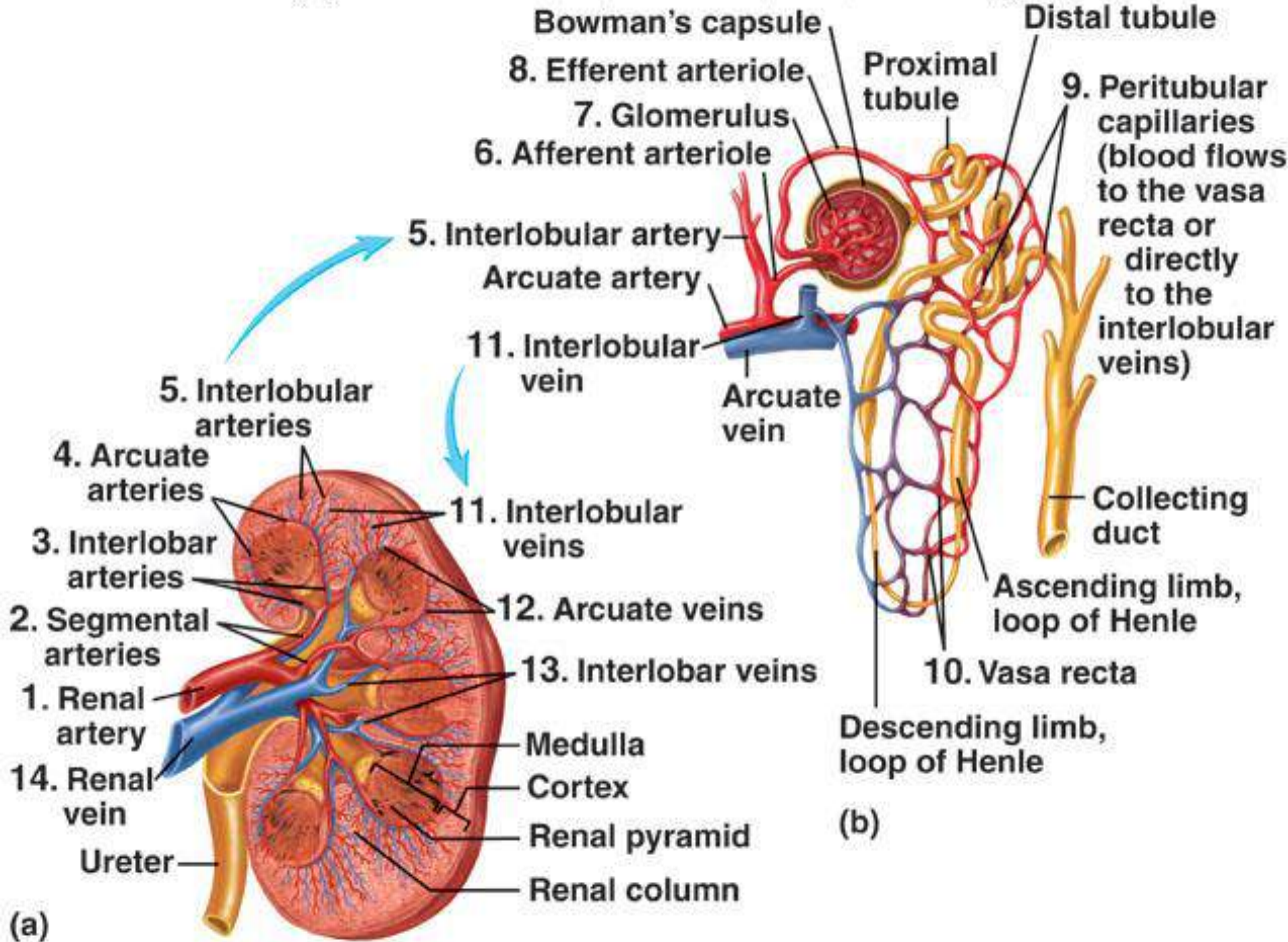
- Terdiri dari 6 -18 struktur berbentuk segitiga yang disebut pyramid. Satu dengan yang lain dipisahkan oleh columna renalis.



Renal Circulation

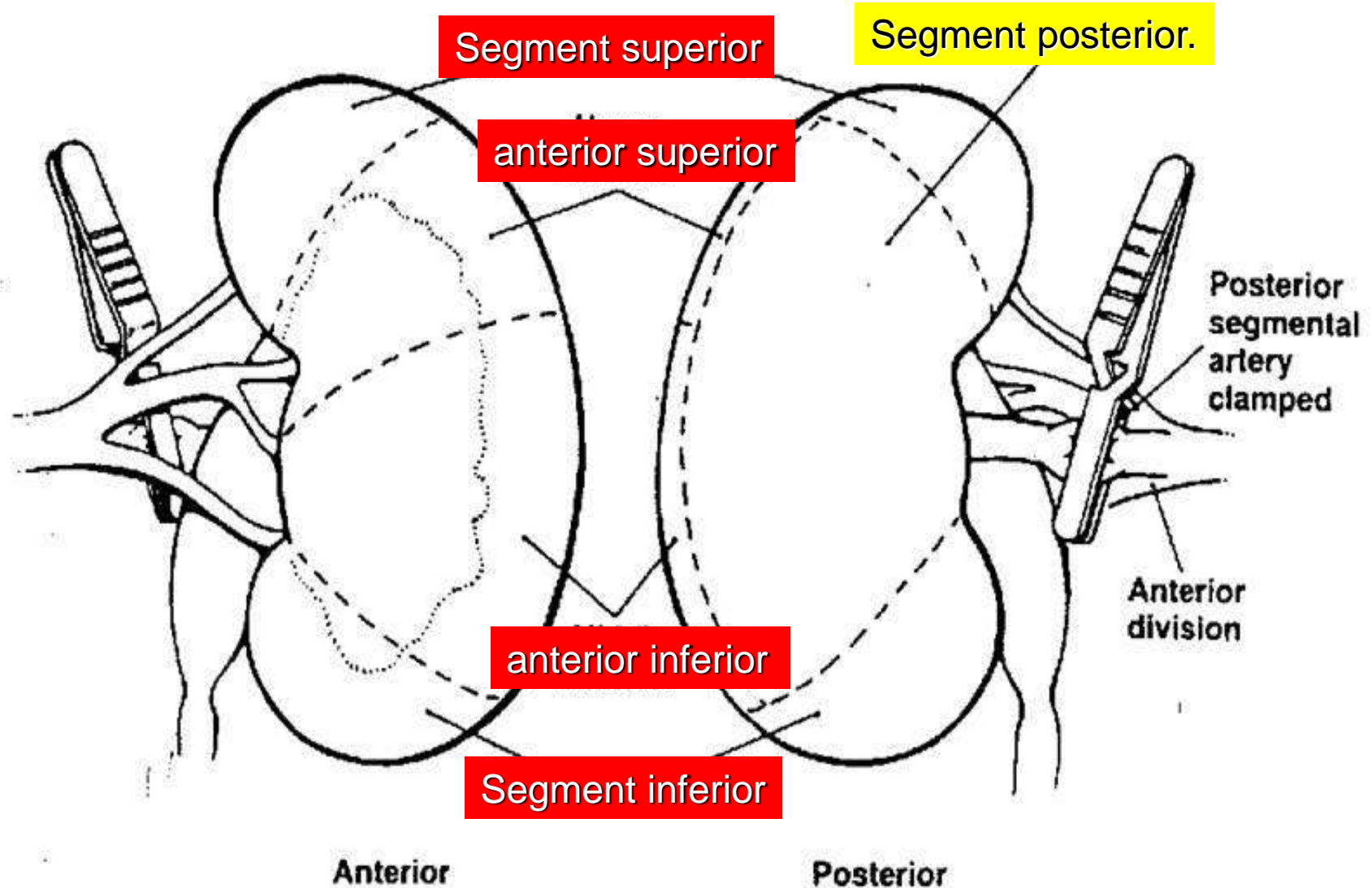
20-25% of cardiac output!!





5 Segments of the Kidney

Brodel Line.



Ureters

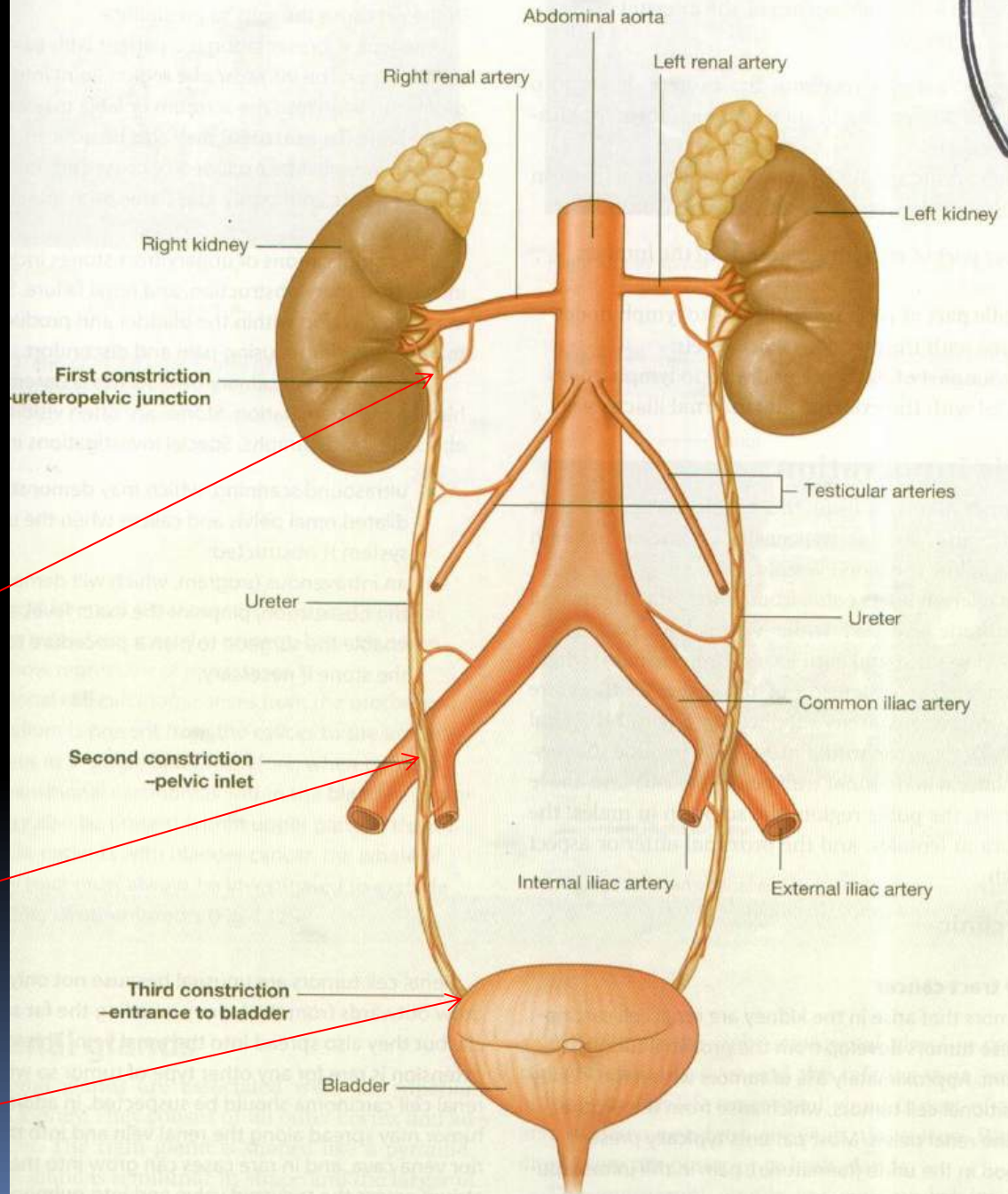
- Sepasang saluran musculer sepanjang 30 cm. (12 in)
- Ureter merupakan lanjutan dari pelvis renalis.
- Merupakan saluran yang mengalirkan urine dari ren menuju vesica urinaria.

Penyempitan

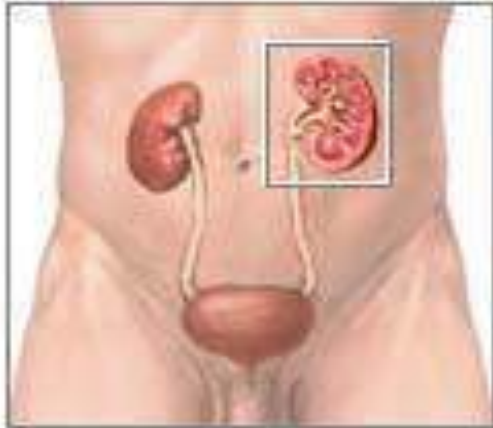
ada ureteropelvic junction.

ada saat menyilang a. iliaca communis

Maktu memasuki vesica urinaria

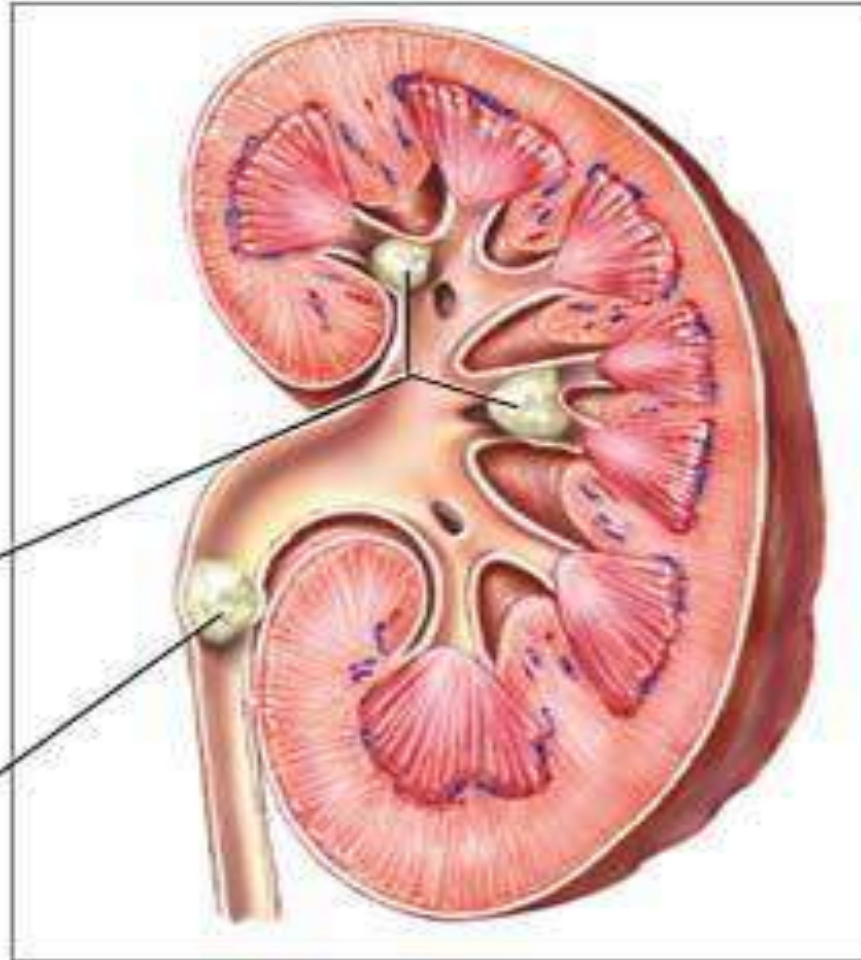


Nephrolithiasis

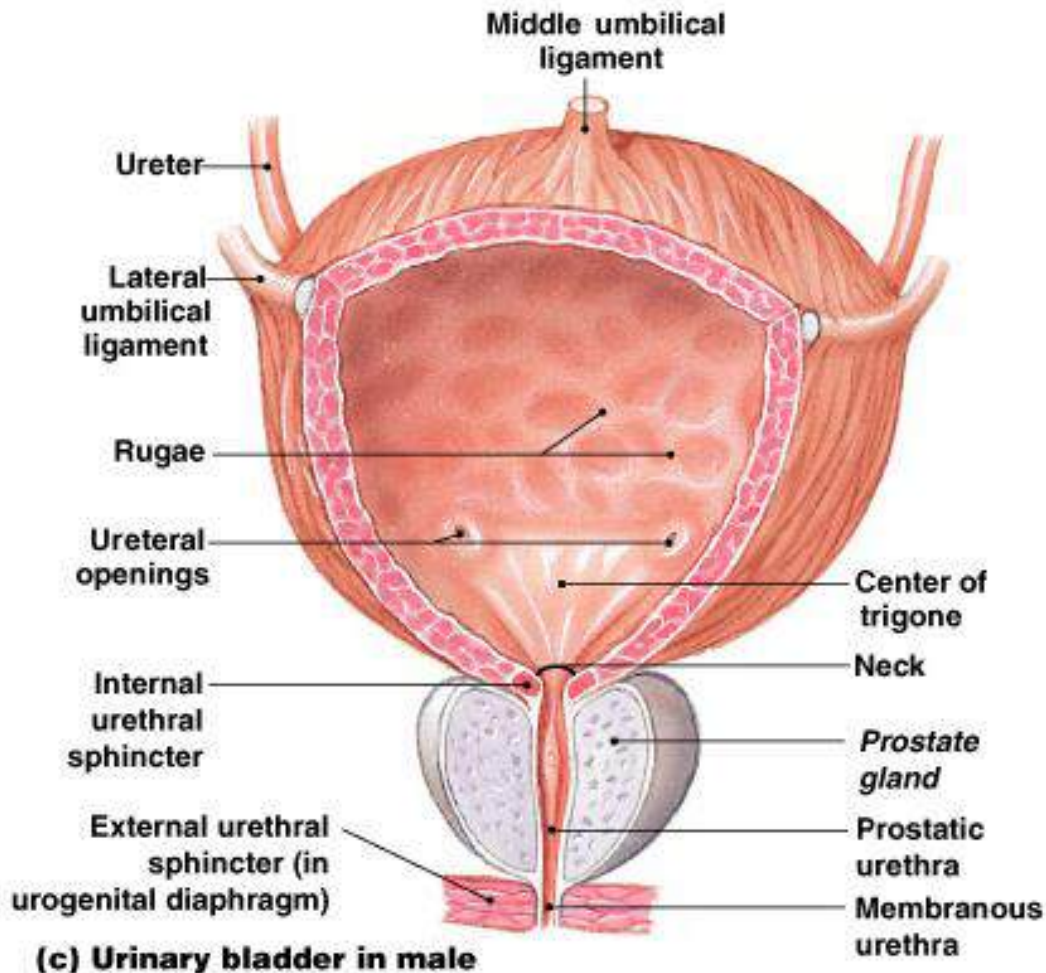


Kidney stones in the minor and major calyces of the kidney

Kidney stone in the ureter

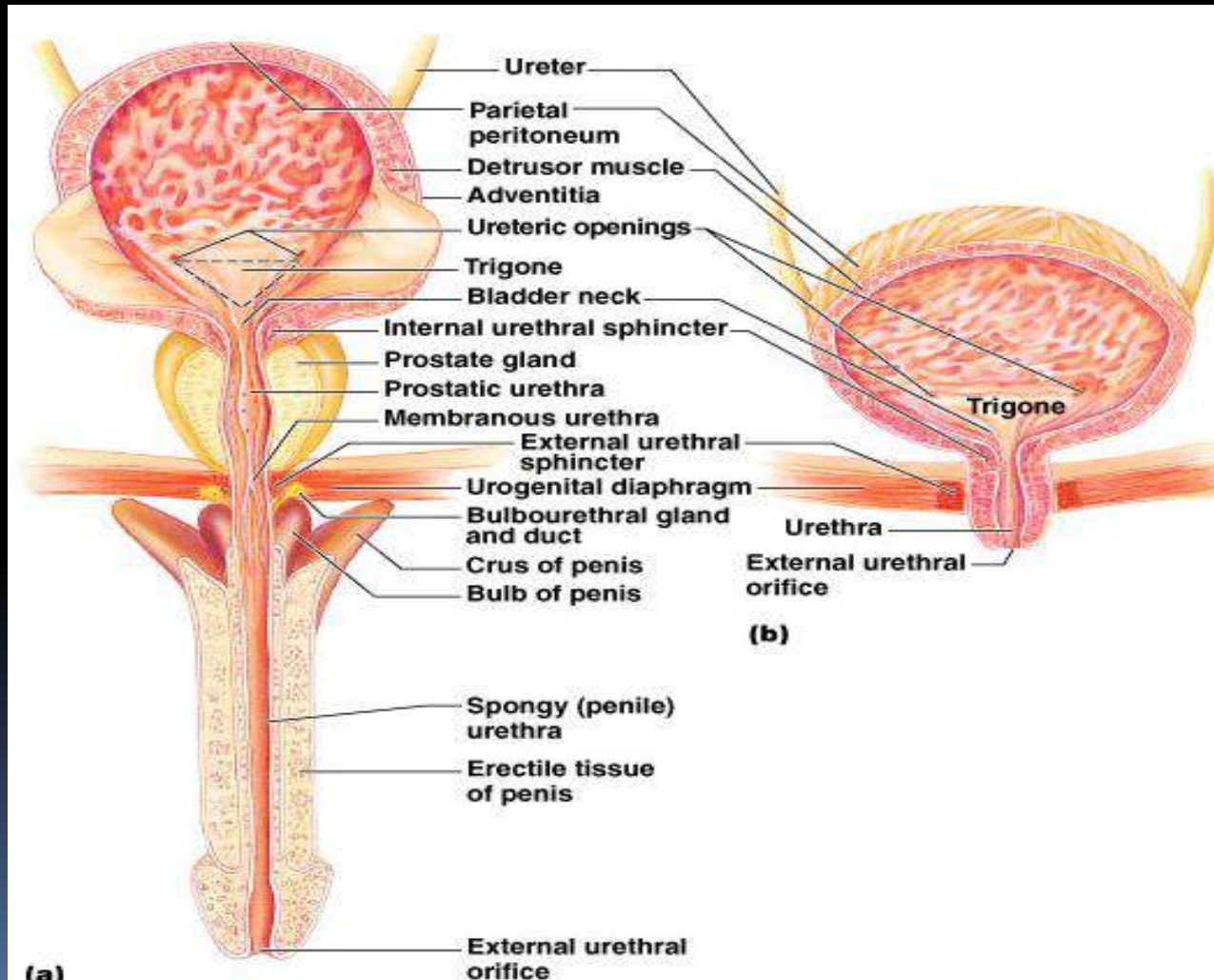


Urinary Bladder



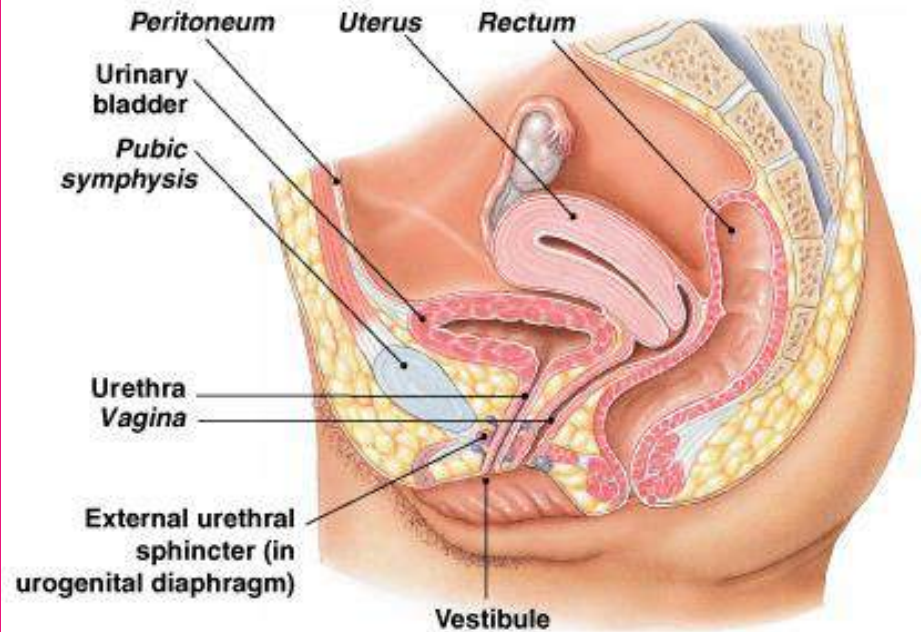
- Suatu organ berongga dengan bentuk yang berubah-ubah.
- Berfungsi sebagai penyimpanan sementara urine.
- Vesica urinaria dapat menampung 1 liter.
- Mucosa vesica urinaria berkerut kerut yang menghilang bila vu penuh.

Male vs. Female

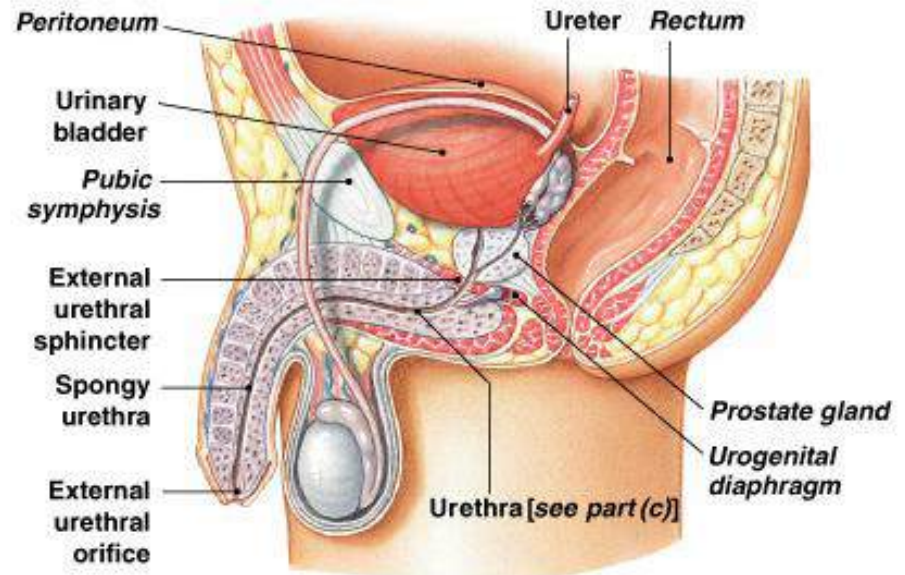


Urethra

- Dimulai dari orificium urethra interna.
- Menyalurkan urine dari vesica urinaria ke luar tubuh.
- Panjang pada wanita = 4 cm.
- Panjang pada pria = 20 cm.
 - Dibagi menjadi 3
 - Pars prostatica.
 - Pars membranacea.
 - Pars cavernosa.
 - Urethra pria juga menyalurkan semen pada saat ejakulasi.



(b) Female



(a) Male

Terima kasih

