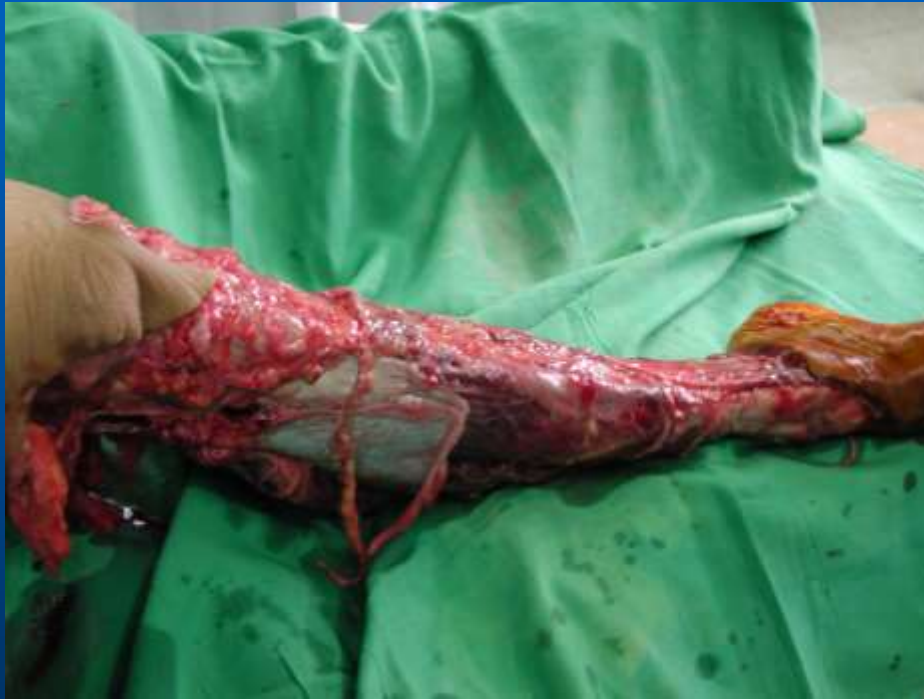

# COMPLICATIONS OF FRACTURES AND ITS MANAGEMENT

dr. BAMBANG WIDIWANTO, MS, SpOT  
FK UMM

# INTRODUCTION

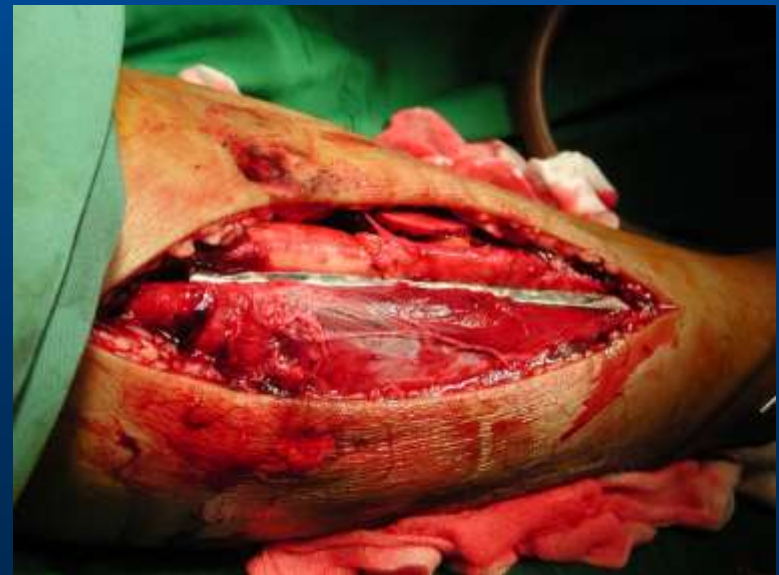
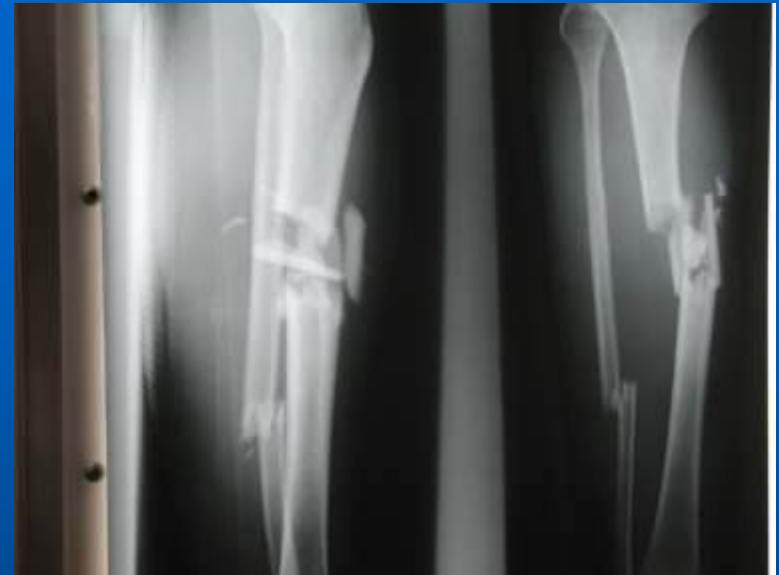
- Because bones are surrounded by soft tissue, the physical forces that produce a fracture always produce some degree of soft tissue injury as well.
- The associated soft tissue injury may assume much greater clinical significance than the fracture itself.

# INTRODUCTION

- Radiographs:
  - Just provide such graphic evidence of a fracture.
  - Seldom provide evidence of the extent of the associated soft tissue injury.

Therefore it must be thought in term of the fracture: What has happened to the surrounding soft tissue?



**General**

```
graph TD; A[General] --- B[Blood Loss]; A --- C[Shock]; A --- D[Fat Embolism]; A --- E[Cardiorespiratory Failure];
```

**Blood Loss**

**Shock**

**Fat Embolism**

**Cardiorespiratory Failure**

# LOCAL

Urgent

Less Urgent

Late

Local visceral injury

Vascular injury

Nerve injury

Compartment Syndrome

Haemarthrosis

Infection

Gas gangrene

Fracture blisters

Plaster sores

Pressure sores

Nerve entrapment

Myositis Ossificans

Ligament injury

Tendon lesions

Joint stiffness

Algdystrophy

Delayed union

Malunion

Non-union

Avascular necrosis

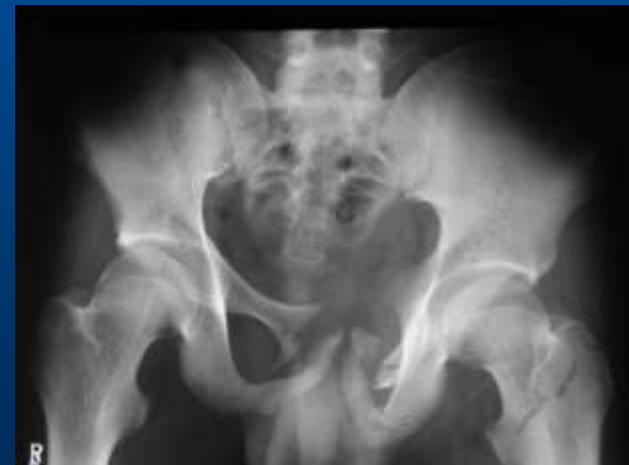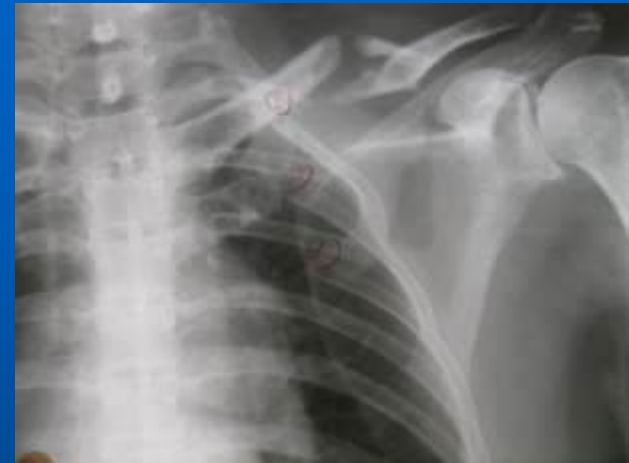Muscle contracture

Joint instability

Osteoarthrosis

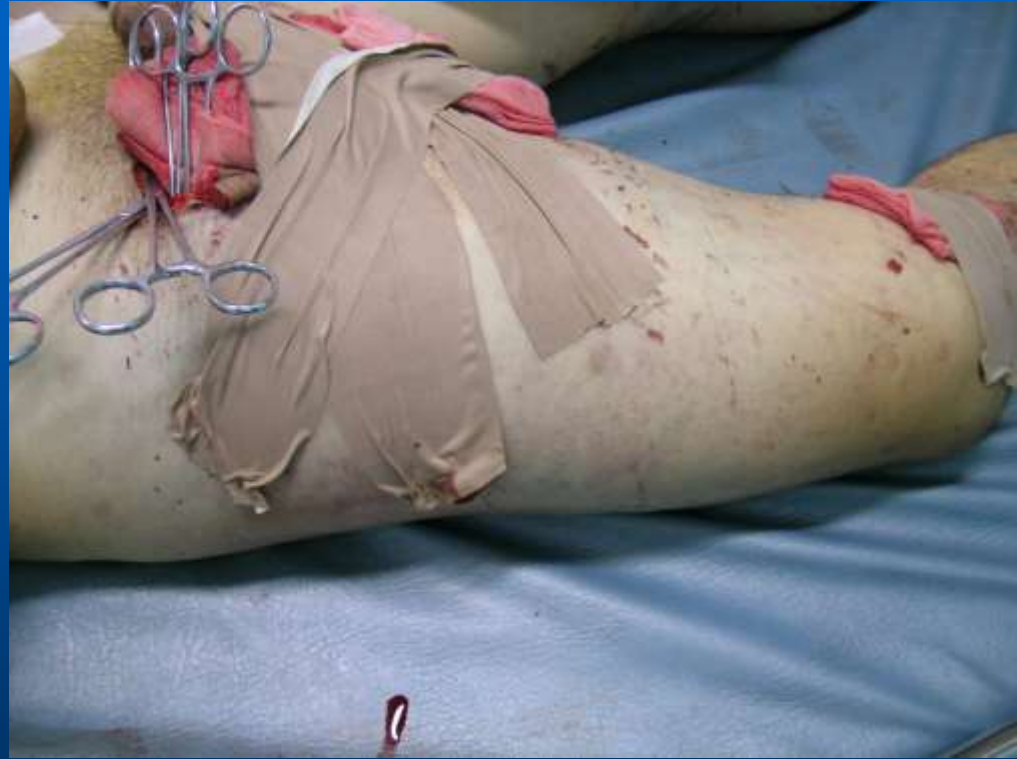# VISCERAL INJURY

- Penetration of the lung with life threatening pneumothorax -- following rib fractures.
- Rupture of the bladder or urethra in pelvic fractures.
- These injuries require emergency treatment.



# VASCULAR INJURY

- The artery may be cut, torn, compressed or contused, either by the initial injury or subsequently by jagged bone fragments.
- The effects vary from transient diminution of blood flow to profound ischaemia, tissue death and peripheral gangrene.



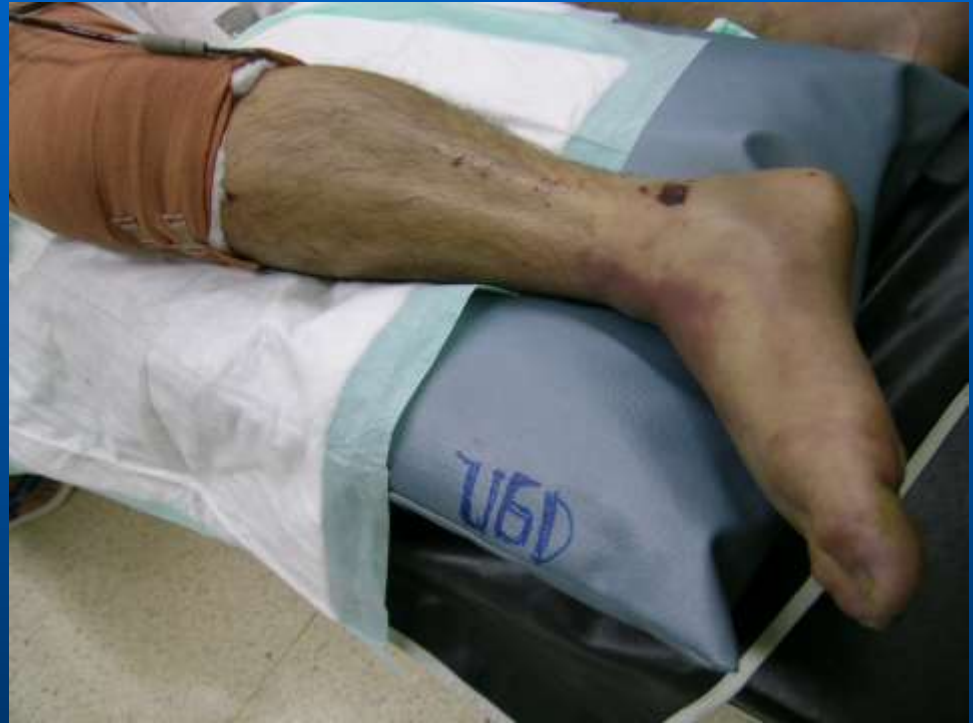# Common vascular injuries

<b>Injury</b>	<b>Vessel</b>
First rib fracture	Subclavian
Shoulder dislocation	Axillary
Humeral supracondylar fracture	Brachial
Elbow dislocation	Brachial
Pelvic fracture	Presacral and internal iliac
Femoral supracondylar fracture	Femoral
Knee dislocation	Popliteal
Proximal tibial	Popliteal



# Clinical feature – Vascular injury

- Paraesthesia or numbness in the toes or fingers.
- The injured limb is cold and pale, or slightly cyanosed.
- The pulse is weak or absent



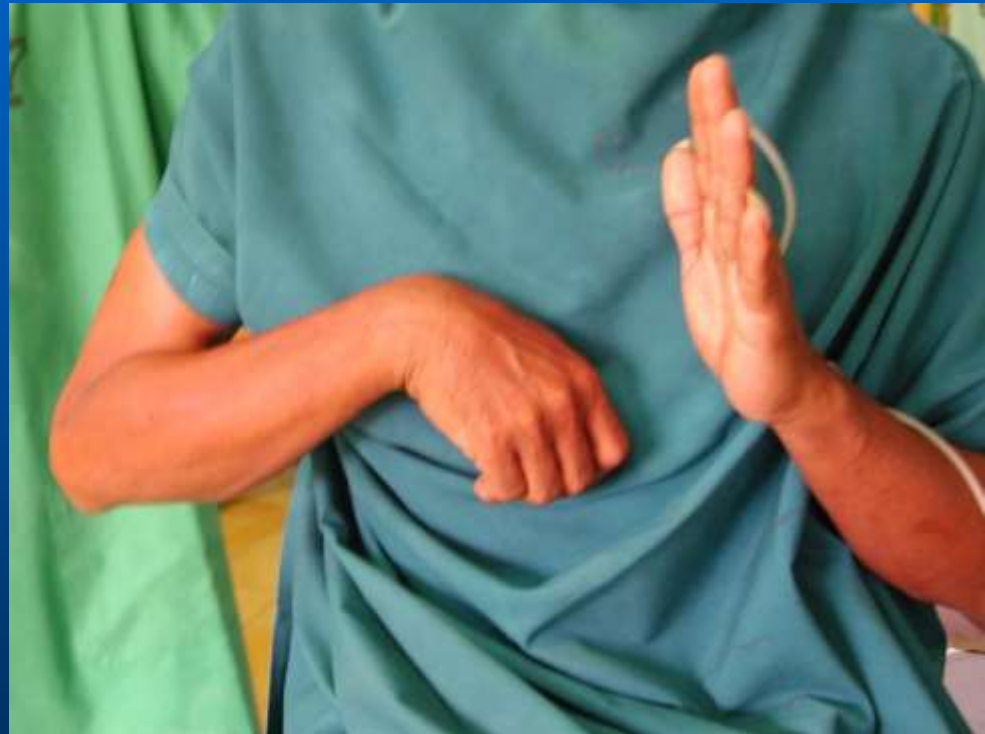# Treatment – Vascular injury

- Prompt reduction is necessary.
- The circulation is then reassessed.
- If there is no improvement the vessels must be explored by operation (preferably with the benefit of preoperative or peroperative angiography).
- A torn vessel can be sutured, or a segment may be replaced by a vein graft.
- If it is thrombosed, endarterectomy may restore the blood flow.

# NERVE INJURY

- Complaints of numbness or paraesthesia in the nerve distribution.

In close injury the nerve is seldom severed, and spontaneous recovery should be awaited – it occurs in 90% of cases within 4 months.



# Common nerve injuries

## Injury

Shoulder dislocation

Humeral shaft fracture

Humeral supracondylar fracture

Elbow medial condyle

Monteggia fracture-dislocation

Hip dislocation

Knee dislocation

## Nerve

Axillary

Radial

Radial or median

Ulnar

Posterior interosseous

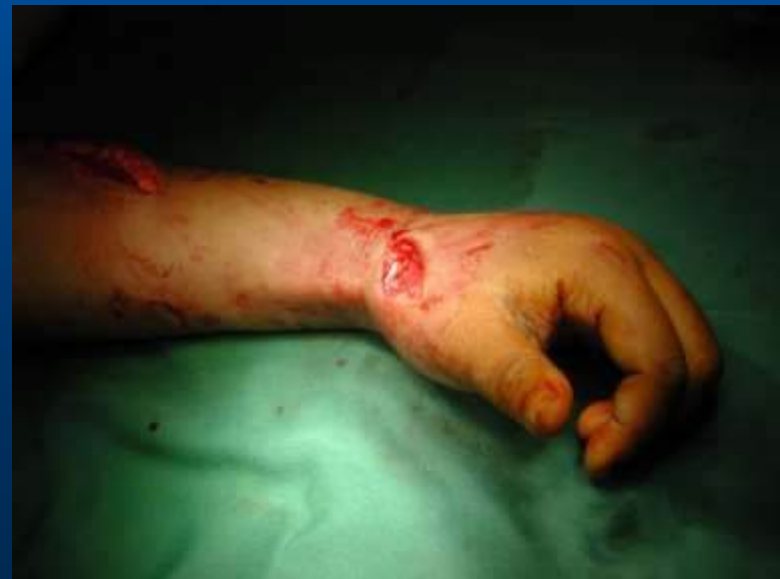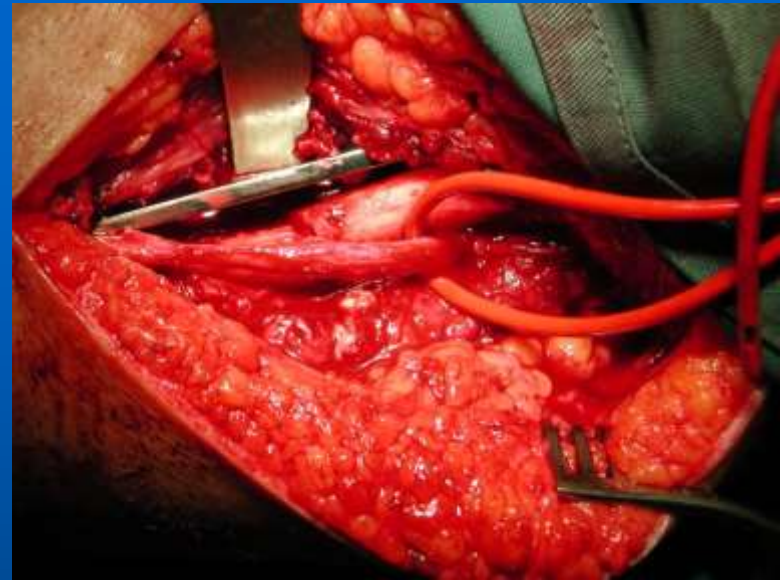
Sciatic

Peroneal

# NERVE INJURY

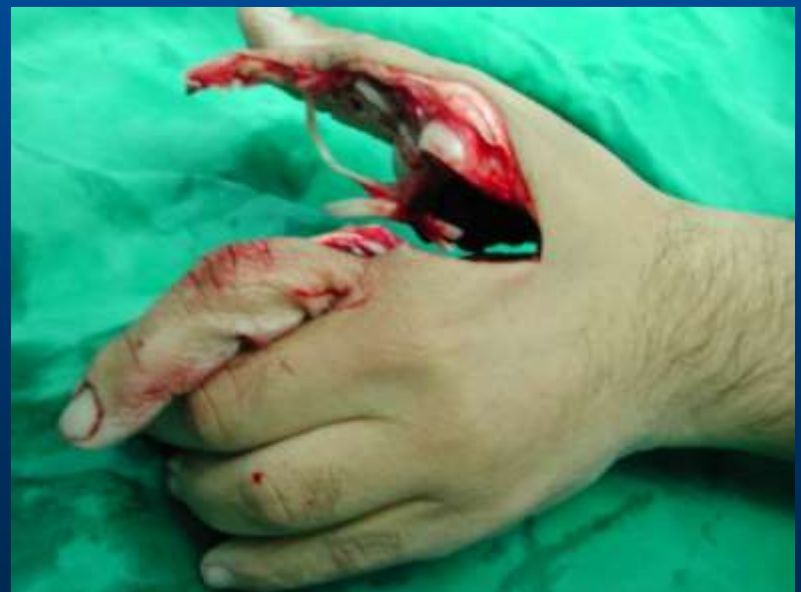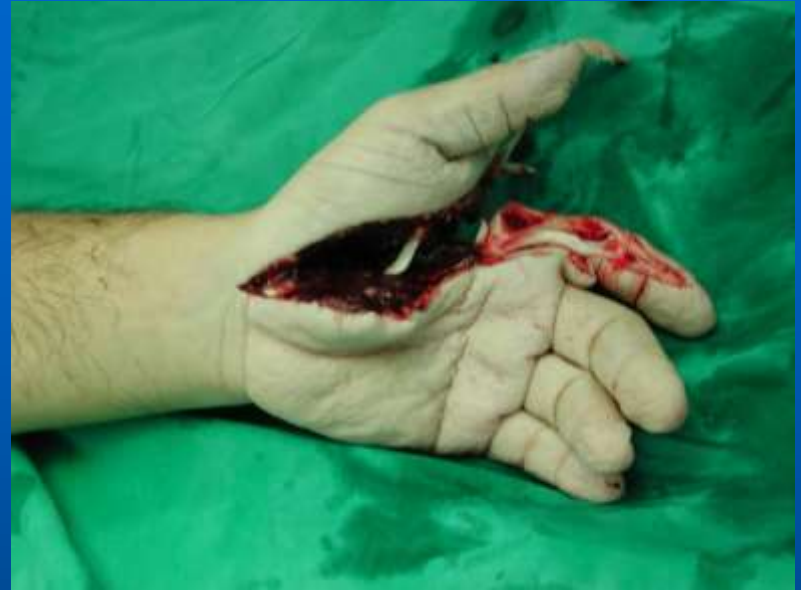**If recovery has not occurred by the expected time, and if nerve conduction studies fail to show evidence of recovery, the nerve should be explored.**

**Early exploration should also be considered if signs of a nerve injury appear after manipulation of the fracture. ( Siegel and Gelberman, 1991)**



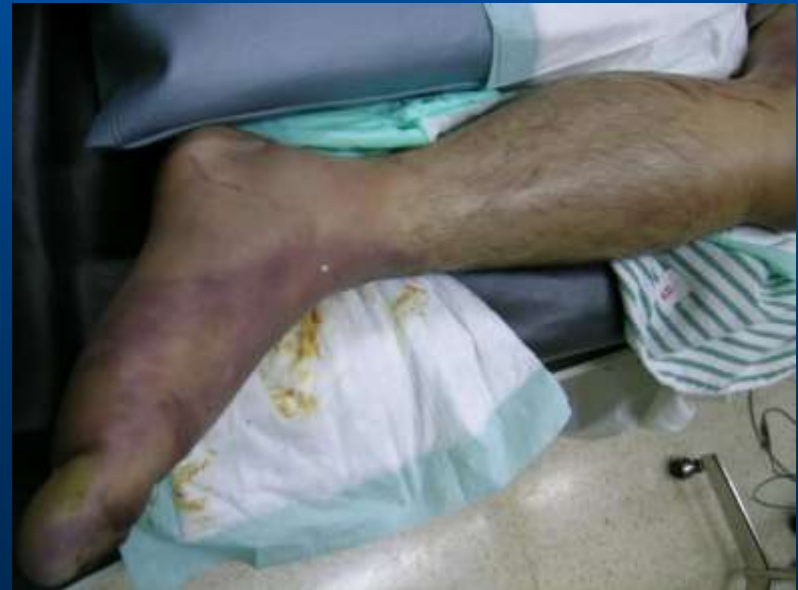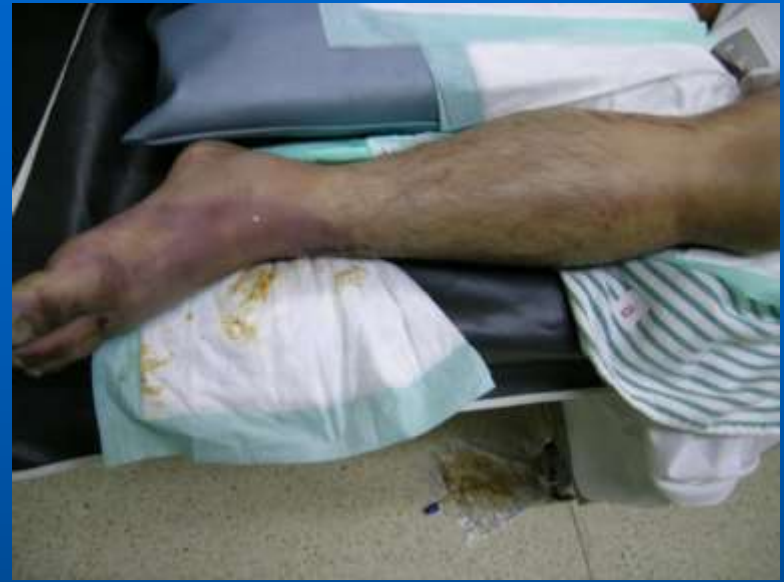# NERVE INJURY

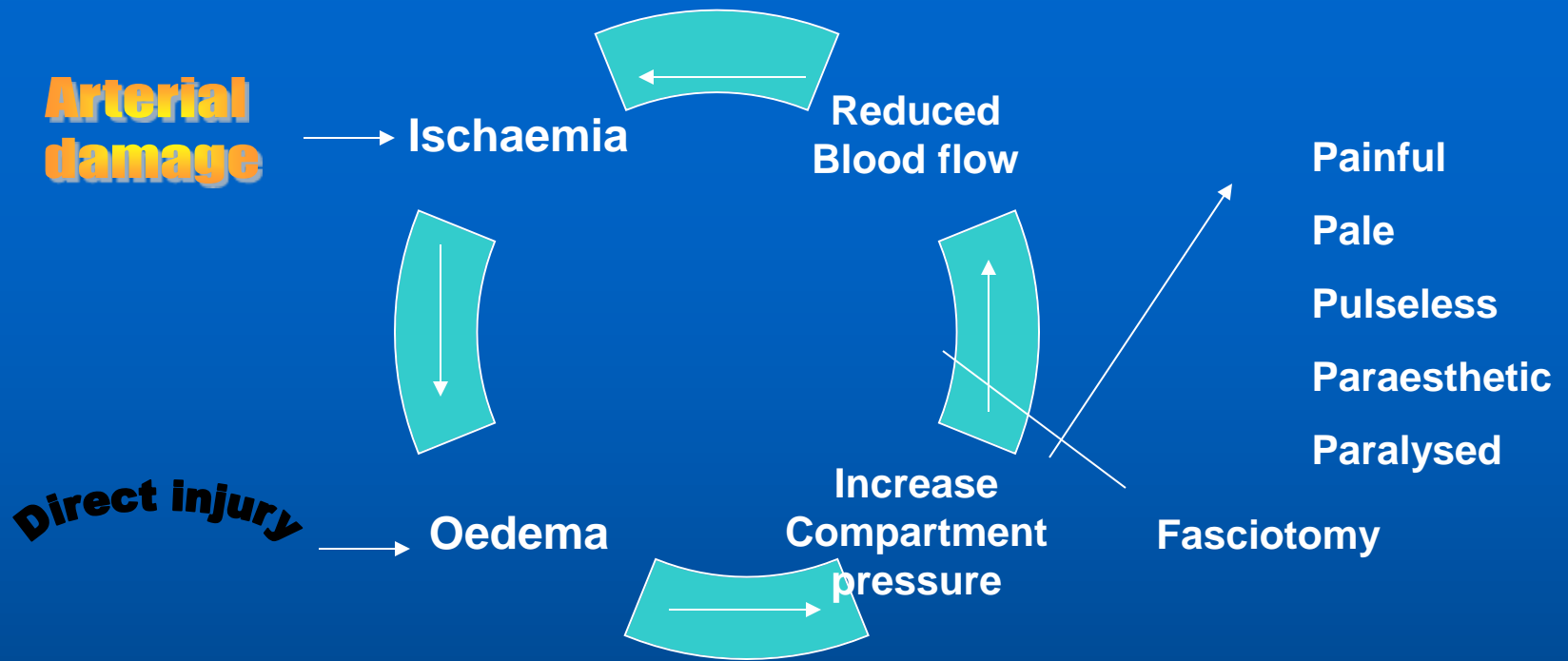
- In open fracture any nerve lesion is more likely to be complete; the nerve is explored during wound debridement and repair, either then or as a secondary procedure 3 week later



# COMPARTMENT SYNDROME

- Bleeding, oedema or inflammation may increase the pressure within one of the osteofascial compartment.
- There is reduced capillary flow which result in muscle ischaemia, further oedema, still greater pressure and yet more profound ischaemia.





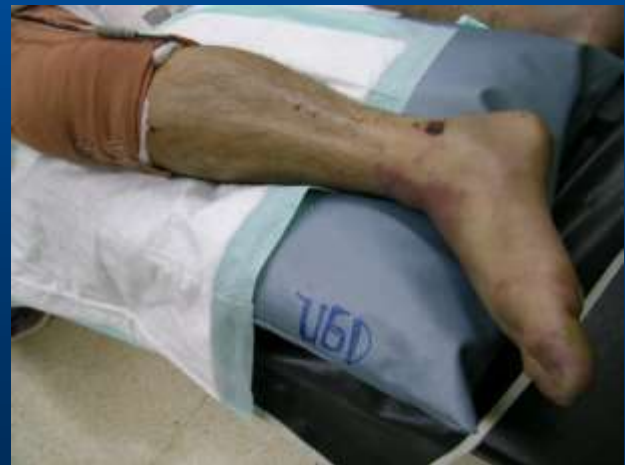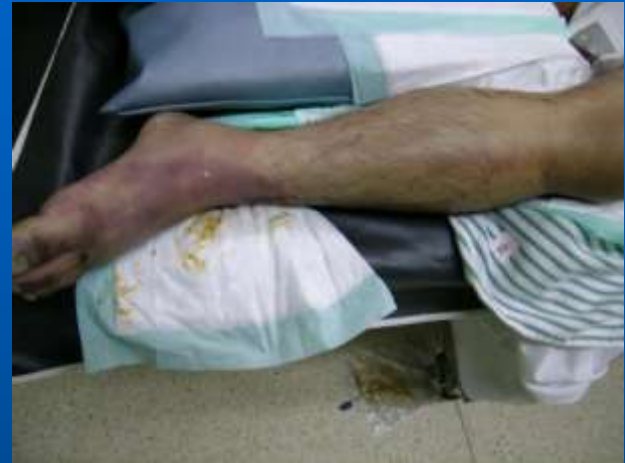A Vicious circle that ends, after 12 hours or less, in necrosis of nerve and muscle within compartment.

Nerve is capable of regeneration but muscle, once infarcted, can never recover and is replaced by inelastic fibrous tissue ( VOLKMANN'S ISCHAEMIC CONTRACTURE )

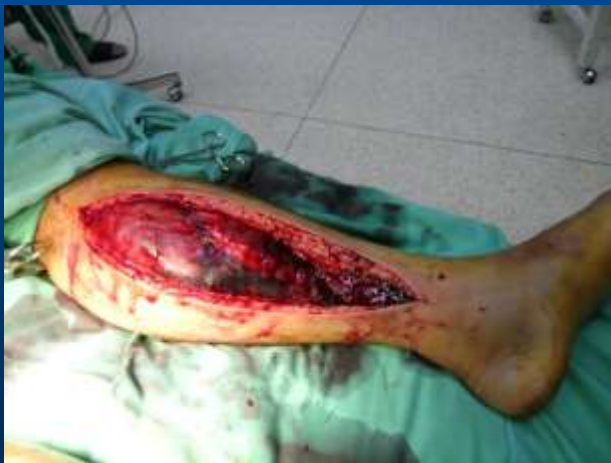
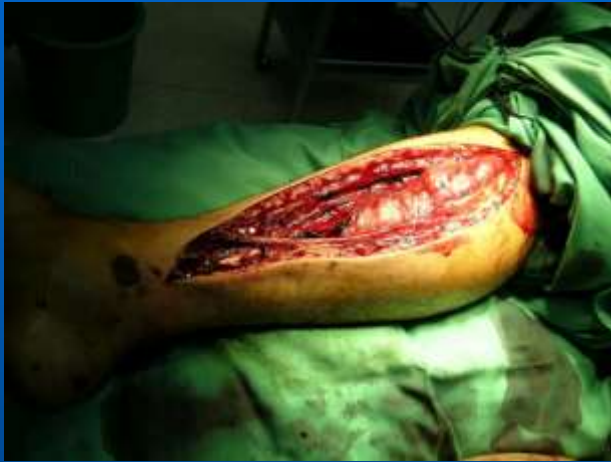
# Clinical Features – Compartment Syndrome

- Ischaemic muscle is highly sensitive to stretch, it should be tested by stretching them – when the toes or fingers are passively hyperextended there is increase pain in the calf or forearm.
- The presence of a pulse does not exclude the diagnosis.
- In doubtful cases the diagnosis can be confirmed by measuring the intracompartmental pressure.



# Treatment – Compartment Syndrome



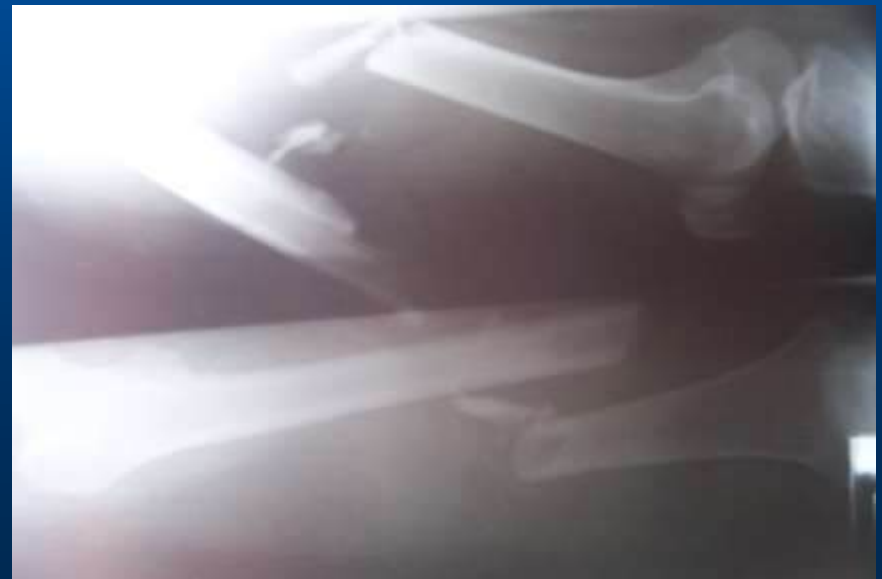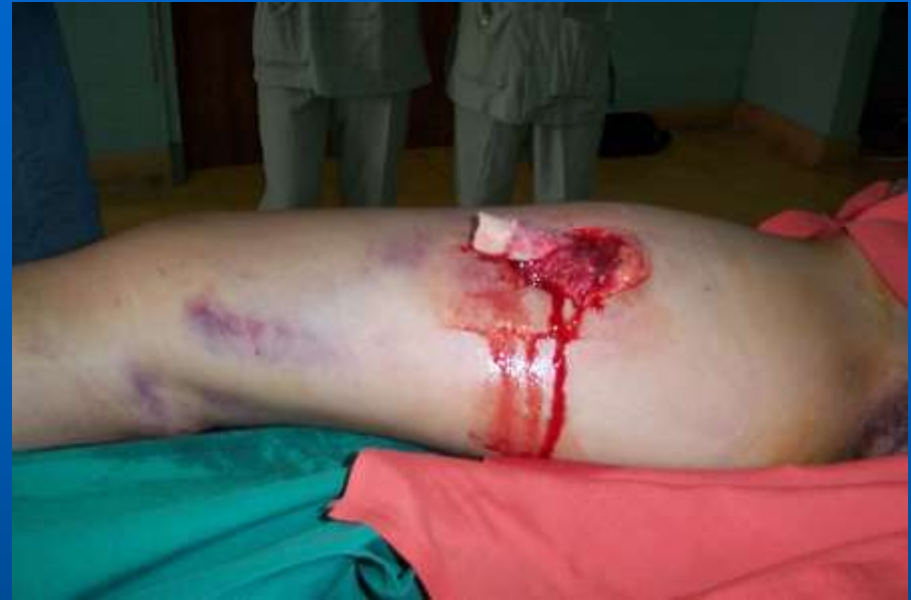- The threatened compartment must be promptly decompressed. Cast, bandage and dressing must be completely removed.
- A differential pressure between diastolic and compartment should be monitored, if it falls below 30 mmHg, immediate open fasciotomy is performed

# HAEMARTHROSIS

- Fractures involving a joint may cause acute haemarthrosis.
- The joint is swollen and tense and the patient resist any attempt at moving it.
- The blood should be aspirated before dealing with the fracture.

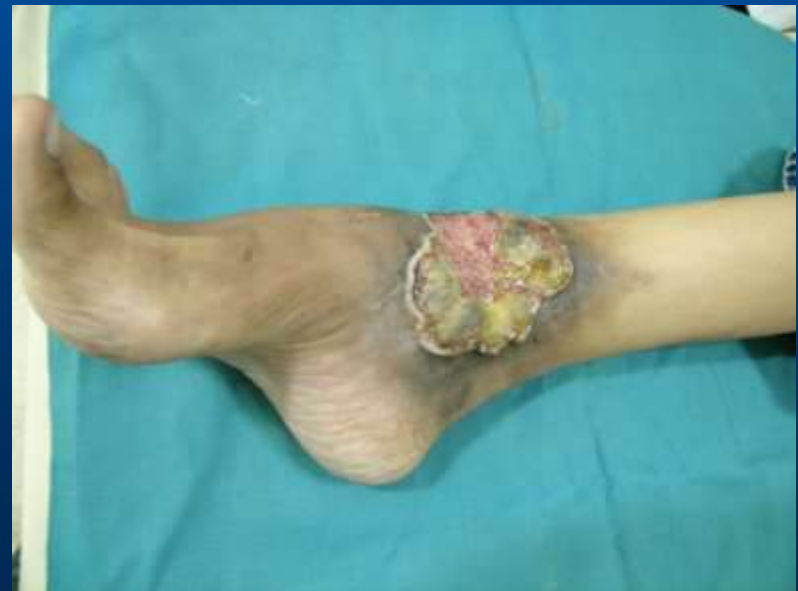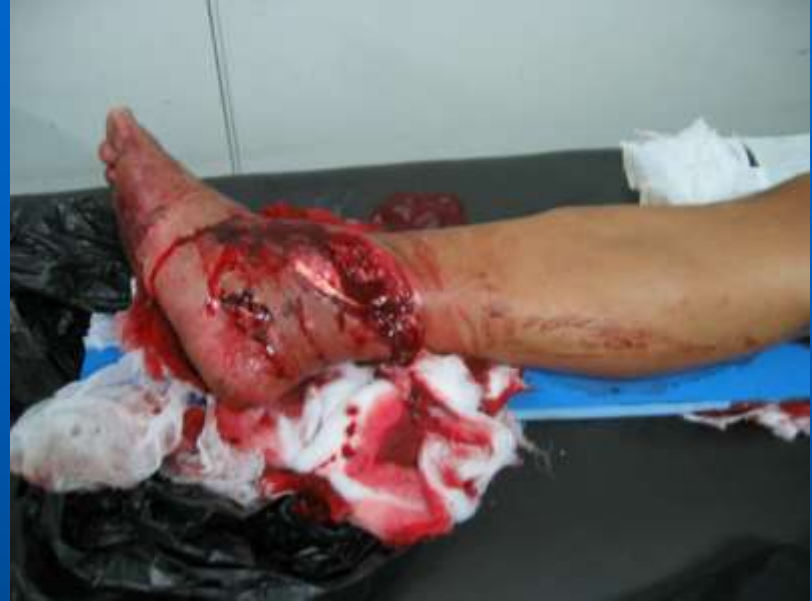# INFECTION

- Open fracture may become infected.
- Closed fractures hardly ever do unless they are opened by operation.
- Post-traumatic wound infection is now the most common cause of chronic osteitis.
- This does not prevent the fracture from uniting, but union will be slow and chance of refracturing is increase.



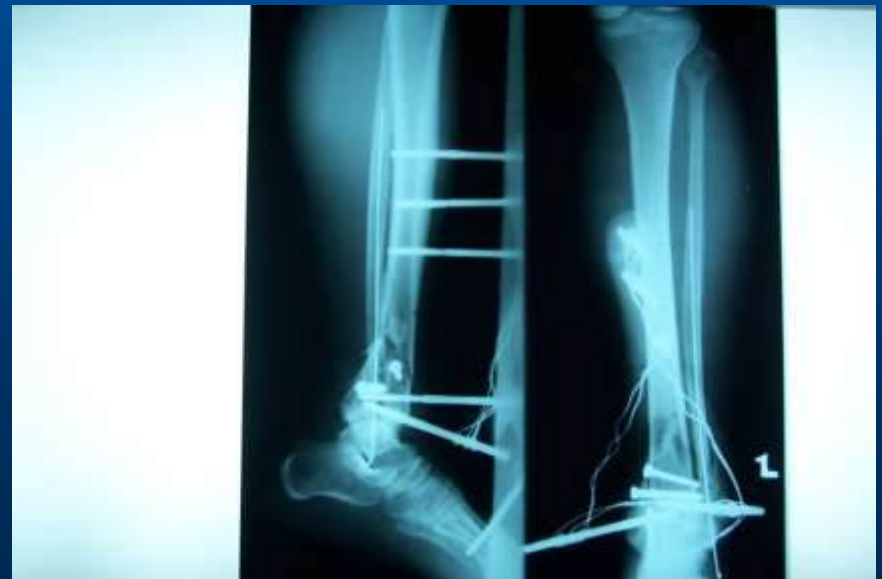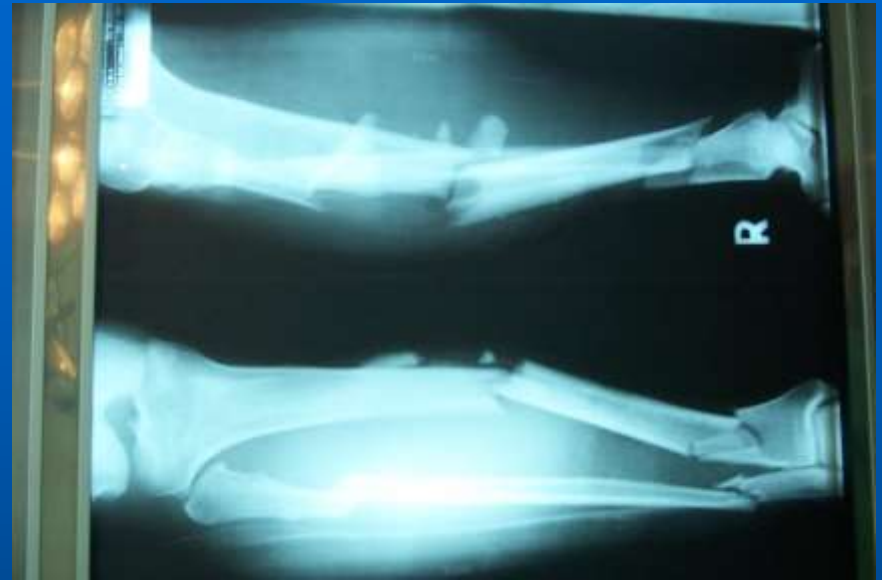# Clinical features - Infection

- The history is of an open fracture or an operation on a closed fracture.
- The wound becomes inflamed and starts draining seropurulent fluid, a sample of which may yield a growth of staphylococci or mixed bacteria.



# Treatment - Infection

- All open fractures should be regarded as potentially infected – antibiotics and meticulously excising all devitalized tissue.
- Signs of acute infection and pus formation, the tissue around the fracture should be opened and drained.
- External fixation is useful in such cases



# GAS GANGRENE

- Produced by Clostridial infection ,especially Clostridium welchii – anaerobic organism that can survive and multiply only in tissues with low oxygen tension.
- The prime site is a dirty wound with dead muscle that has been closed without adequate debridement.
- Toxins produced by the organisms destroy the cell wall and rapidly lead to tissue necrosis, thus promoting the spread of the disease.

# Clinical feature – Gas gangrene

- Appear within 24 hours of injury.
- Intense pain, swelling around the wound and a brownish discharge may be seen. Gas formation is usually not very marked.
- Pulse rate is increase and a characteristic smell becomes evident. Rapidly the patient becomes toxaemic and may lapse into coma and death.



# Clinical feature – Gas gangrene

- It is essential to distinguish gas gangrene, which is characterized by myonecrosis, from anaerobic cellulitis, in which superficial gas formation is abundant but toxaemia usually slight.
- Failure to recognize the difference may lead to unnecessary amputation for the nonlethal cellulitis.

# Prevention – Gas gangrene

- Deep, penetrating wound in muscular tissue are dangerous; they should be explored, all dead tissue should be completely excised.
- If there is the slightest doubt about tissue viability, the wound should be left open.
- Unhappily there is no effective antitoxin against *C.welchii*.

# Treatment – Gas gangrene

- The key to life-saving treatment is early diagnosis.
- Fluid replacement and intravenous antibiotic are started immediately.
- Hyperbaric oxygen has been used as a means of limiting the spread of gangrene.
- The mainstay of treatment is prompt decompression of the wound and removal of all dead tissue.
- In advanced cases, amputation may be essential.

# FRACTURE BLISTERS

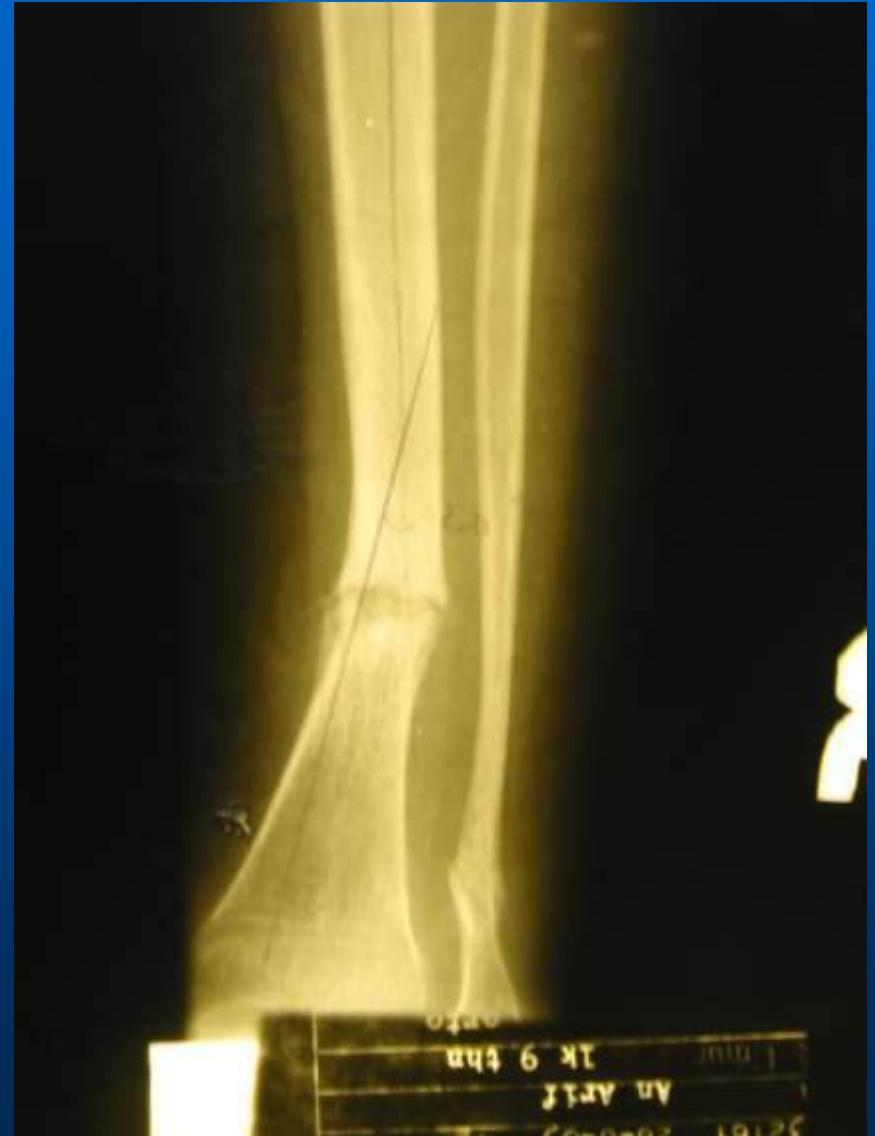- These are due to elevation of the superficial layers of skin by oedema, and can sometime be prevented by firm bandaging.
- They should be covered with a sterile dry dressing.

# PLASTER SORES AND PRESSURE SORES

- Plaster sores occur where skin presses directly onto bone. They should be prevented by padding the bony points and by moulding the wet plaster so that pressure is distributed to the soft tissue around the bony points.
- While a plaster sore is developing the patient feels localized burning pain. A window must immediately be cut in the plaster, or warning pain quickly abates and skin necrosis proceeds unnoticed.

# DELAYED UNION

- If the time is unduly prolonged, the term 'delayed union' is used.
- Factors causing delayed union can be summarized as :
  - Biological
  - Biomechanical
  - Patient related



# BIOLOGICAL FACTORS

- **INADEQUATE BLOOD SUPPLY**

A badly displaced fracture of a long bone will cause tearing of both the periosteum and interruption of the intramedullary blood supply.

- **SEVERE SOFT TISSUE DAMAGE**

- Reducing the effect of muscle splintage.
- Damaging blood supply.
- Diminishing the osteogenic stimulus.

- **PERIOSTEAL STRIPPING**

# BIOMECHANICAL FACTORS

- **IMPERFECT SPLINTAGE**

Excessive traction, excessive movement or isolated fracture of forearm or leg will delay ossification in the callus.

- **OVER-RIGID FIXATION**

Contrary to popular belief, rigid fixation delays rather than promotes fracture union. Union by primary bone healing is slow.

- **INFECTION**

There is bone lysis, necrosis and pus formation but also implants which are used to hold the fracture tend to loosen.



# Clinical features – Delayed Union

- Fracture tenderness persists and if the bone is subjected to stress, pain may be acute.
- X-Ray
  - The fracture line remains visible and there is very little callus formation or periosteal reaction.
  - The bone ends are not sclerosed or atrophic.

# Conservative Treatment – Delayed Union

The two important principles are:

1. To eliminate any possible cause of delayed union.
2. To promote healing by providing the most appropriate biological environment.

Fracture loading is an stimulus to union by:

- a. By encouraging muscular exercise
- b. By weightbearing in the cast or brace

# Operative Treatment – Delayed Union

If union is delayed for more than 6 months and there is no sign of callus formation, fixation and bone grafting are indicated.

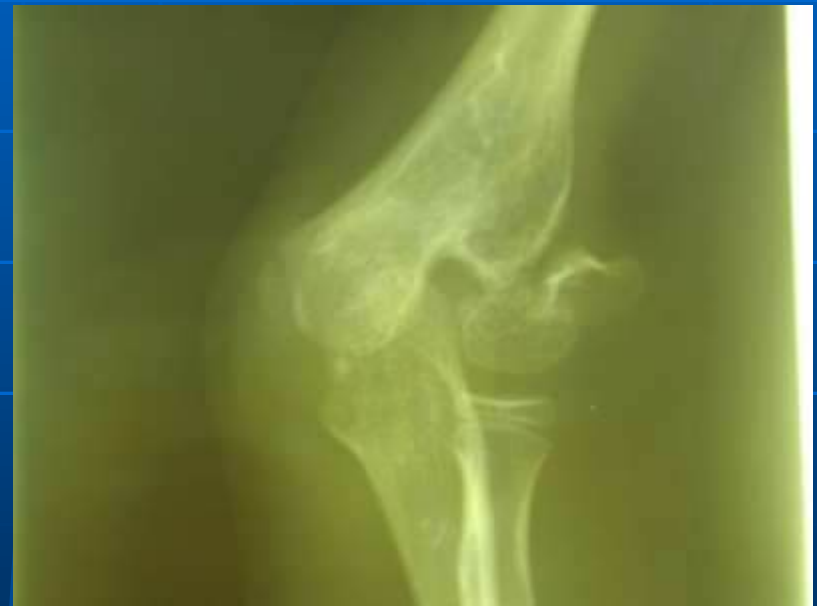The operation should be planned in such a way as to cause the least possible damage to the soft tissue.

# NON-UNION

The fracture gap become a type of pseudoarthrosis.

In hyperthropic non-union the bone ends are enlarged, suggesting that osteogenesis is still active but not quite capable of bridging the gap.

In atrophic non-union osteogenesis seems to have ceased. The bone ends are often tapered or rounded with no suggestion of new bone formation.



# Causes of non-union

## The Injury

Soft tissue loss

Bone loss

Intact fellow bone

Soft tissue interposition

## The bone

Poor blood supply

Poor haematoma

Infection

Pathologic lesion

## The surgeon

Distraction

Poor splintage

Poor fixation

Impatience

## The patient

Immense

Immoderate

Immovable

Impossible

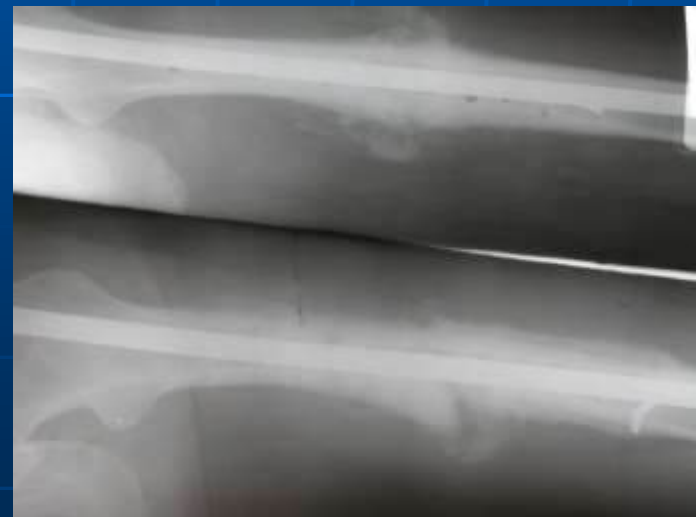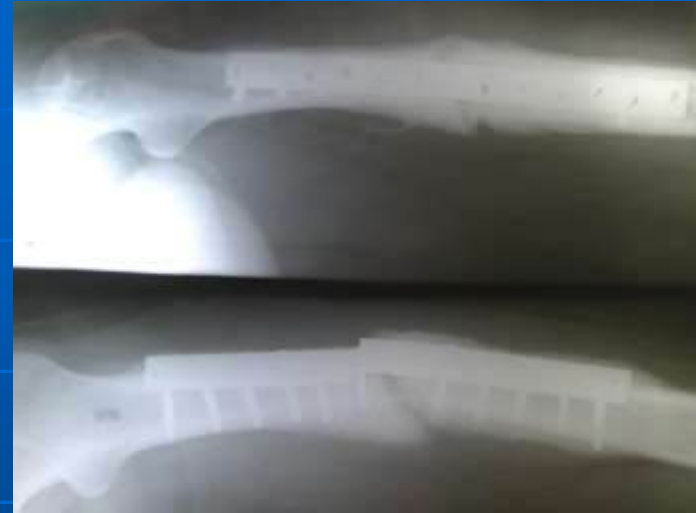# CONSERVATIVE TREATMENT

With hyperthropic non-union,

- Functional bracing may be sufficient to induce union.
- Pulse electromagnetic fields.
- Low frequency pulsed ultrasound can

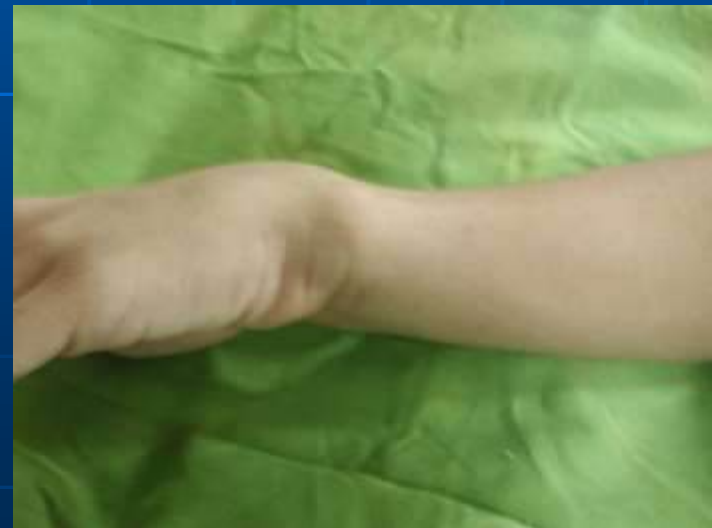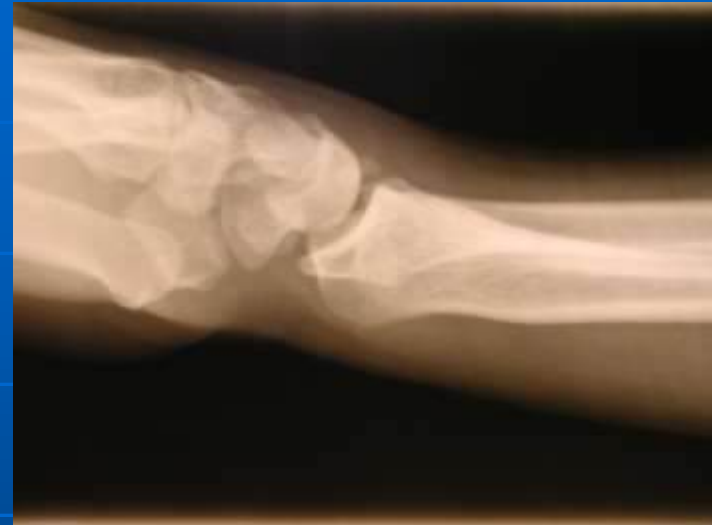# OPERATIVE TREATMENT

- Hypertrophic non-union, rigid fixation alone may lead to union.
- Atrophic non-union, fixation alone is not enough. Fibrous tissue in the fracture gap, as well as the hard, sclerotic bone ends, are excised and bone grafts are packed around the fracture.



# MALUNIION

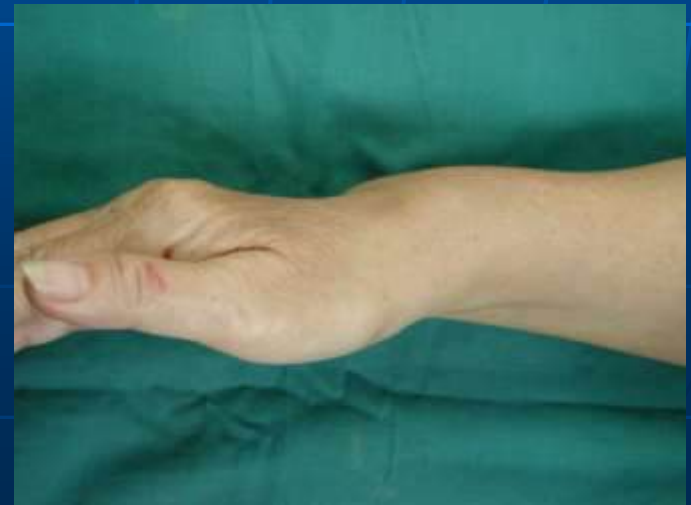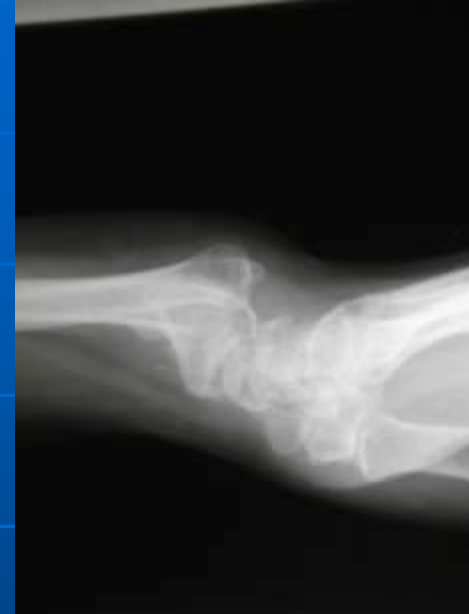- When the fragments join in an unsatisfactory position (unacceptable angulation, rotation or shortening) the fracture is said to be malunited.
- Causes are failure to reduce a fracture adequately, failure to hold reduction while healing proceeds or gradual collapse of comminuted or osteoporotic bone.





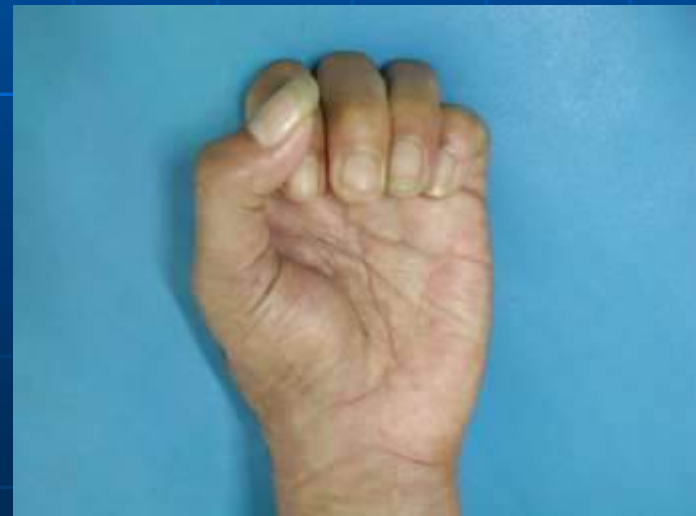# Clinical features - Malunion

- The deformity is usually obvious, but sometimes apparent only on X-ray.
- Rotational deformity of the femur, tibia, humerus or forearm may be missed unless the limb is compared with its opposite fellow.



# Clinical features - Malunion

- Rotational deformity of a metacarpal fracture is detected by asking the patient to flatten the fingers onto the palm and seeing whether the normal regular fan-shaped appearance is reproduced.



# Treatment – Malunion

## A few guidelines are offered

1. In adults, angulation of more than  $10 - 15^{\circ}$  in a long bone, or a noticeable rotational deformity, may need correction by remanipulation, or by osteotomy and internal fixation.
2. In children, angular deformities near the bone ends will usually remodel with time; rotational deformity will not.
3. In the lower limb, shortening of more than 2.0cm is seldom acceptable to the patient and a limb lengthening procedure may be indicated.
4. The patient's expectation (often prompted by cosmesis) may be quite different from the surgeon's; they are not to be ignored.

# Treatment – Malunion

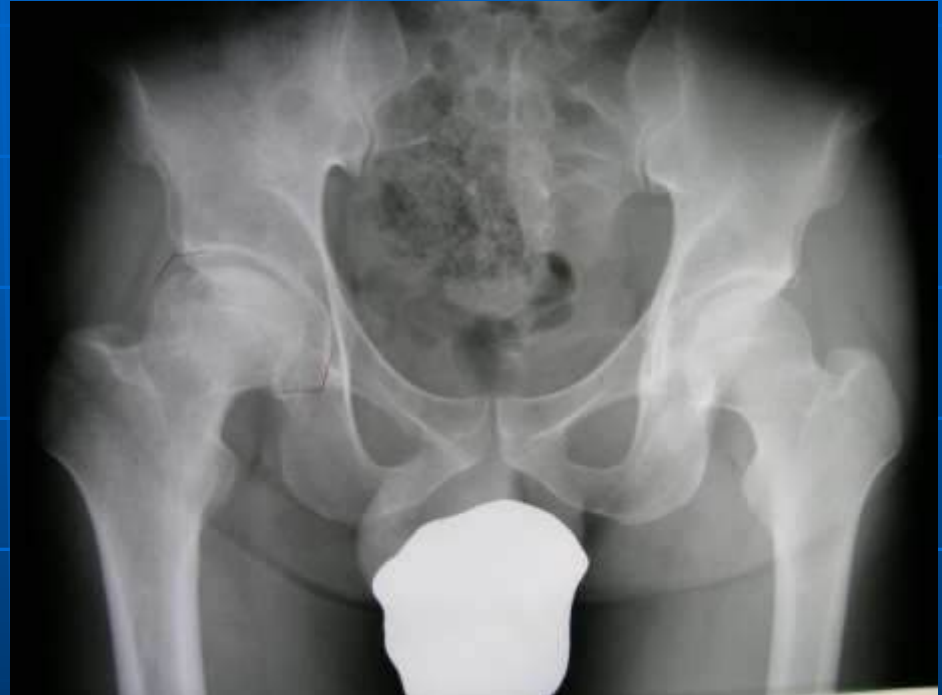## A few guidelines are offered

5. Early discussion with the patient, and a guided view of the X-rays, will help in deciding on the need for treatment and may prevent later misunderstanding.
6. Malalignment of more than  $15^{\circ}$  in any plane may cause asymmetrical loading of the joint above or below and the late development of secondary osteoarthritis; this applies particularly to the large weightbearing joints.

# AVASCULAR NECROSIS

Certain regions are notorious for their propensity to develop ischaemia and bone necrosis after injury:

1. The head of the femur (after fracture of femoral neck or dislocation of the hip).
2. The proximal part of the scaphoid (after fracture through its waist).
3. The lunate (following dislocation).
4. The body of the talus (after fracture of its neck).



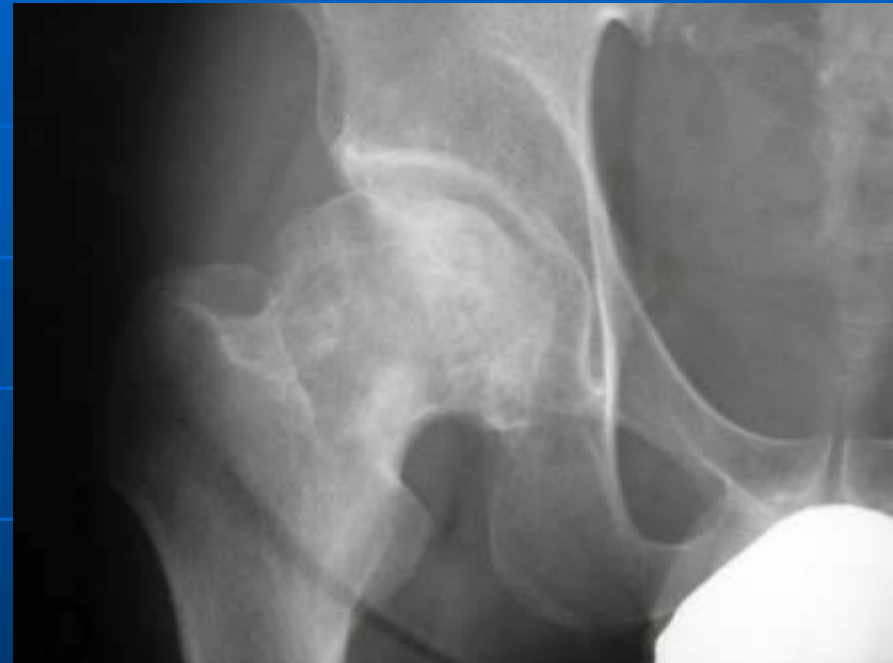# AVASCULAR NECROSIS

Ischaemia occurs during the first few hours following fracture or dislocation.

However, the clinical and radiological effects are not seen until weeks or even months later.

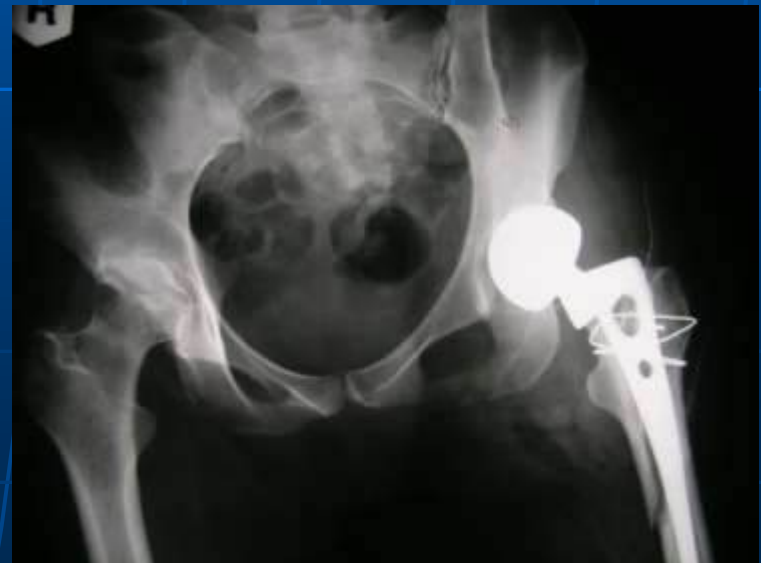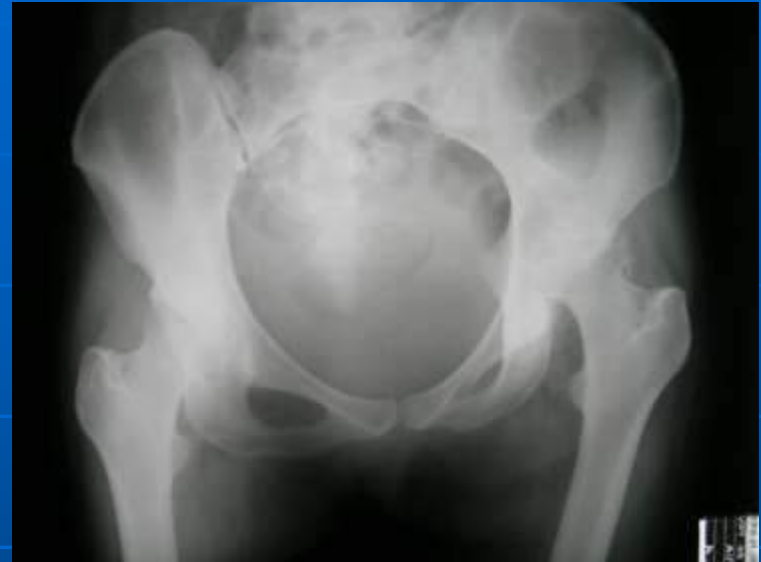# Clinical feature – Avascular Necrosis

- There are no symptoms associated with avascular necrosis, but if the fracture fails to unite or if the bone collapses the patient may complain of pain.
- The X-ray shows:
  - Increase in bone density.
  - New bone ingrowth in the necrotic segment.
  - Disuse osteoporosis in the surrounding parts



# Treatment – Avascular Necrosis

- In old people with necrosis of the femoral head an arthroplasty is the obvious choice, in younger people, realignment osteotomy (or even arthrodesis) may be wiser.
- Avascular necrosis in the scaphoid or talus may need no more than symptomatic treatment, but vascular bone grafting, or arthrodesis of the wrist or ankle, is sometime needed.



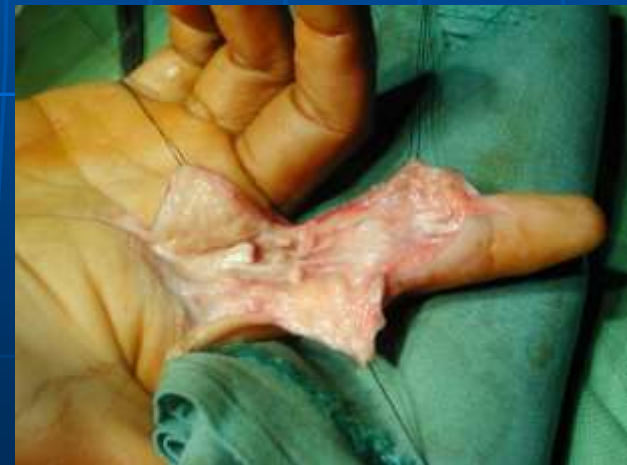
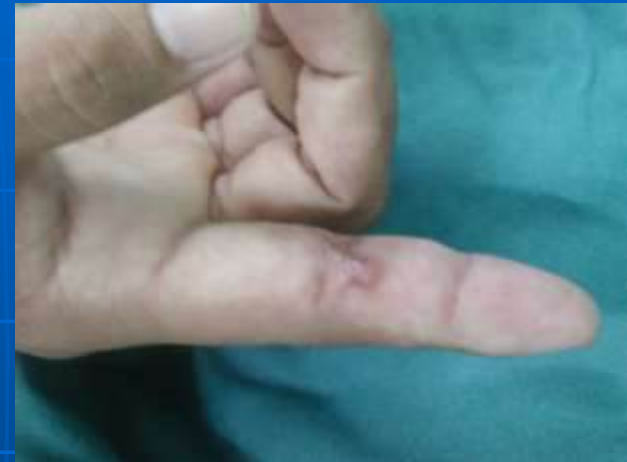
# GROWTH DISTURBANCE

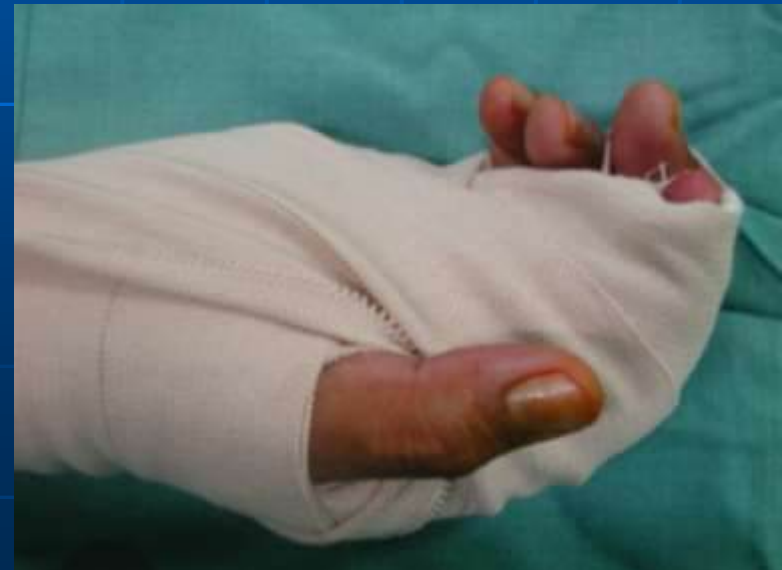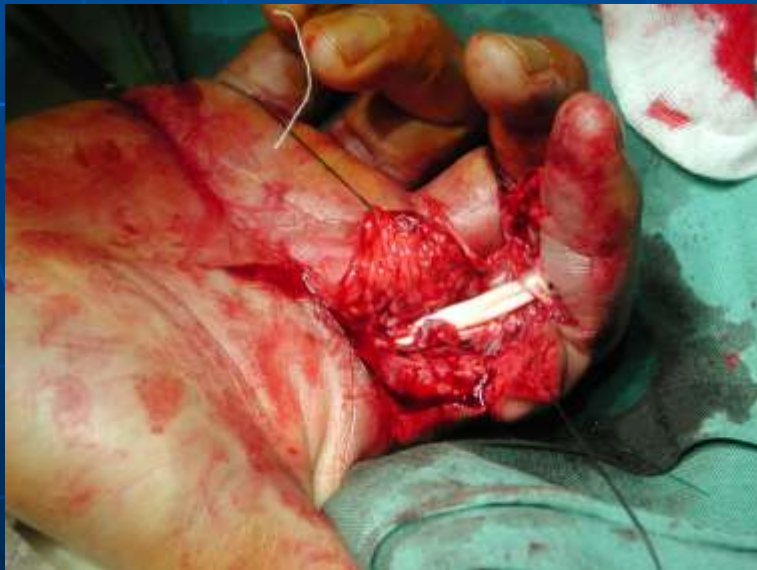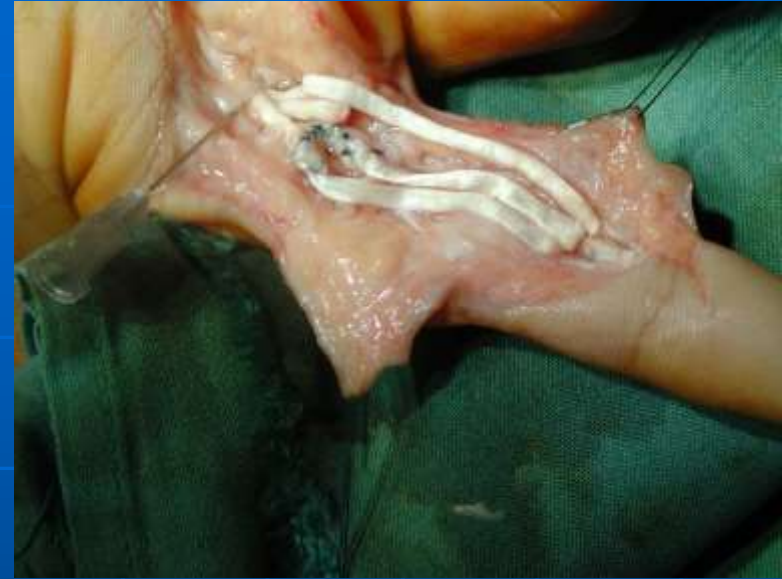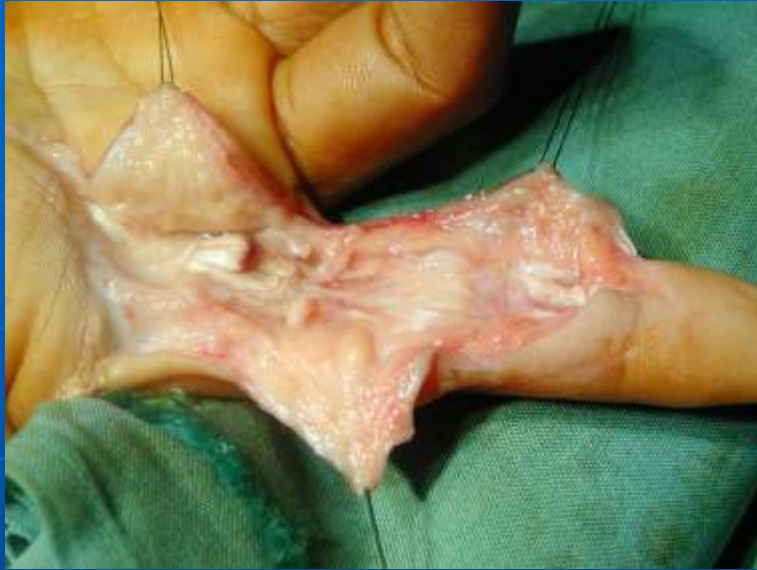- In children, damage to the physis may lead to abnormal or arrested growth.
- Fractures that split the epiphysis inevitably traverse the growing portion of the physis, and so further growth may be asymmetrical and the bone end characteristically angulated.

# TENDON LESIONS

- Rupture of the extensor pollicis tendon may occur 6 – 12 weeks after a fracture of the lower radius.
- Direct suture is seldom possible and the resulting disability is treated by transferring the extensor indicis proprius tendon to the distal stump of the ruptured thumb tendon.

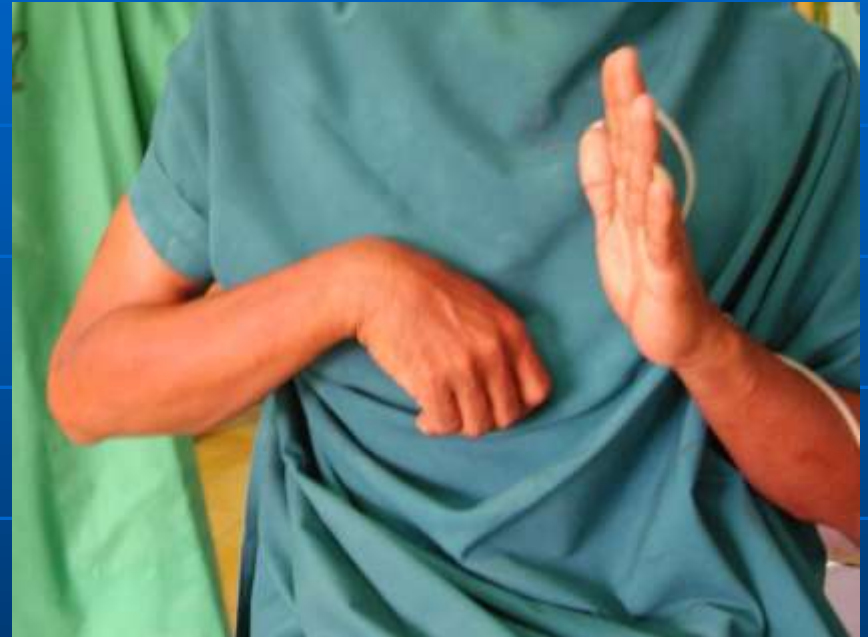

# TENDON LESIONS



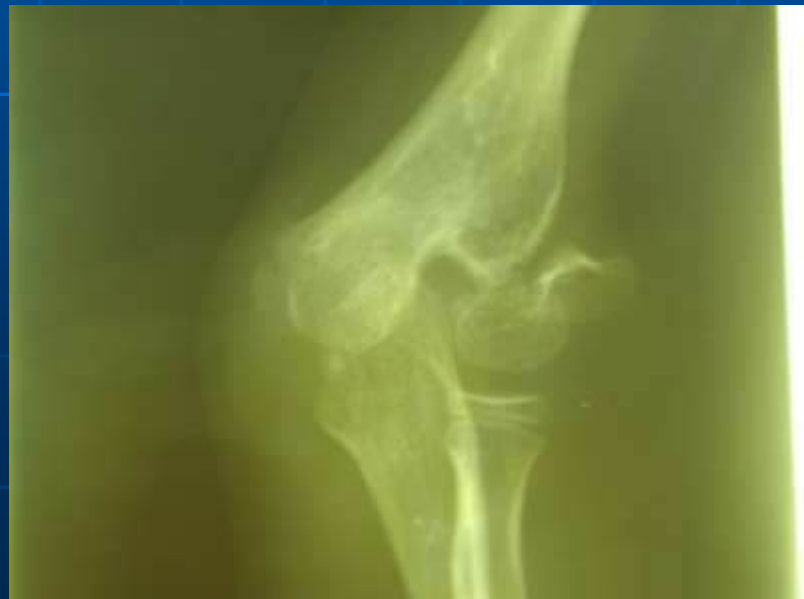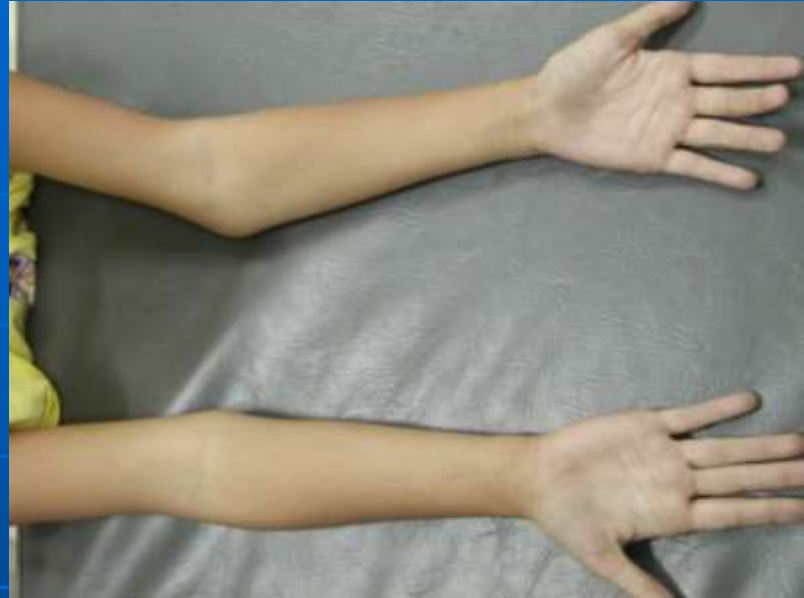# NERVE COMPRESSION

- Peroneal nerve may damage if an elderly patient lies with the leg in full external rotation.
- Radial palsy may follow the faulty use of crutches.



# NERVE COMPRESSION

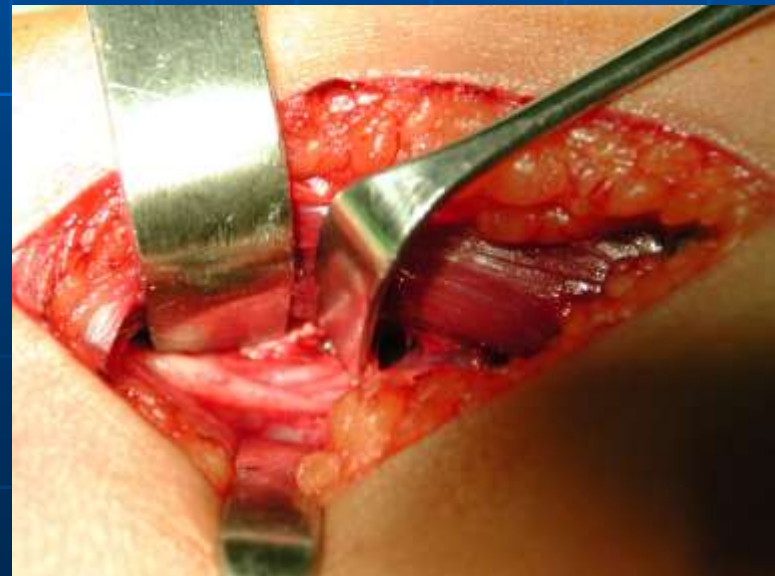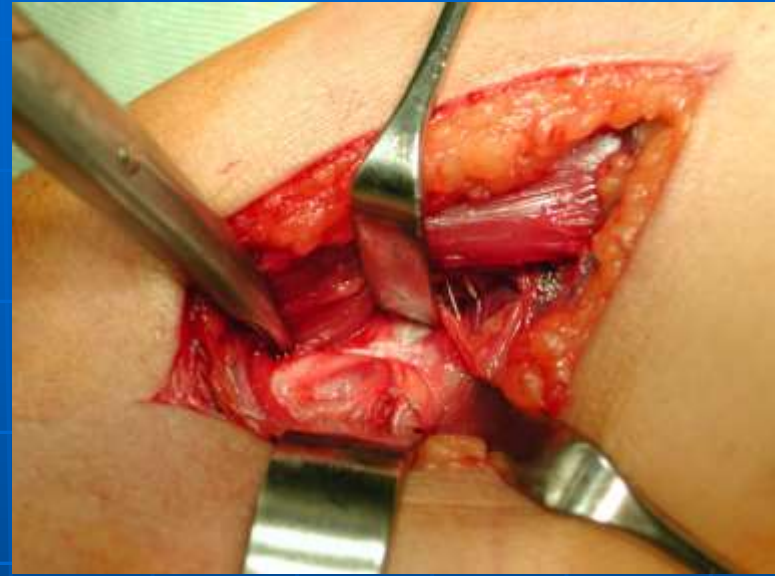
- Bone or joint deformity may result in local nerve entrapment with typical feature such as numbness or paraesthesia, loss of power and muscle wasting in the distribution of the affected nerve.
- Common site are :
  1. the ulnar nerve, due to a valgus elbow following an un-united lateral condyle fracture.
  2. the median nerve, following injuries around the wrist.
  3. the posterior tibial nerve, following fractures around the ankle.



# TREATMENT – NERVE COMPRESSION

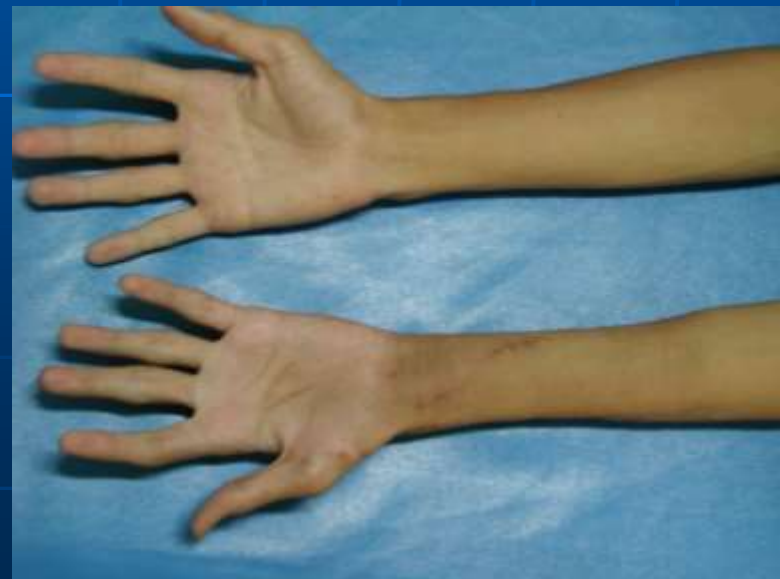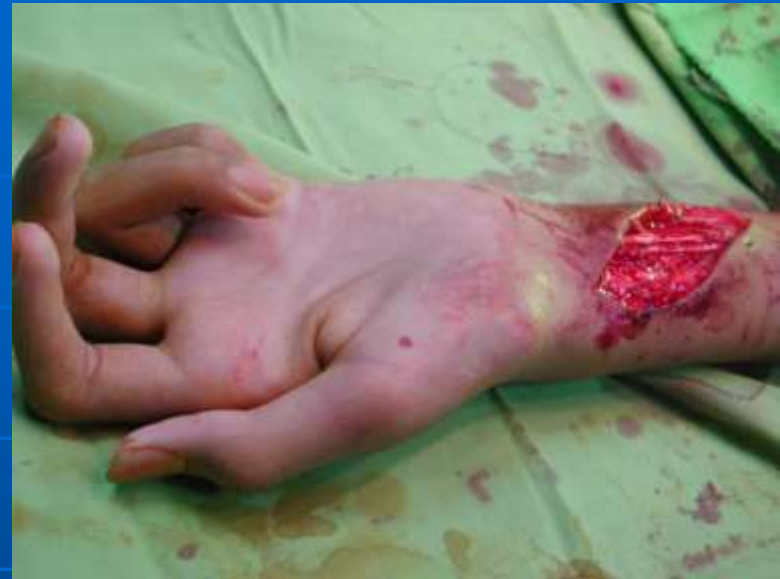Treatment is by early decompression of the nerve.

In the case of the ulnar nerve this may require anterior transposition.



# MUSCLE CONTRACTURE

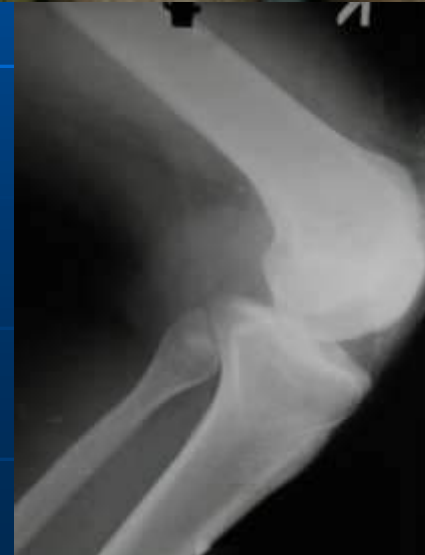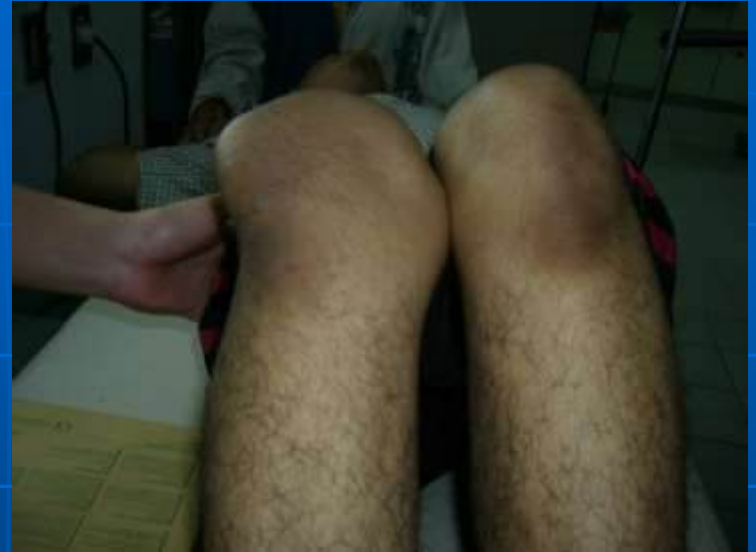- Following arterial injury or a compartment syndrome, the patient may develop ischaemic contractures of the affected muscles (*Volkmann's ischaemic contracture*).
- The sites most commonly affected are the forearm and hand, the leg and the foot.



# JOINT INSTABILITY

- Following injury a joint may give way. Causes include :
  1. Ligamentous laxity
  2. Muscle weakness
  3. Bone loss

Injury may also lead to recurrent dislocation. The commonest sites are the shoulder and the patella.

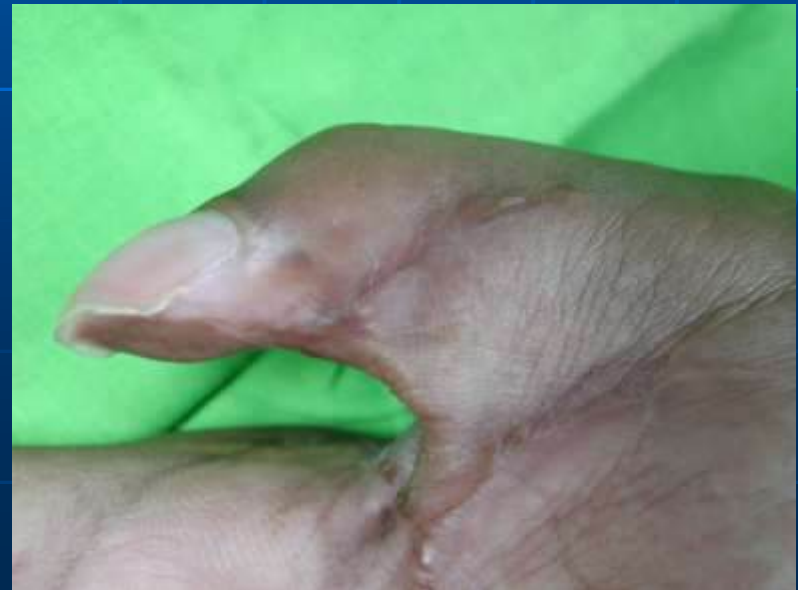
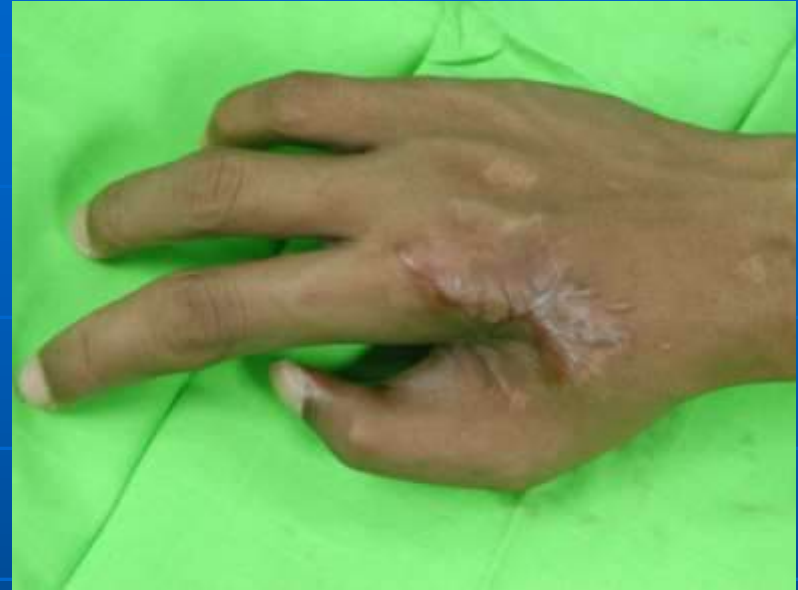


# JOINT STIFFNESS

- A haemarthrosis forms and leads to synovial adhesions.
- Oedema and fibrosis of the capsule, the ligaments and the muscles around the joint.
- Adhesion of the soft tissues to each other or to the underlying bone.

All these condition are made worse by prolonged immobilization.



# Treatment – Joint Stiffness

The best treatment is prevention:

- by exercises that keep the joints mobile from the outset.
- if the joint has to be splinted, make sure that it is held in the 'position of safety'.

# Treatment – Joint Stiffness

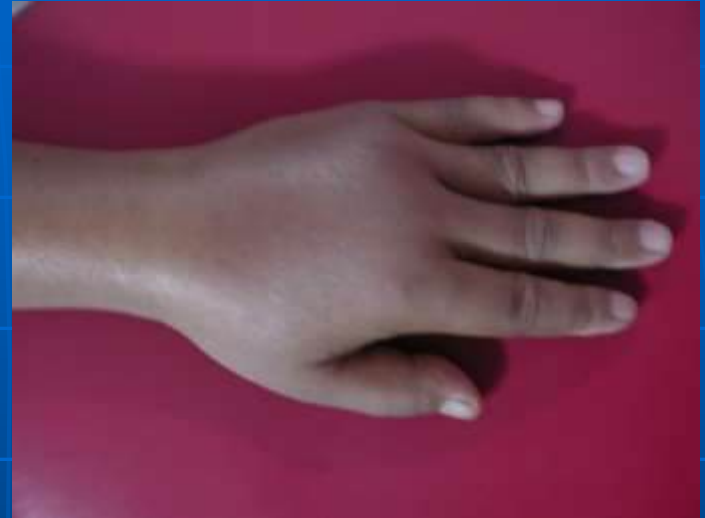- Joints that are already stiff take time to mobilize, but prolonged and patient physiotherapy can work wonders.
- If the situation is due to intra-articular adhesions, gentle manipulation under GA may free the joint sufficiently to permit a more pliant response to further exercise.
- Occasionally, adherent or contracted tissues need to be released by operation.

# ALGODYSTROPHY (COMPLEX REGIONAL PAIN SYNDROME)

- Sudeck, in 1900, describe a condition characterized by painful osteoporosis of the hand after fracture, it was called *Sudeck's atrophy*.
- Now recognized as the late stage of a post traumatic *reflex sympathetic dystrophy* (also known as *algodystrophy*)

# ALGODYSTROPHY (COMPLEX REGIONAL PAIN SYNDROME)

- The patient complains of continuous pain.
- Local swelling, redness and warmth as well as tenderness and moderate stiffness of the nearby joints.
- X-ray characteristically show patchy rarefaction of the bone.

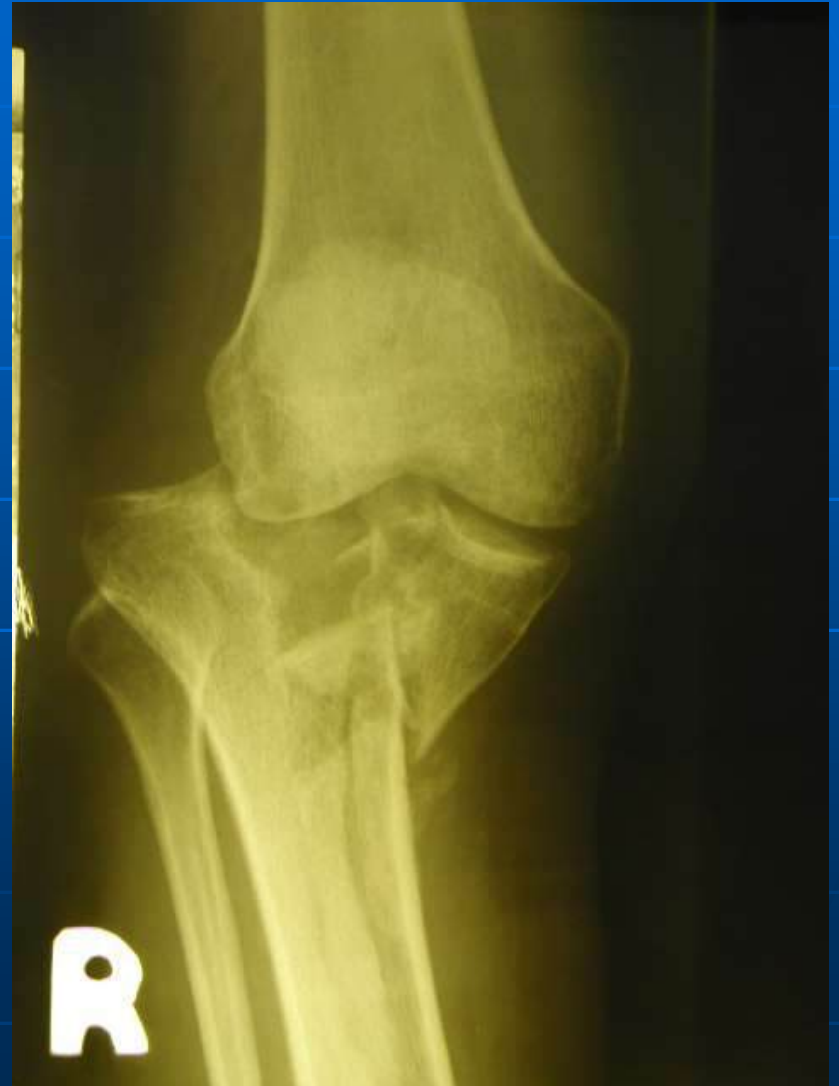

# Treatment

- In the early stage; anti-inflammatory drugs are helpful.
- If this does not produce improvement, amitriptyline may help to control the pain.
- Sympathetic block or sympatholytic drugs such as intravenous guanethidine have been advocated for this condition.
- Prolonged and dedicated physiotherapy will usually be needed.

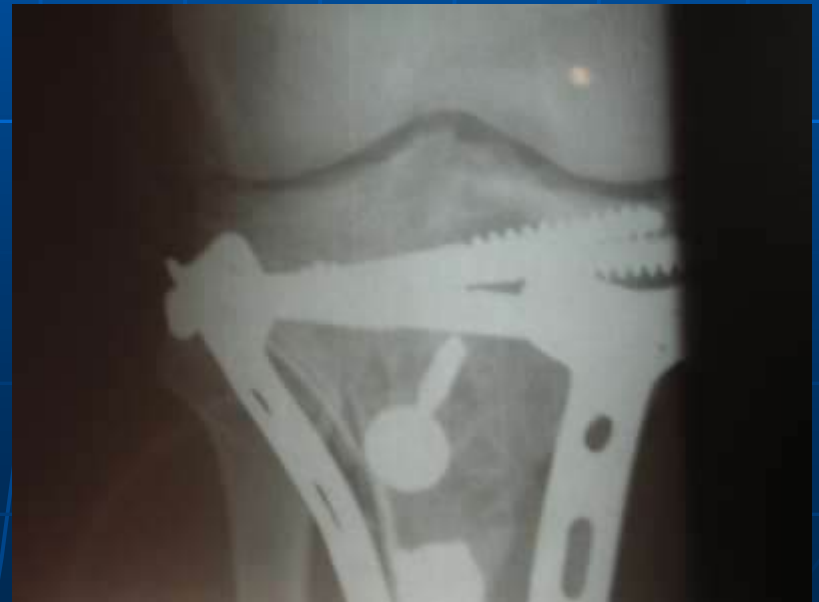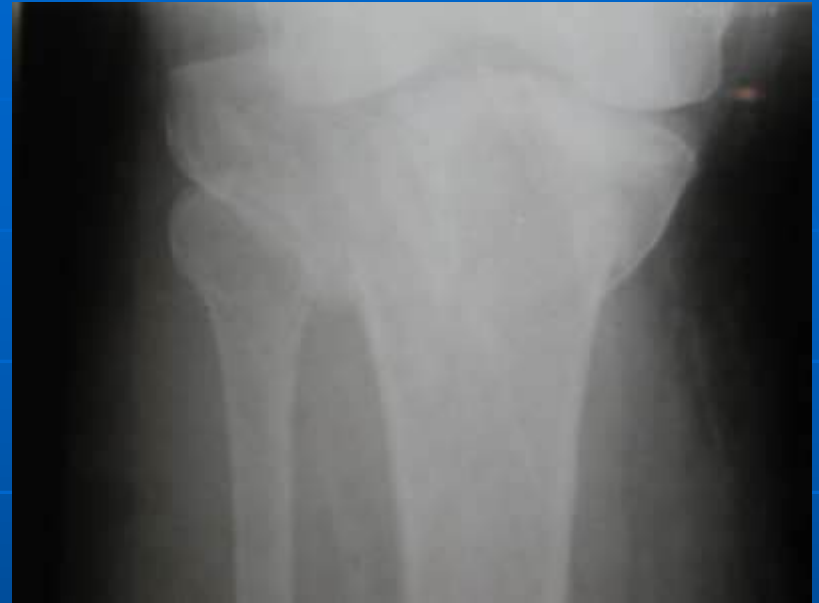# OSTEOARTHRITIS

- A fracture involving a joint may severely damage the articular cartilage and give rise to *post traumatic osteoarthritis* within a period of months
- Even if the cartilage heals, irregularity of the joint surface may cause localized stress and so predispose to *secondary osteoarthritis* years later



# OSTEOARTHRITIS

- Malunion of a metaphyseal fracture may radically alter the mechanics of a nearby joint and this, too, can give rise to secondary osteoarthritis.







Thank you