



MUSCULUS EXTREMITAS INFERIOR

Dr. Anung Putri Illahika, M.Si

Laboratorium Anatomi

FK UMM

TOPIK BAHASAN

REGIO EXTREMITAS INFERIOR



MUSCULUS PENYUSUN PER REGIO



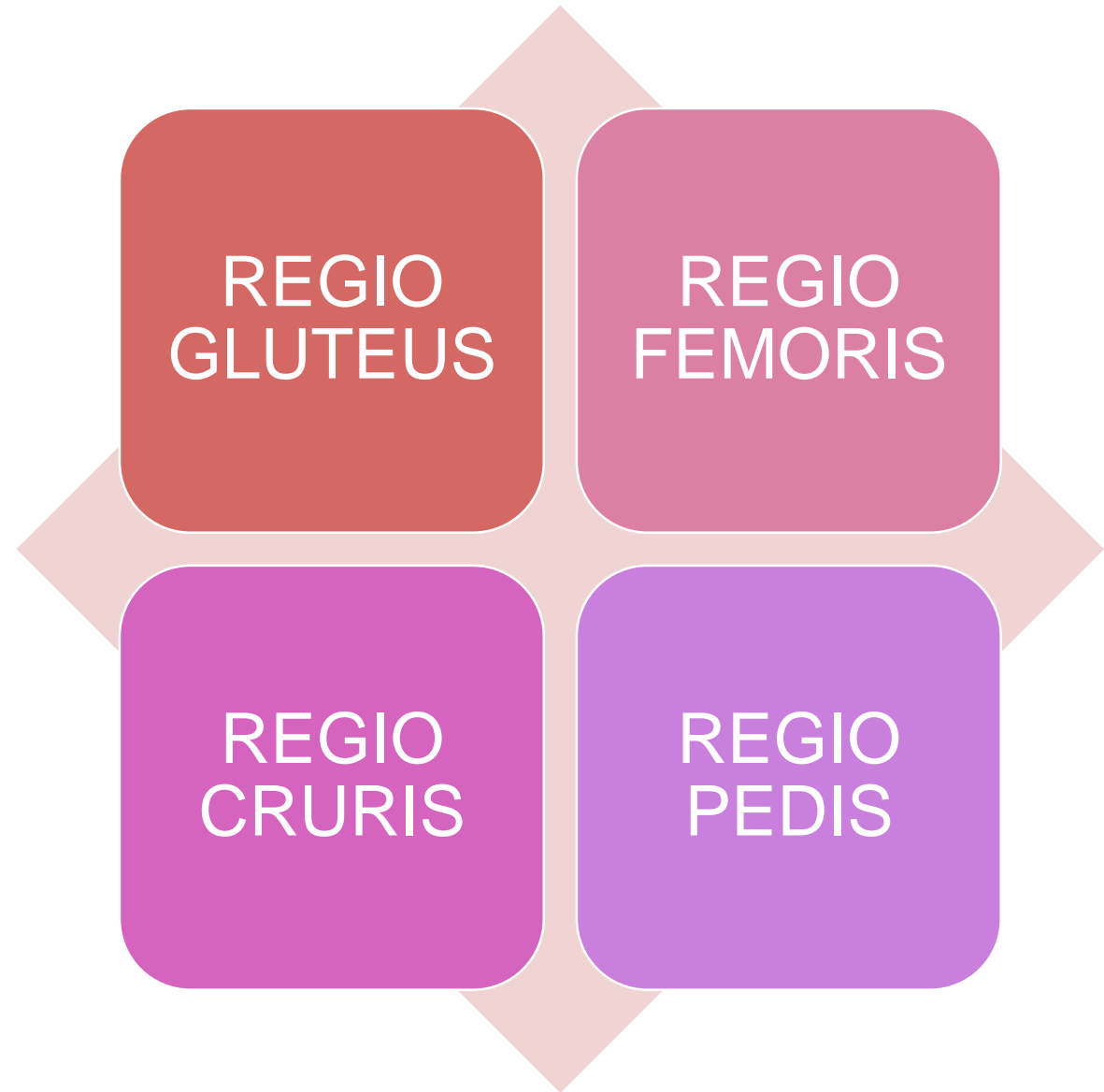
INNERVASI



STRUKTUR KHUSUS



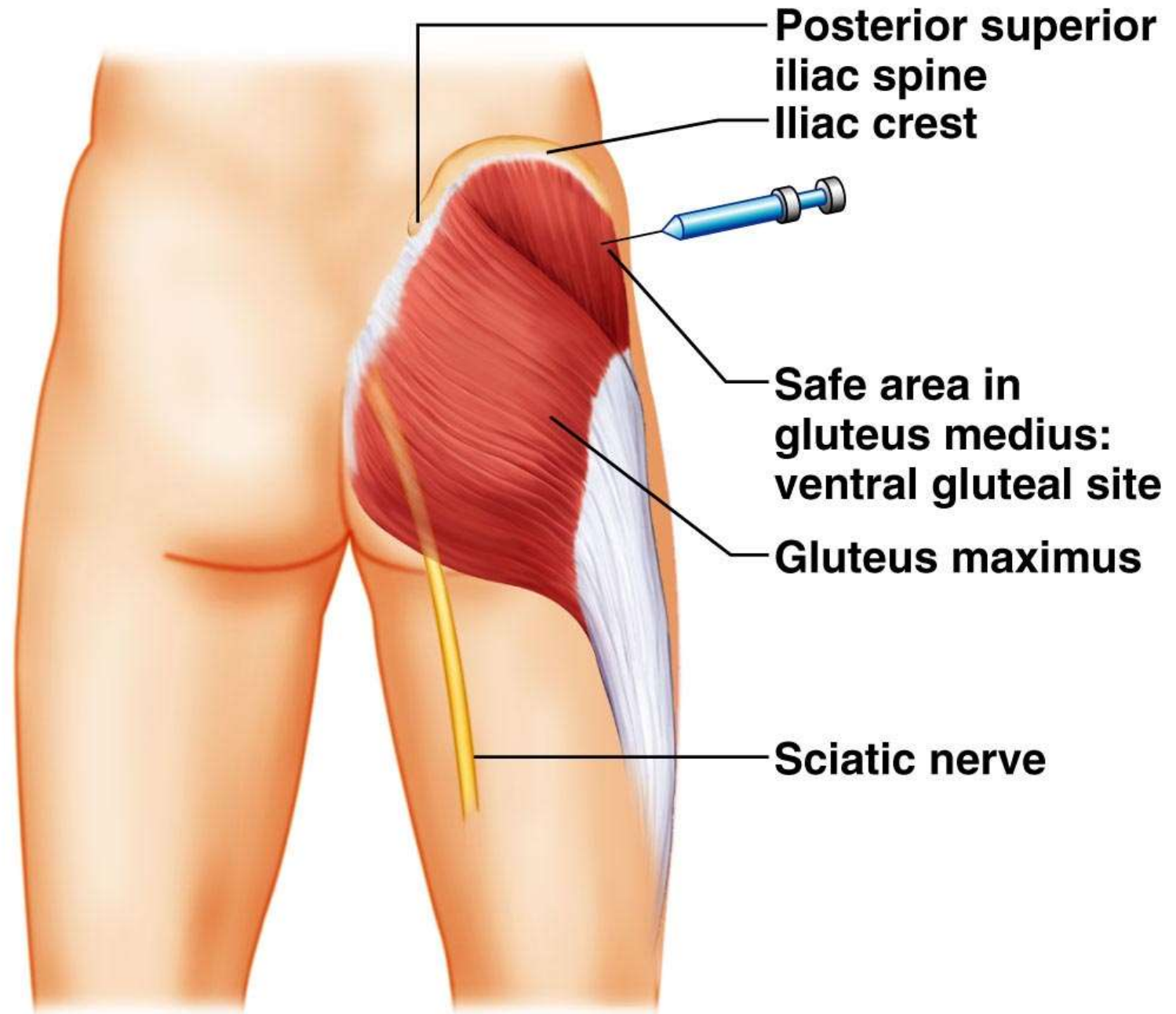
REGIO
EXTREMITAS
INFERIOR



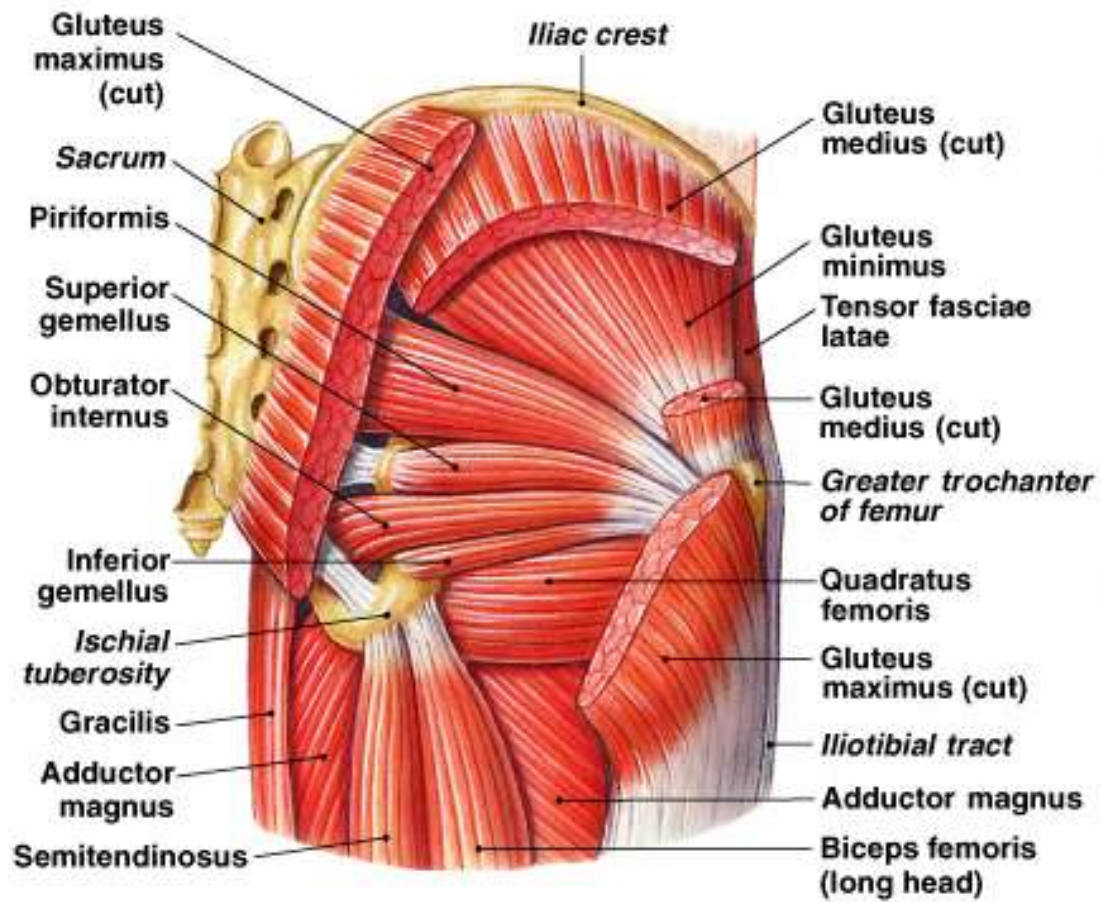
MUSCULUS PENYUSUN PER REGIO



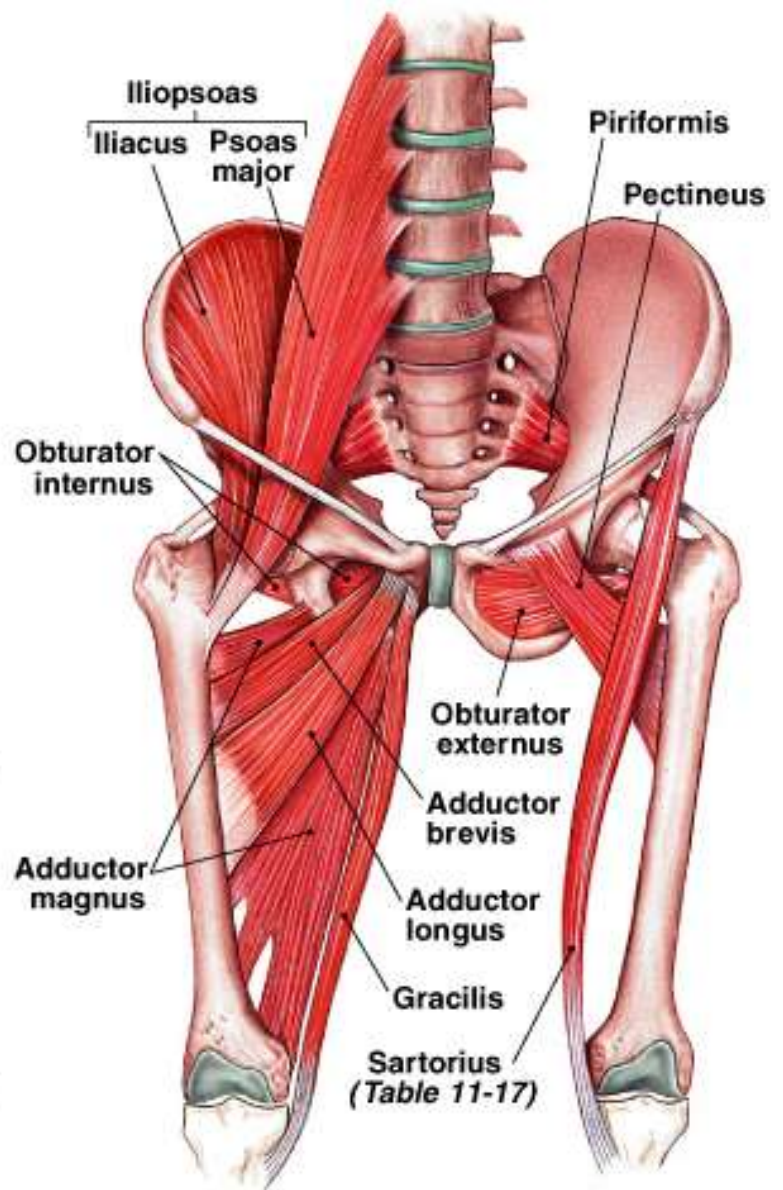
Lower Limb and Gluteal Region



(a)



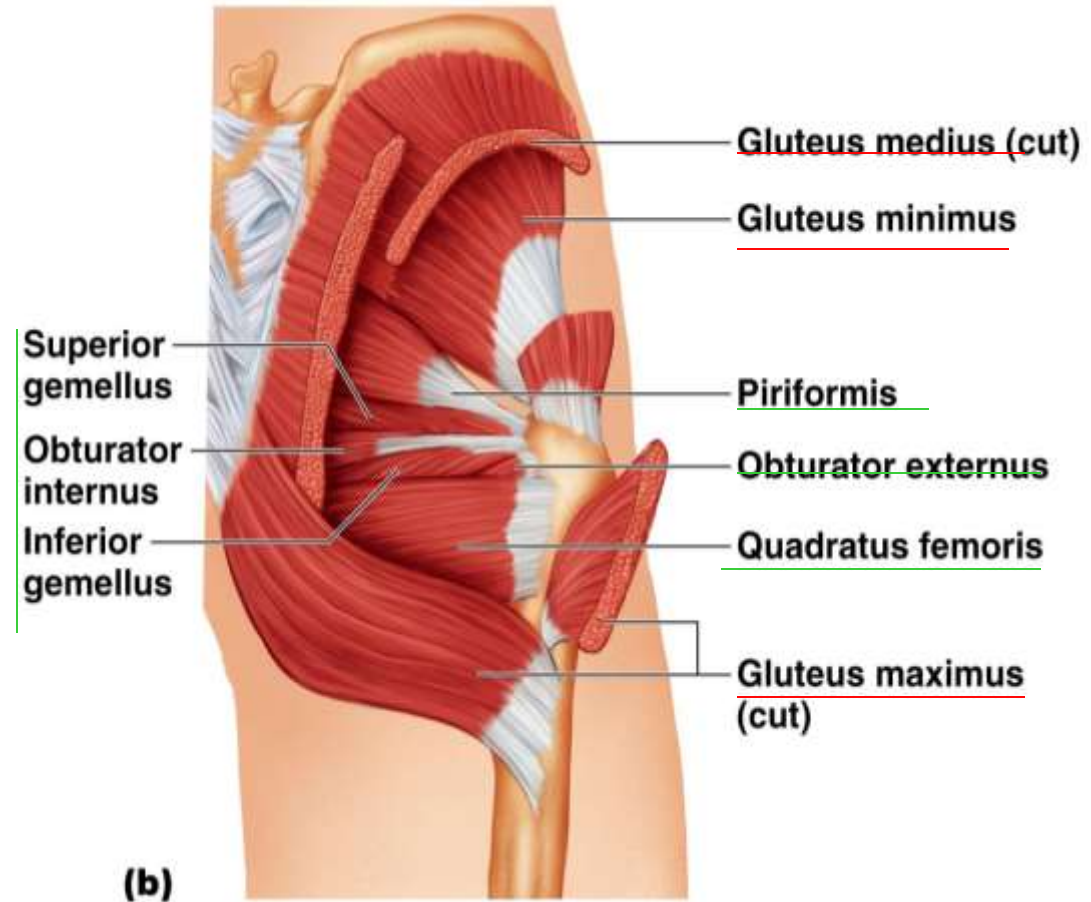
(c) Posterior view, deep muscles



(d) The iliopsoas muscle and the adductor group

Posterior Muscles

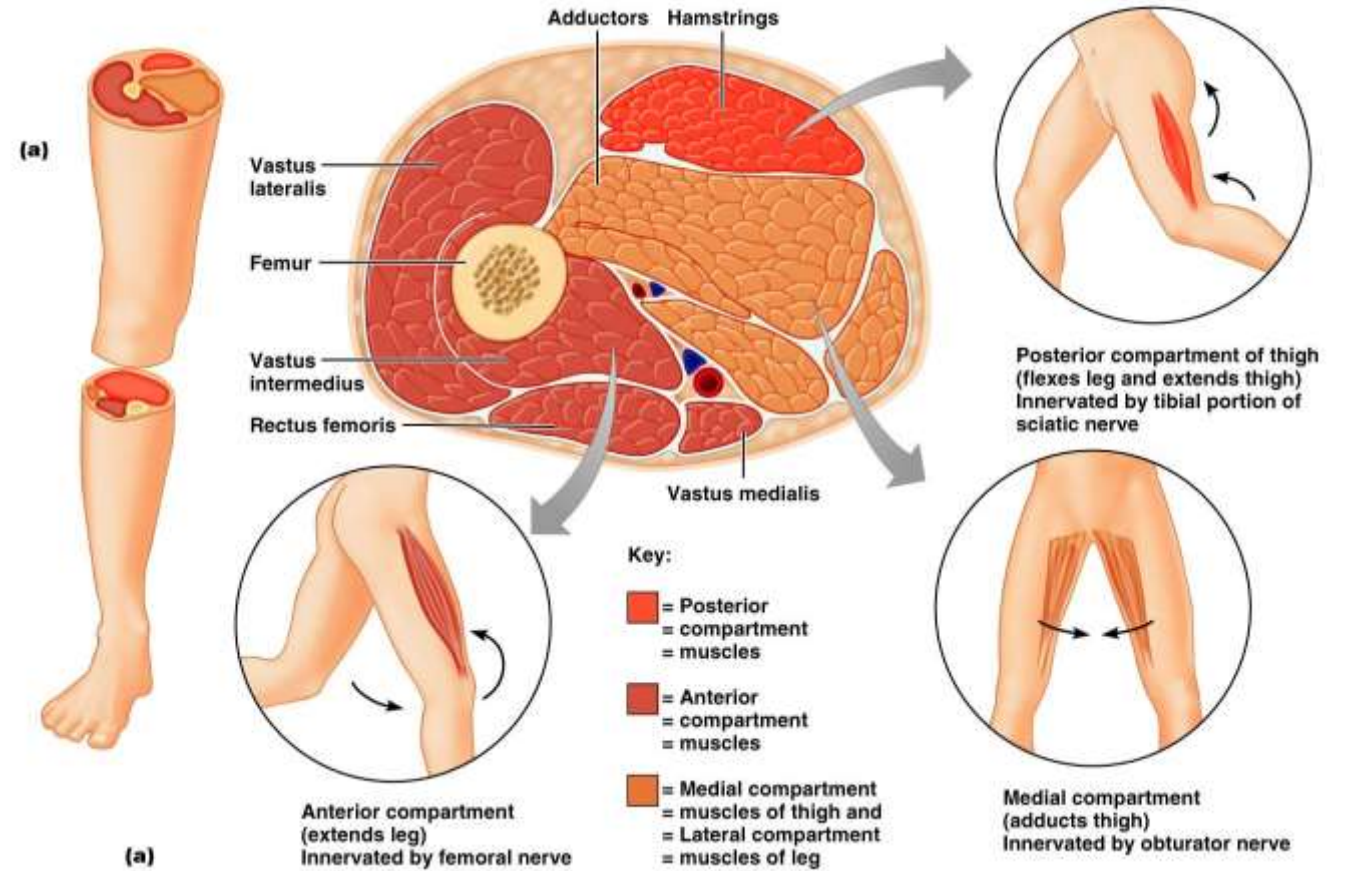
- Origin on pelvis or sacrum
 - **Gluteus maximus**
 - **Gluteus medius**
 - **Gluteus minimus**
- Lateral rotators
 - **Piriformis**
 - **Obturator externus**
 - **Obturator internus**
 - **Superior and inferior gemellus**
 - **Quadratus femoris**



REGIO FEMORIS

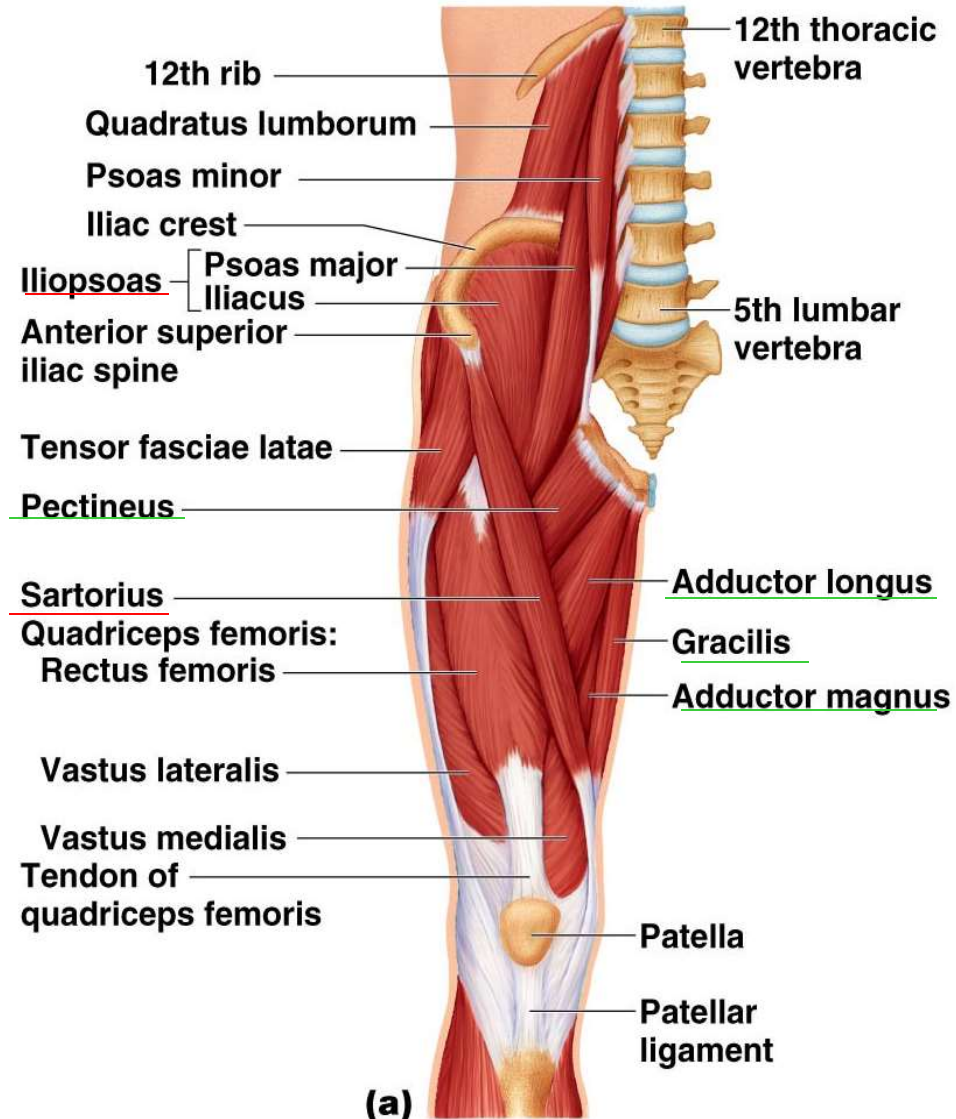
Muscle Compartments

- Sebutkan kompartemennya
- Sebutkan musculus penyusunnya
- Sebutkan innervasi nya



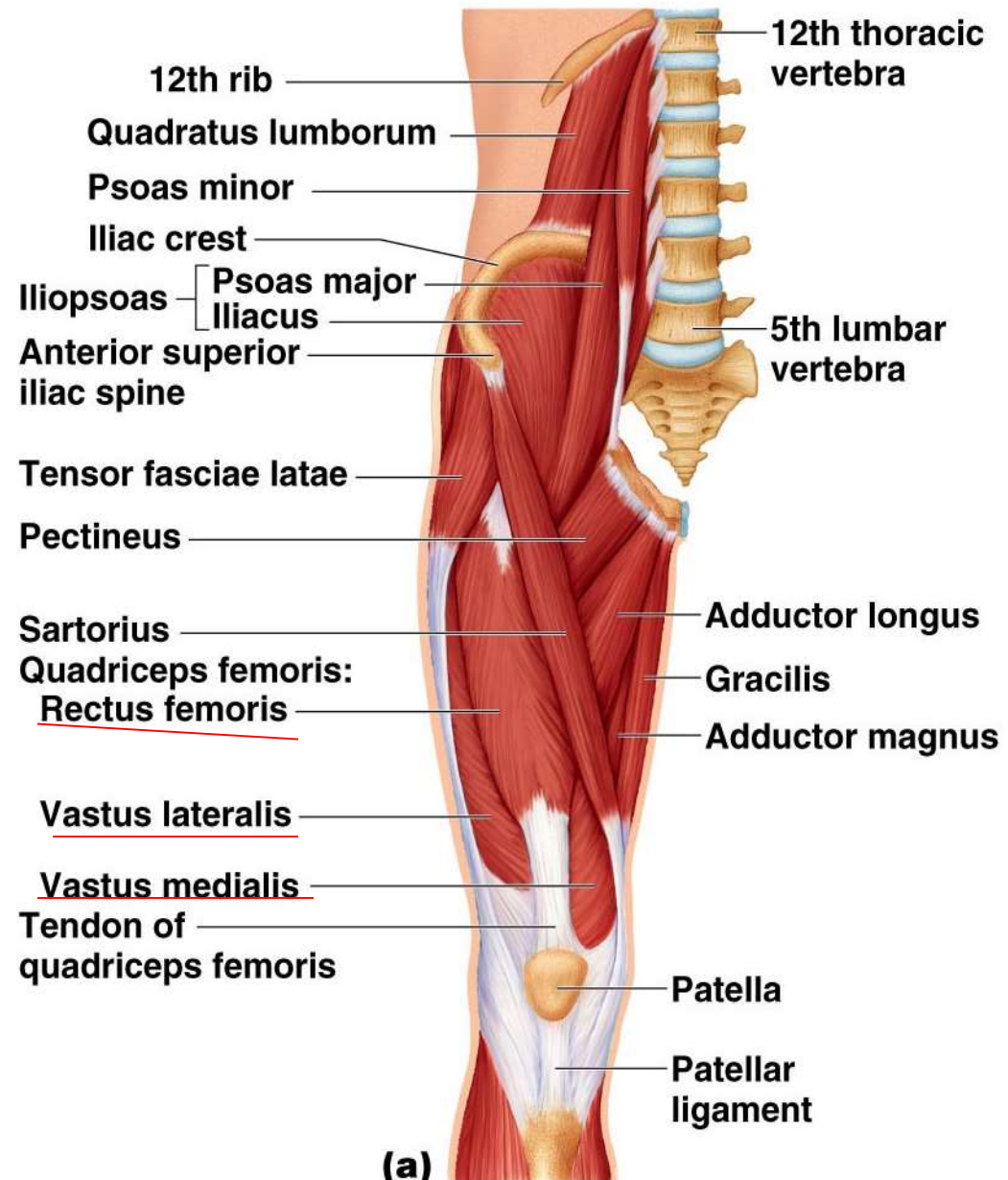
Anterior and Medial Muscles

- Origin on pelvis or vertebral column
 - Iliacus
 - Psoas major
 - Sartorius
- Muscles of the medial compartment
 - Adductor longus
 - Adductor brevis
 - Adductor magnus
 - Pectineus
 - Gracilis



Muscles of the Anterior Compartment of the Thigh

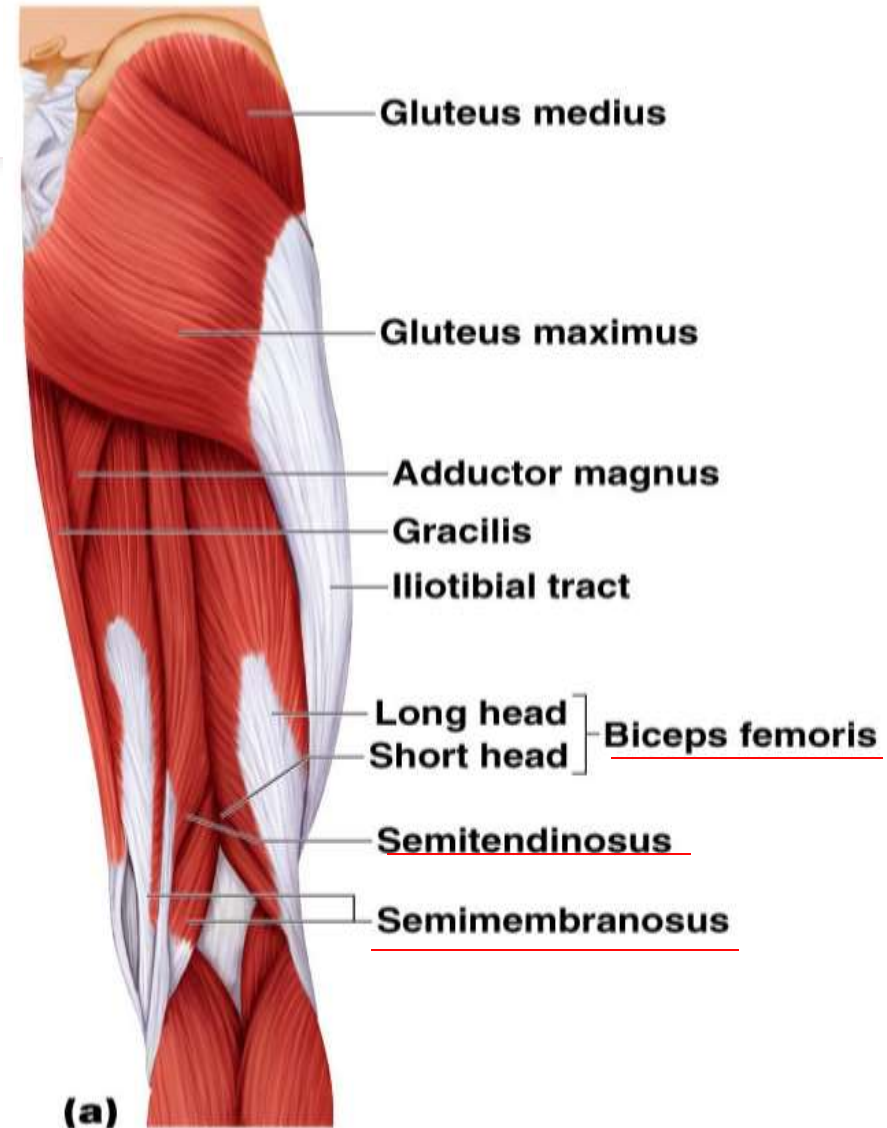
- **M. Sartorius**
- **Quadriceps femoris**
 - Has four separate heads
 - Powerful knee extensors
 - **Rectus femoris**
 - **Vastus lateralis**
 - **Vastus medialis**
 - **Vastus intermedius**
- **Tensor fasciae latae**

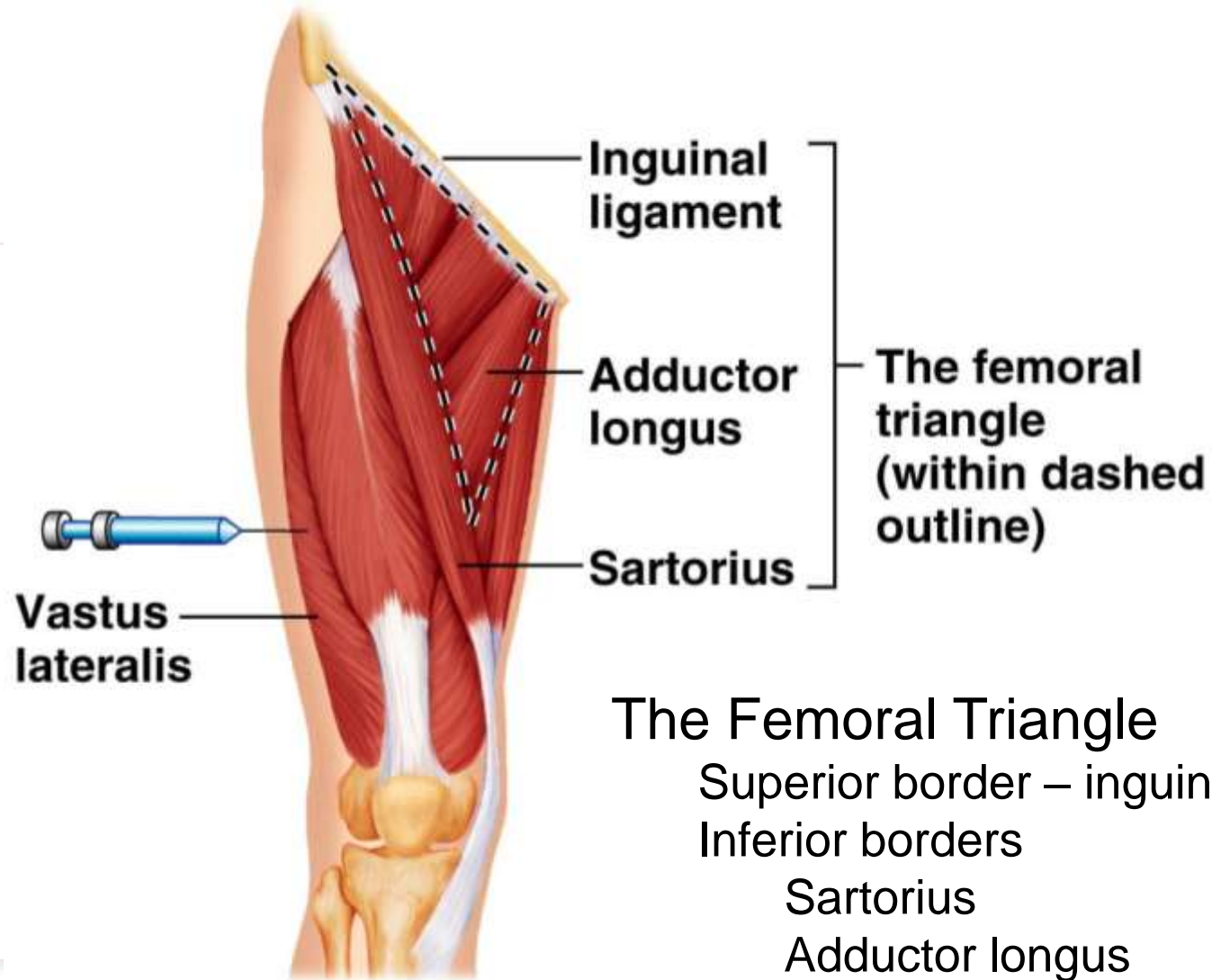


Muscles of the Posterior Compartment of the Thigh

Hamstrings

- Biceps femoris
- Semitendinosus
- Semimembranosus





The Femoral Triangle

Superior border – inguinal ligament

Inferior borders

Sartorius

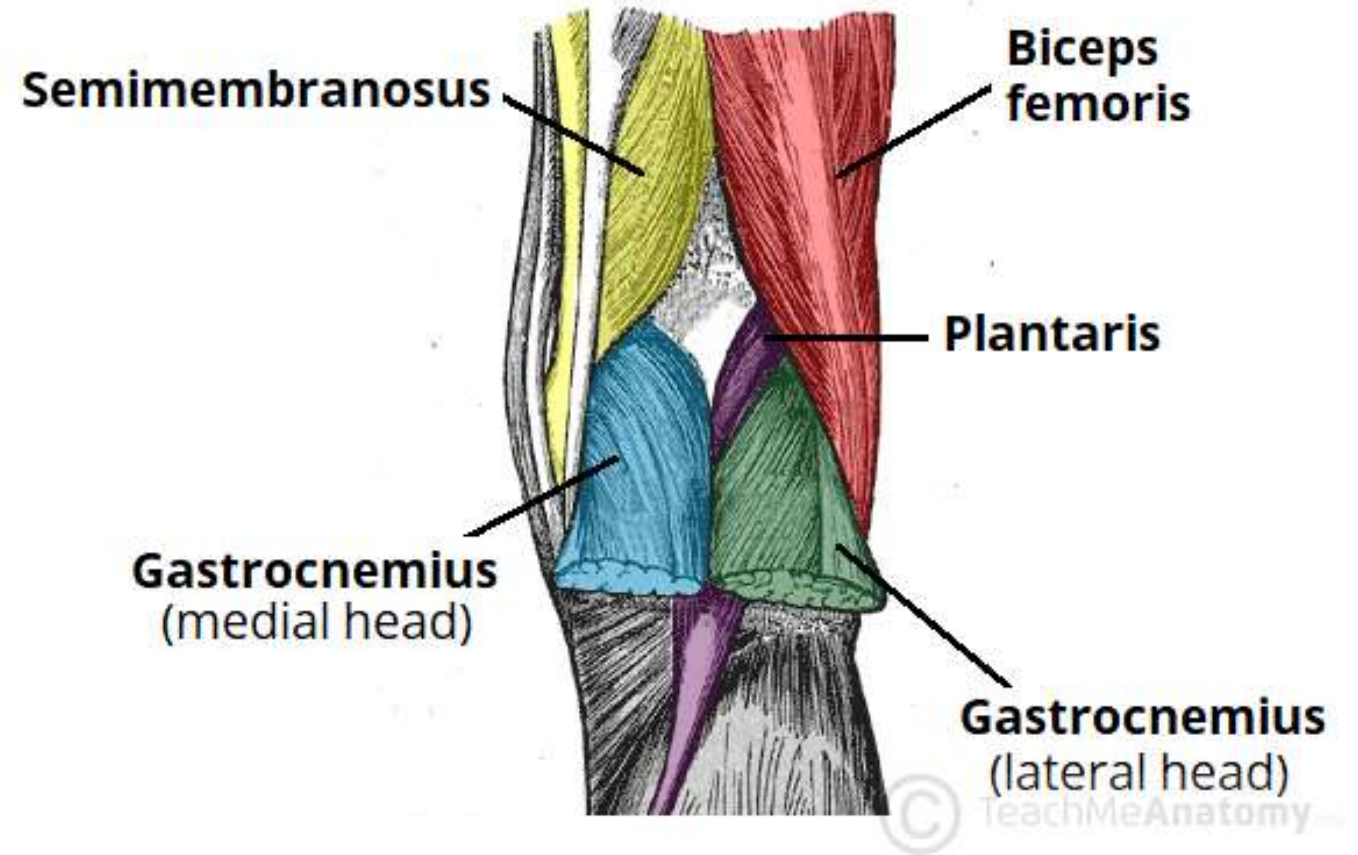
Adductor longus

(b)

Vastus lateralis –
injection site

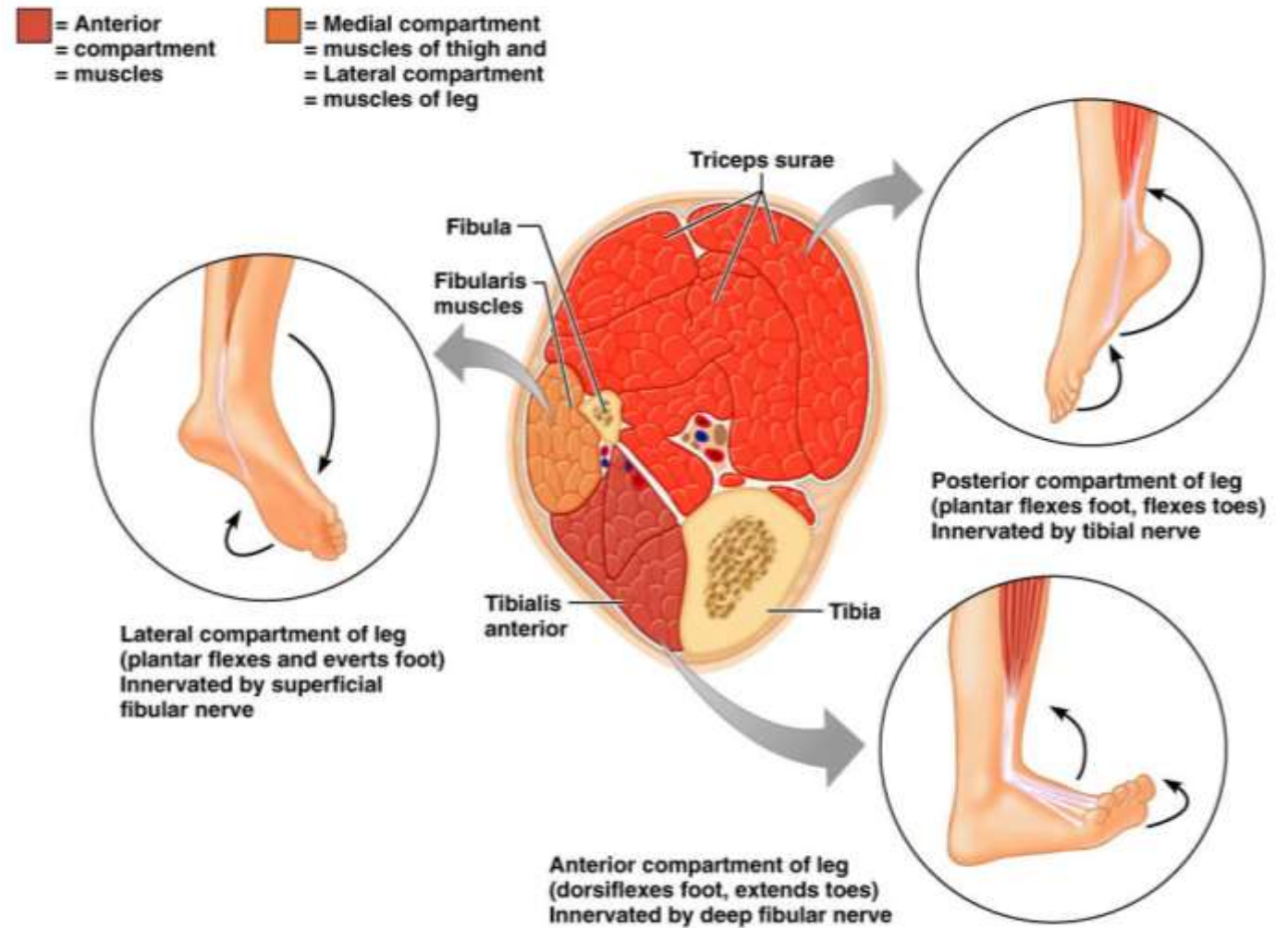
FOSSA POPLITEA

(sebutkan struktur
pengisinya)



REGIO CRURIS

- Muscle Compartments
 - ❖ Sebutkan kompartemennya
 - ❖ Sebutkan musculus penyusunnya
 - ❖ Sebutkan innervasi nya



Muscles of the Anterior Compartment



Tibialis anterior



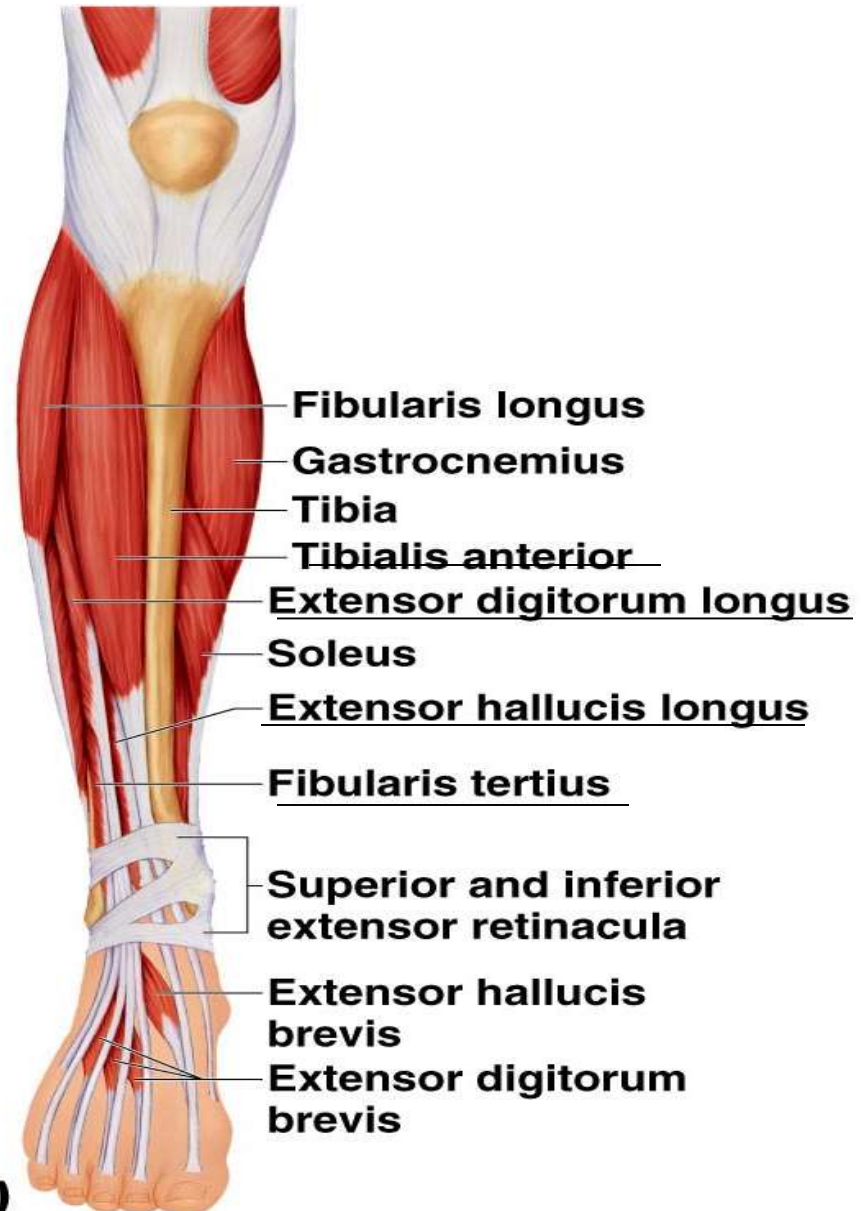
Extensor digitorum longus



Fibularis (peroneus) tertius



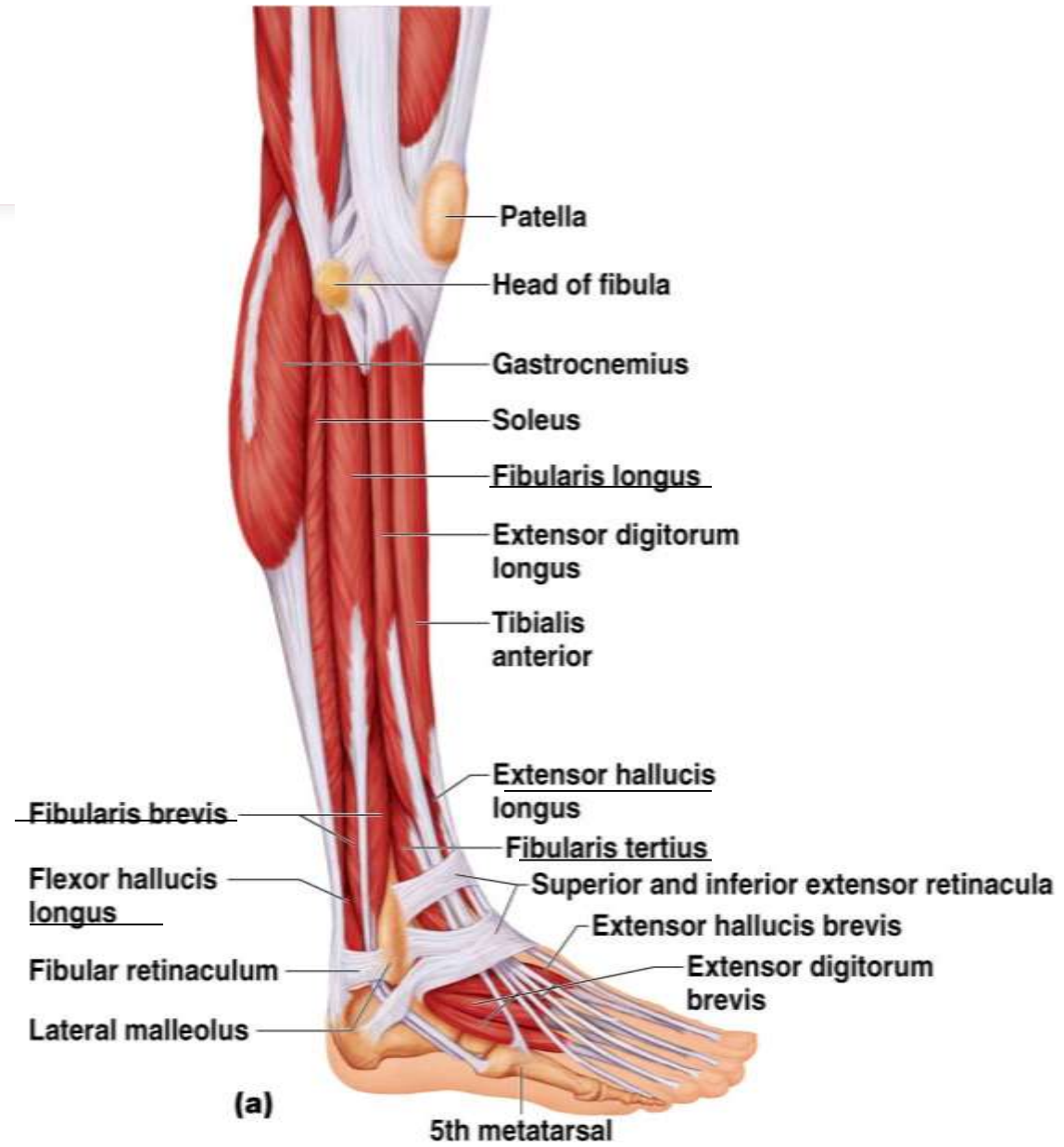
Extensor hallucis longus



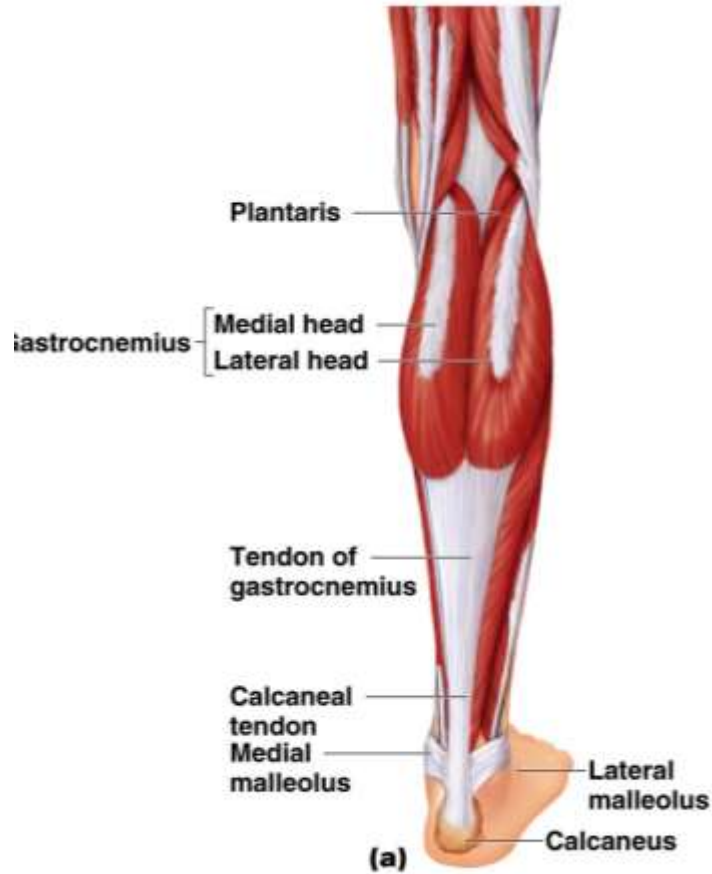
Khas

Muscles of the Lateral Compartment

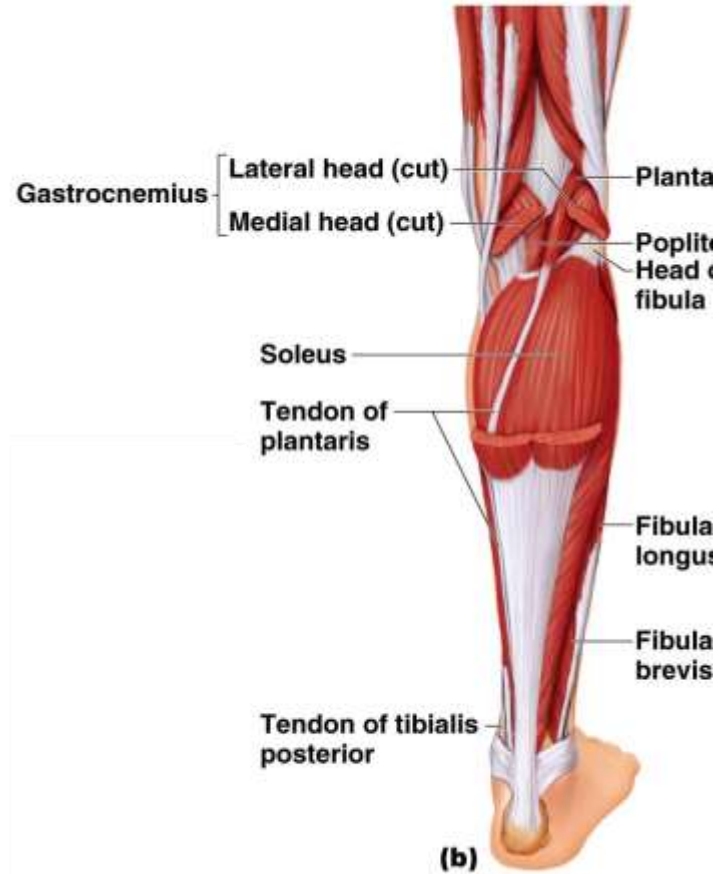
- Fibularis (peroneus) longus
- Fibularis (peroneus) brevis
- Flexor hallucis longus
- Extensor hallucis longus
- Fibularis tertius



Muscles of the Posterior Compartment



Copyright © 2008 Pearson Education, Inc., publishing as Benjamin Cummings

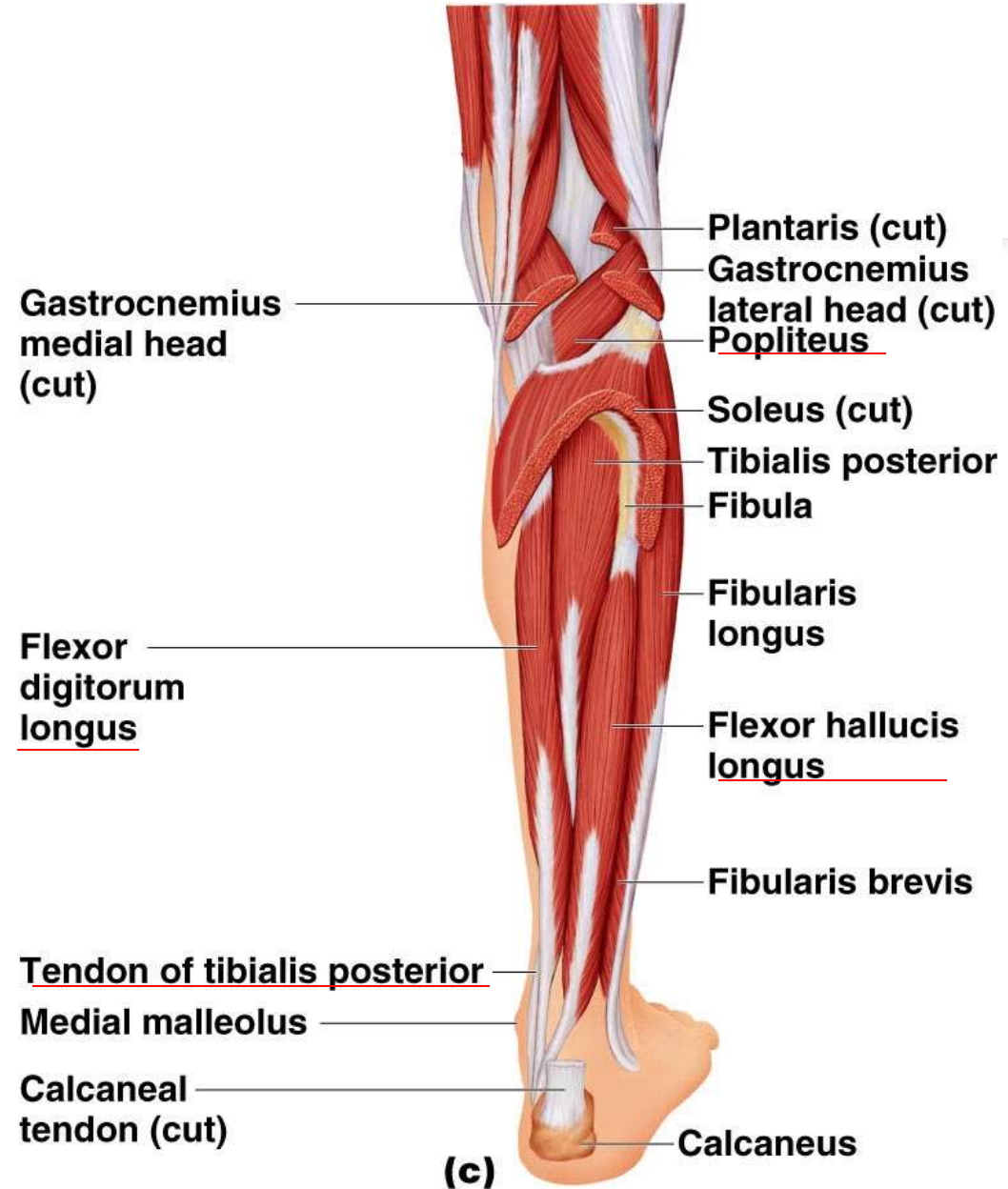


Copyright © 2008 Pearson Education, Inc., publishing as Benjamin Cummings

- Superficial muscles
 - Triceps surae
 - Gastrocnemius
 - Soleus
 - Plantaris

Muscles of the Posterior Compartment

- Deep muscles
 - Popliteus
 - Flexor digitorum longus
 - Flexor hallucis longus
 - Tibialis posterior

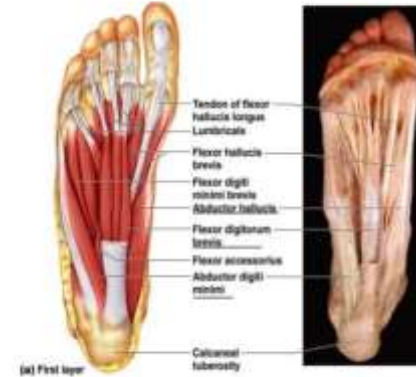


REGIO PEDIS

- Layer 1
- Layer 2
- Layer 3
- Layer 4

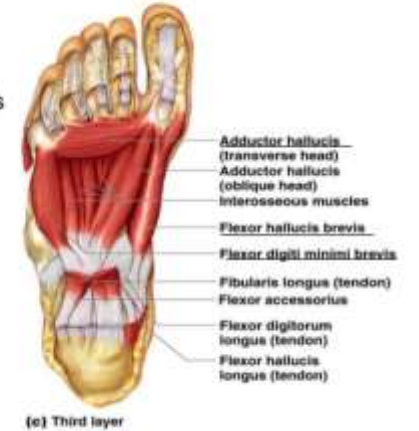Musculus Intrinsik Telapak Kaki

- First layer
 - Flexor digitorum brevis
 - Abductor hallucis
 - Abductor digiti minimi



Musculus Intrinsik Telapak Kaki

- Third layer
 - Flexor hallucis brevis
 - Adductor hallucis
 - Flexor digiti minimi brevis



Musculus Intrinsik Telapak Kaki

- Second layer
 - Flexor accessorius
 - Lumbricals

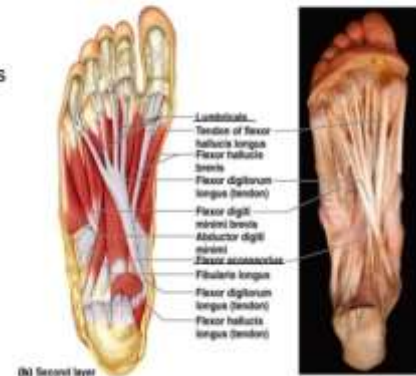
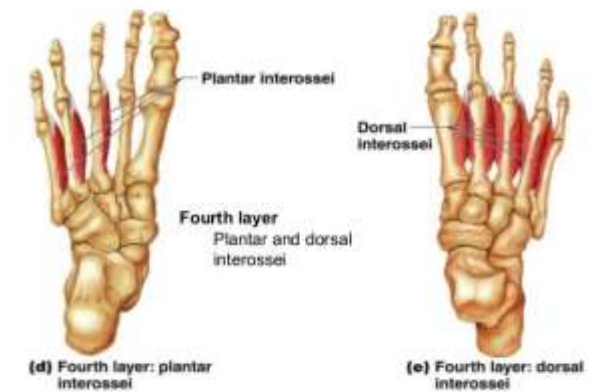


Figure 11.25b

Musculus Intrinsik Telapak Kaki



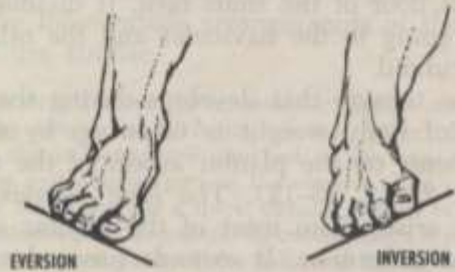
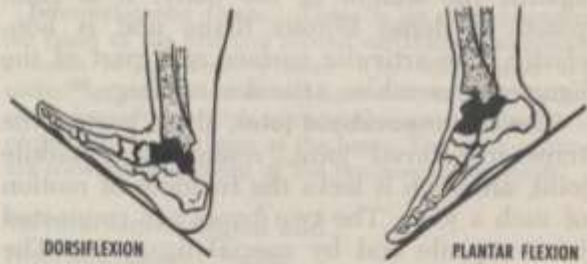
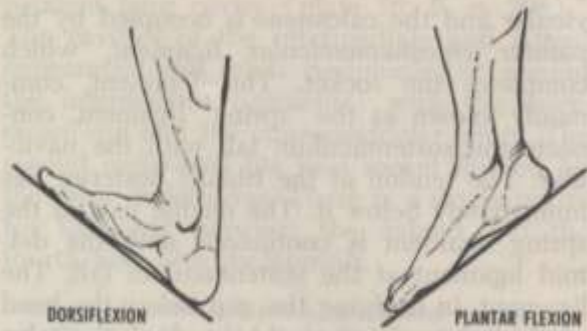


Fig. 23-10. Movements of the foot and ankle. Dorsiflexion and plantar flexion are shown as in walking up and down hill. Movement occurs at the ankle joint. Eversion and inversion are shown as in standing sideways on a hill. Movement occurs at tarsal joints, the talus remaining fixed. Based on S. Mollier.^{10*}

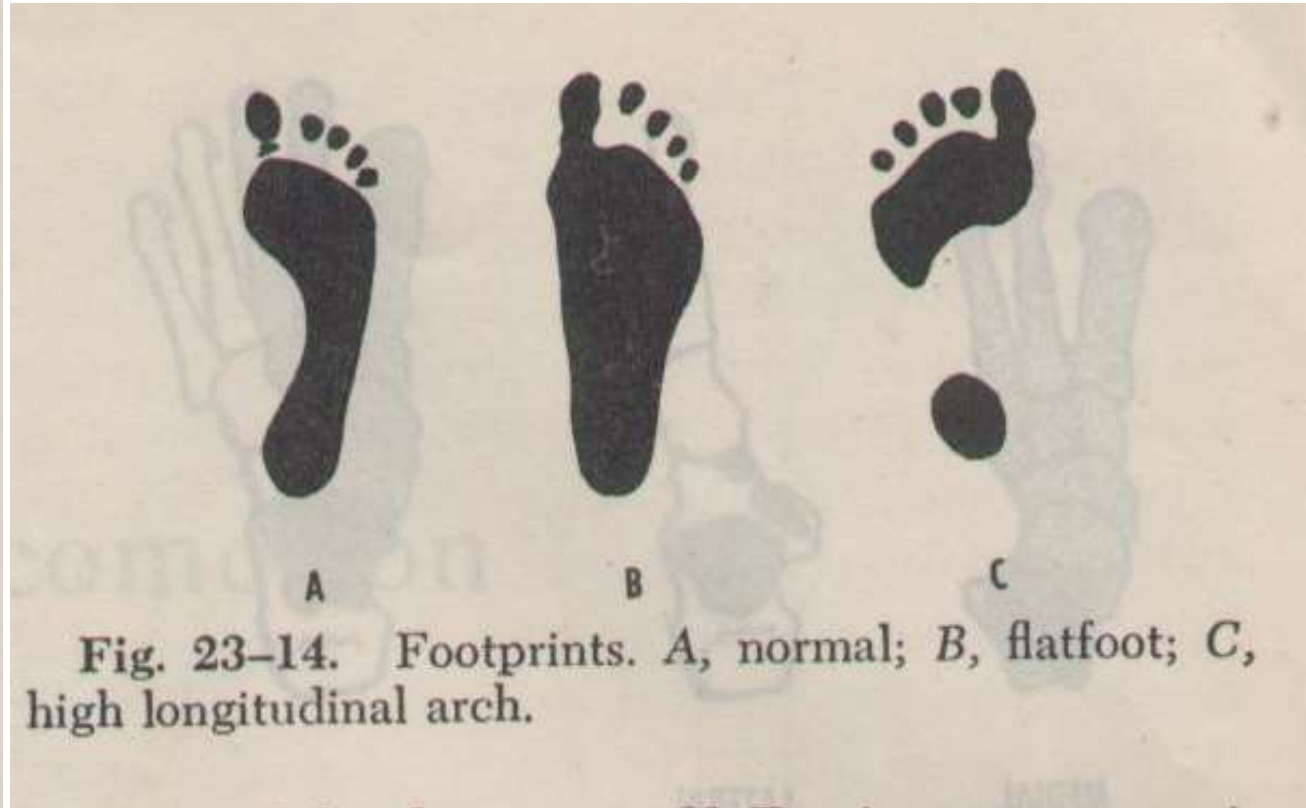


Fig. 23-14. Footprints. A, normal; B, flatfoot; C, high longitudinal arch.

The Lumbar Plexus

Lumbar plexus

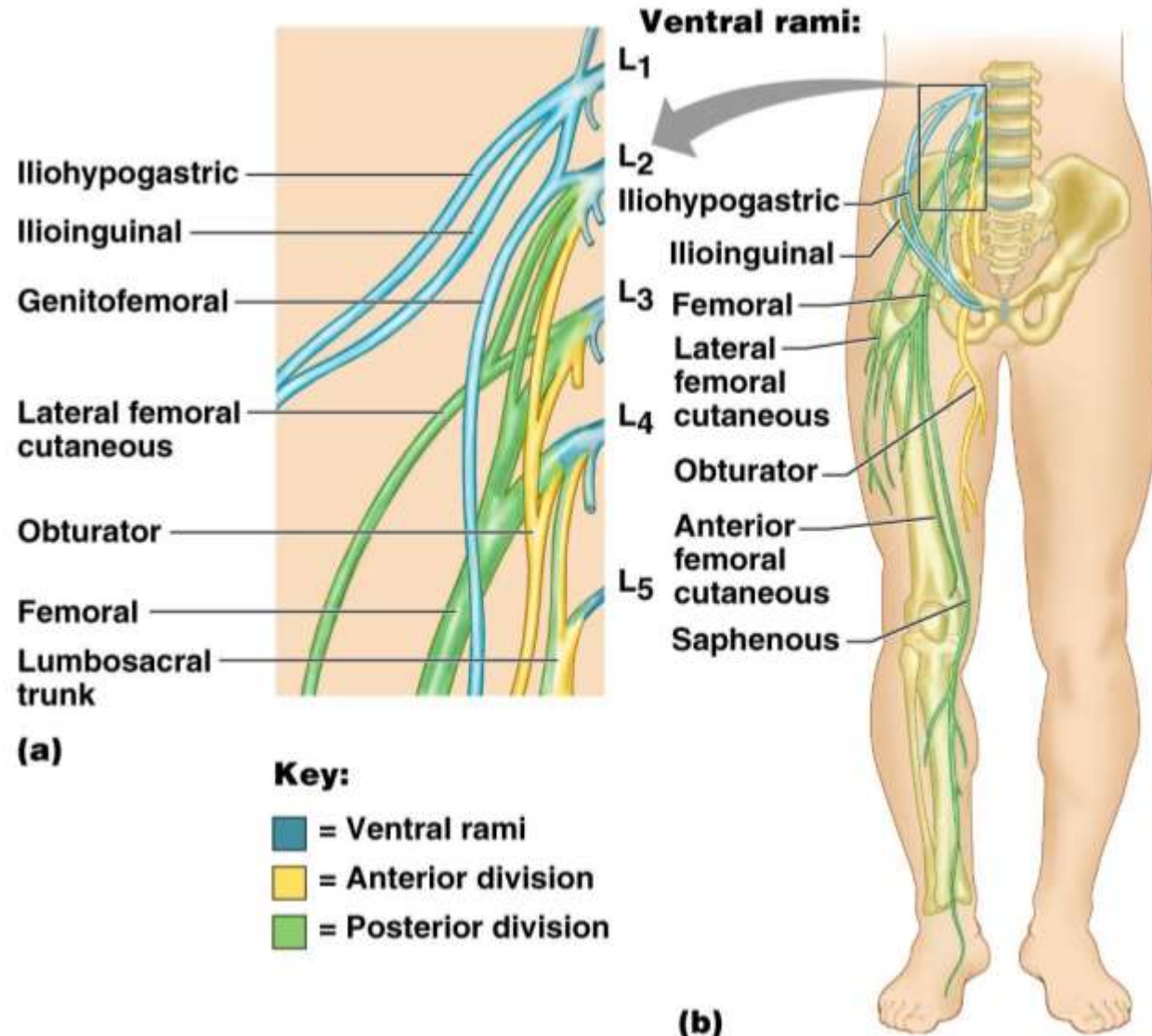
Arises from L1– L4

Smaller branches innervate the posterior abdominal wall and psoas muscle

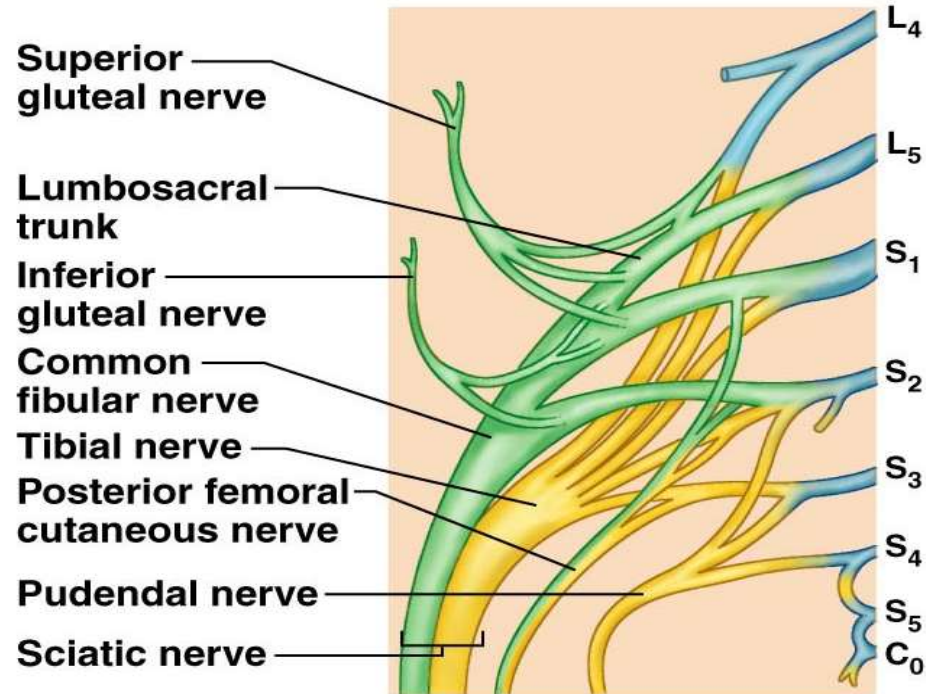
Main branches innervate the anterior thigh

Femoral nerve – innervates anterior thigh muscles

Obturator nerve – innervates adductor muscles



The Sacral Plexus

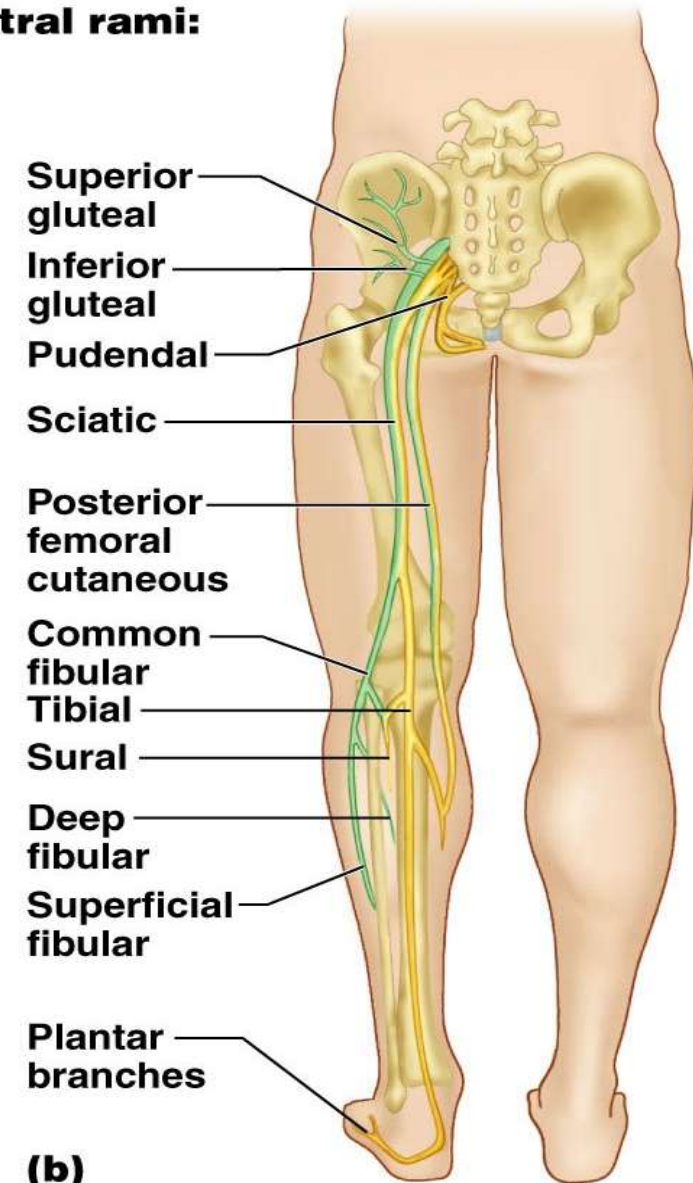


Key:

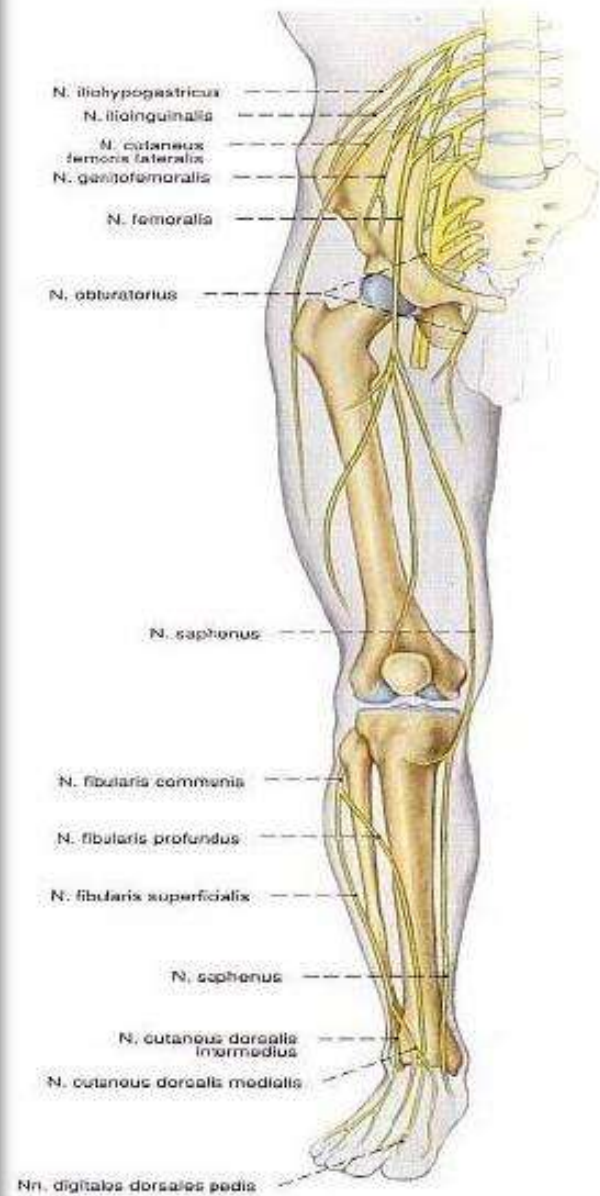- = Ventral rami
- = Anterior divisions
- = Posterior divisions

(a)

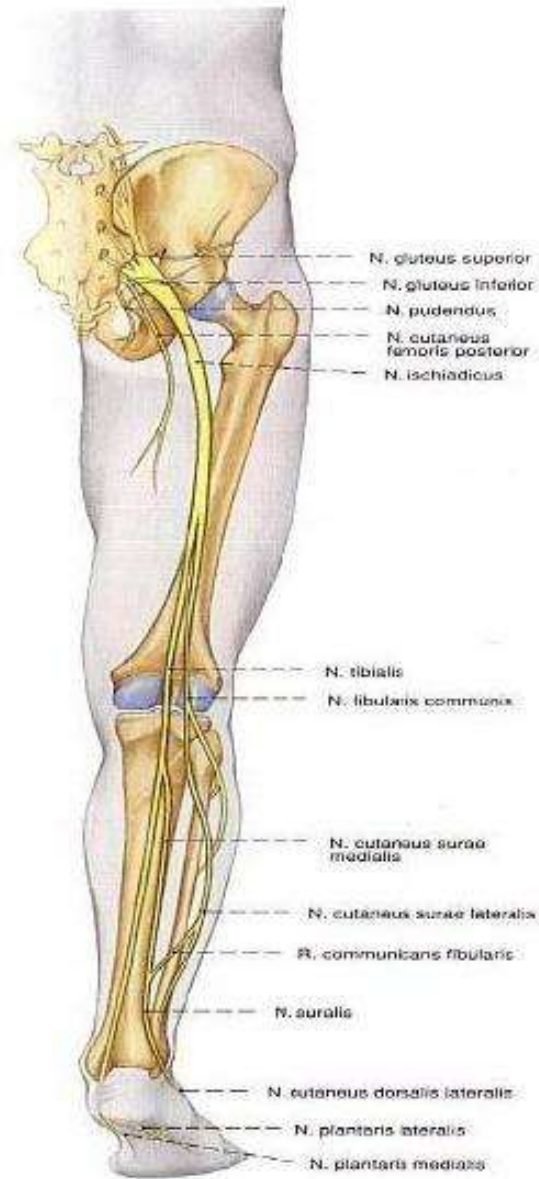
Ventral rami:



(b)



Gambar 1323 Saraf ekstremitas bawah; ikhtisar; tampak depan (ka.).



Gambar 1324 Saraf ekstremitas bawah; ikhtisar; tampak belakang (ka.).



GAME

- <https://wordwall.net/play/25058/922/252>
- <https://wordwall.net/play/25058/922/703>



الْحَمْدُ لِلَّهِ

that I'm
able to be
thankful.

tutlix

SEMOGA SUKSES
