



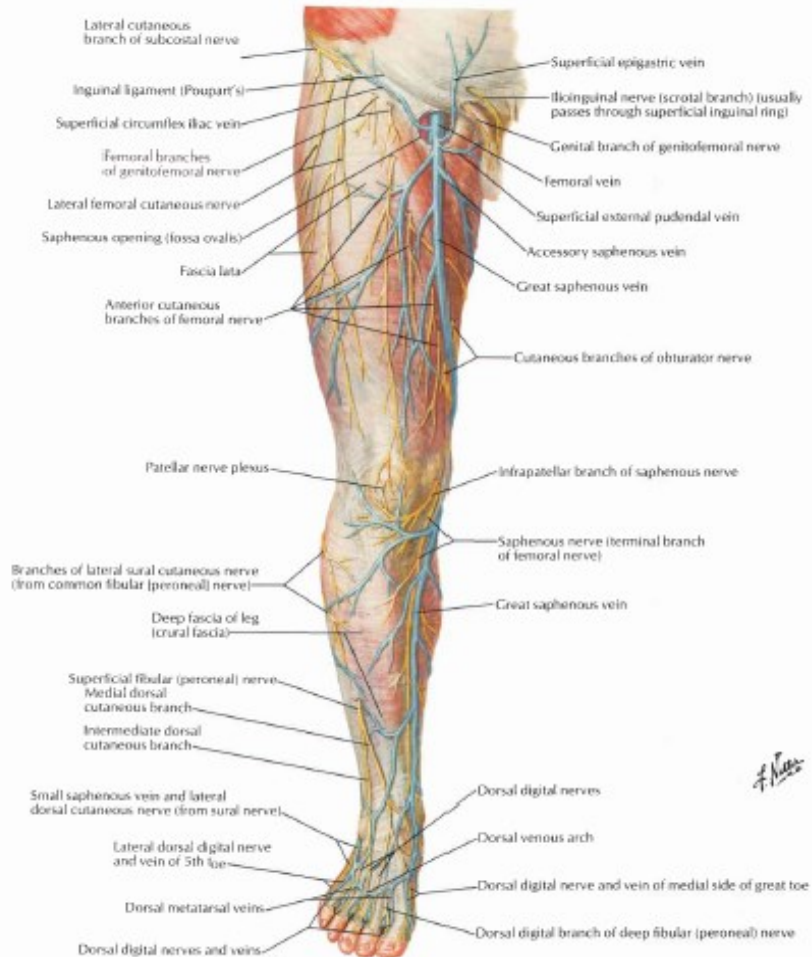
VASKULARISASI DAN INNERVASI EXTREMITAS CAUDALIS

dr. Anung Putri Illahika.M.Si

LABORATORIUM ANATOMI

FK UMM

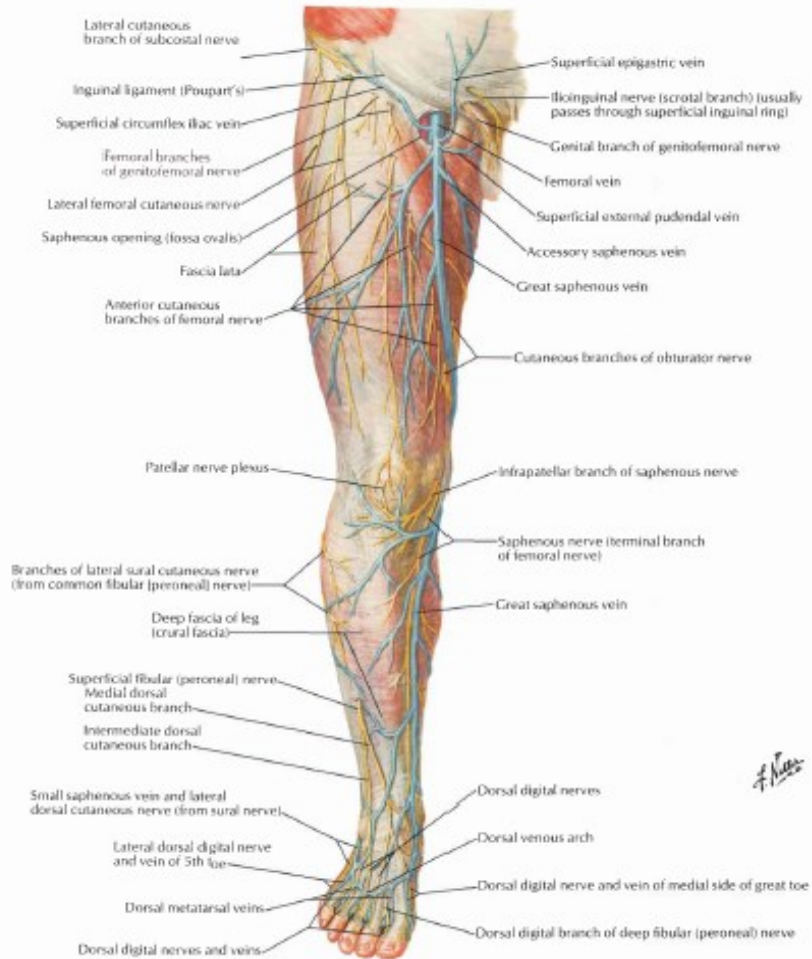
NERVUS CUTANEUS, VENA SUPERFICIALIS (ANTERIOR VIEW)



■ V. saphena magna :

■ Dimulai dari medial arcus venosus pd pedis → naik di depan malleolus medialis → sisi medial tibia → jalan bersama n. saphenus → bawah condylus medialis os tibia → sisi medial femur → fossa ovalis pd fascia lata → muara ke v. femoralis

NERVUS CUTANEUS, VENA SUPERFICIALIS (ANTERIOR VIEW)



■ N. cutaneus femoris lateralis

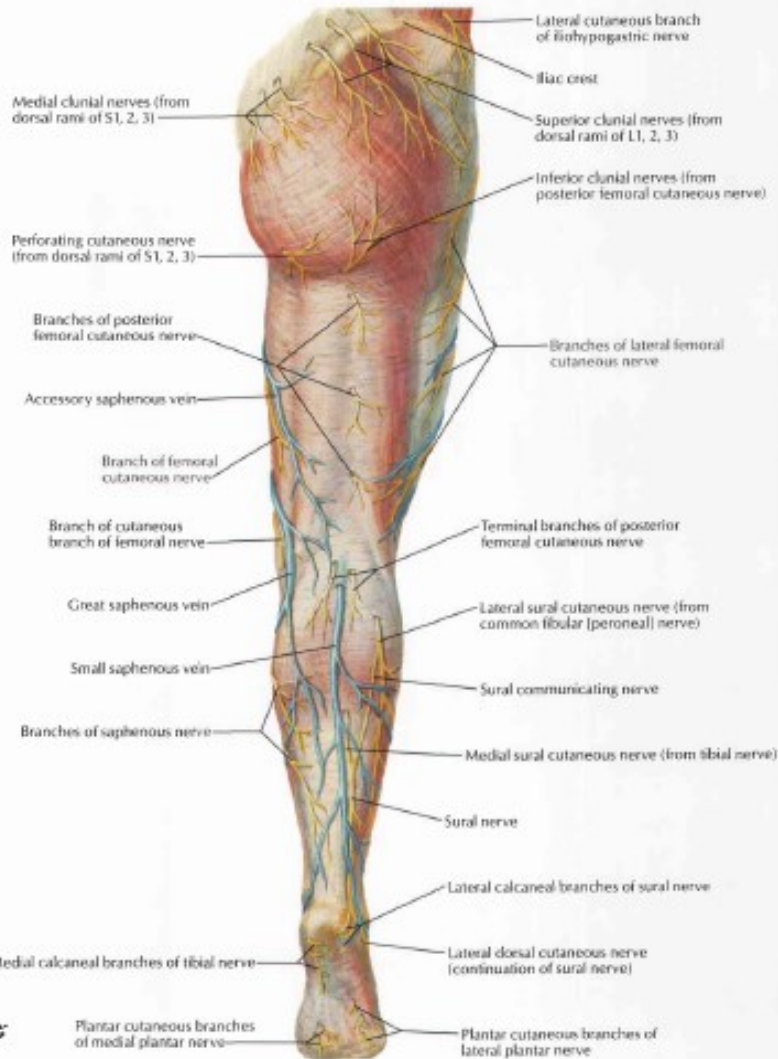
■ N. saphenus

■ N. peroneus superficialis

■ N. cutaneus surae lateralis

■ N. suralis

NERVUS CUTANEUS, VENA SUPERFICIALIS (POSTERIOR VIEW)



■ V. saphena parva:

■ Dimulai dari lateral arcus venosus pd pedis → naik di bawah malleolus lateralis → jalan bersama n.suralis → fossa poplitea → muara ke v.poplitea

■ N. peroneus profundus

THE LUMBAR PLEXUS

Lumbar plexus

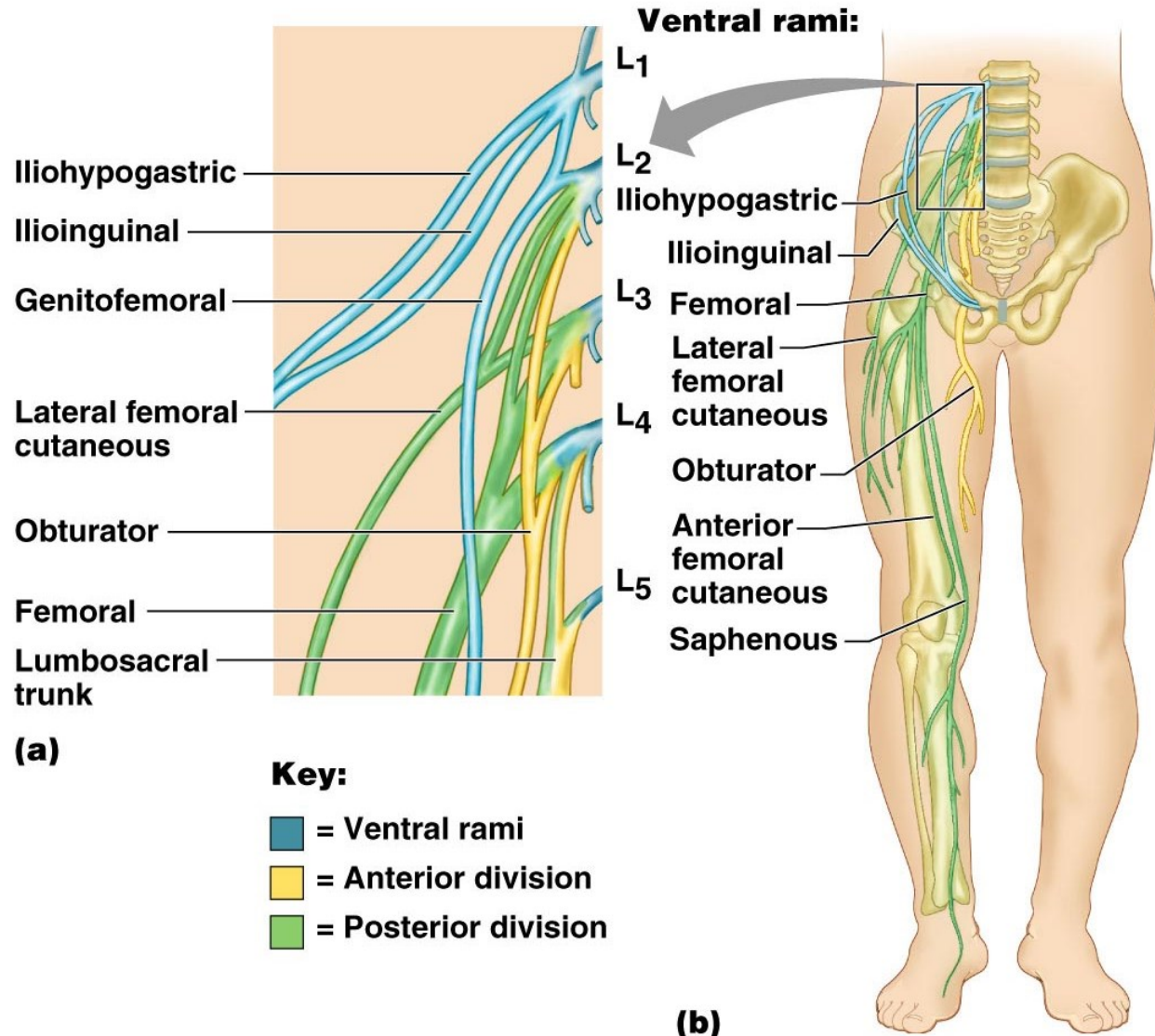
Arises from L1– L4

Smaller branches innervate the posterior abdominal wall and psoas muscle

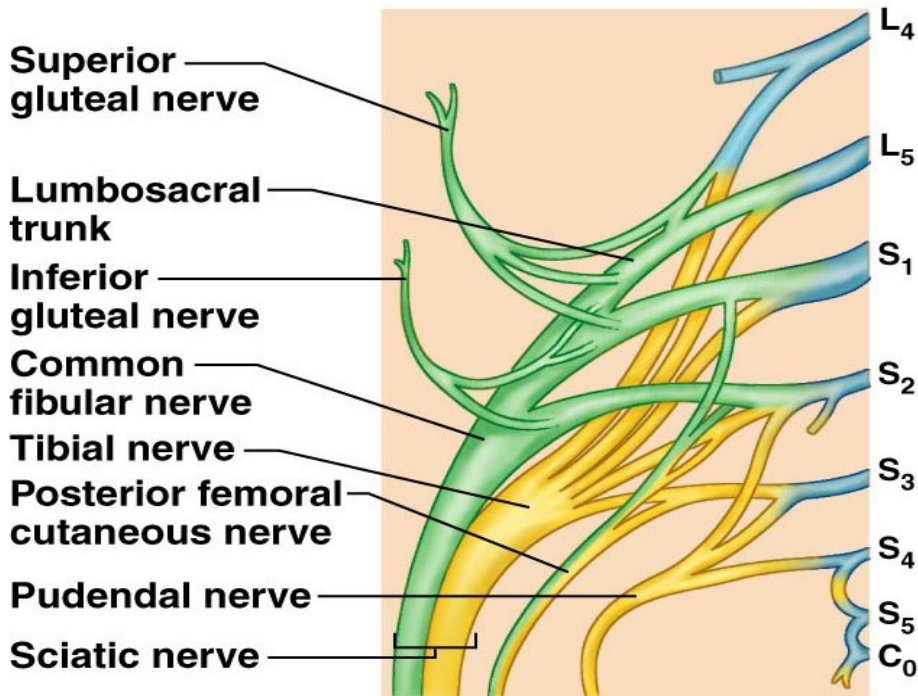
Main branches innervate the anterior thigh

Femoral nerve – innervates anterior thigh muscles

Obturator nerve – innervates adductor muscles



THE SACRAL PLEXUS

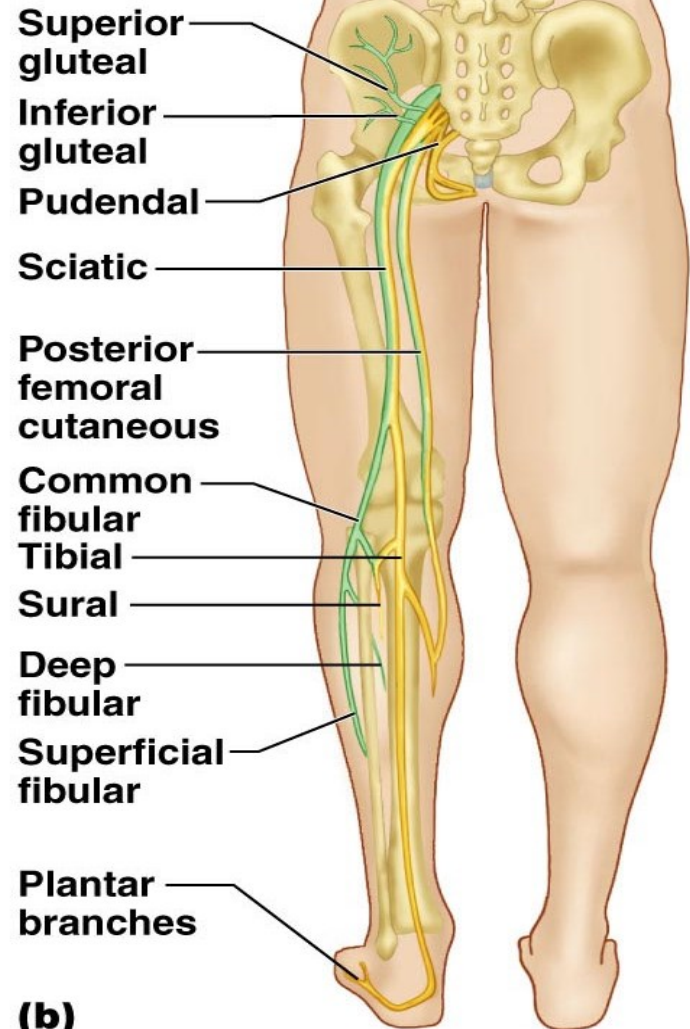


Key:

- = Ventral rami
- = Anterior divisions
- = Posterior divisions

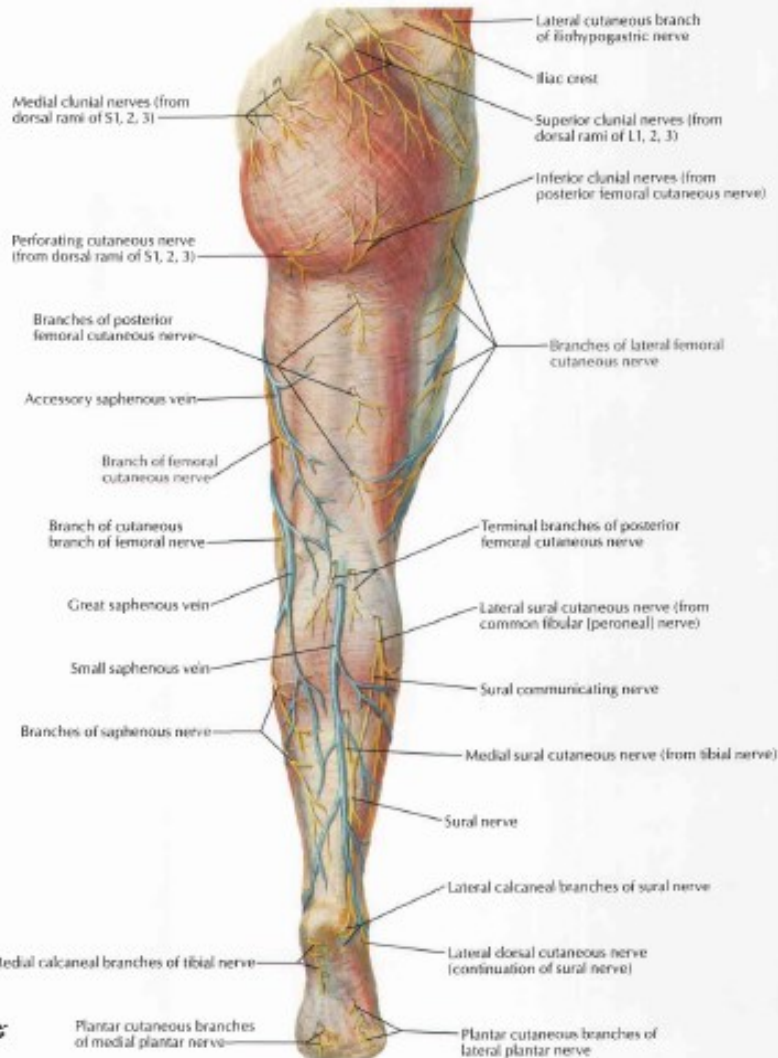
(a)

Ventral rami:



(b)

NERVUS CUTANEUS, VENA SUPERFICIALIS (POSTERIOR VIEW)



■ N. cutaneus femoris posterior :

■ Innervasi kulit regio glutea, femoris dan cruris.

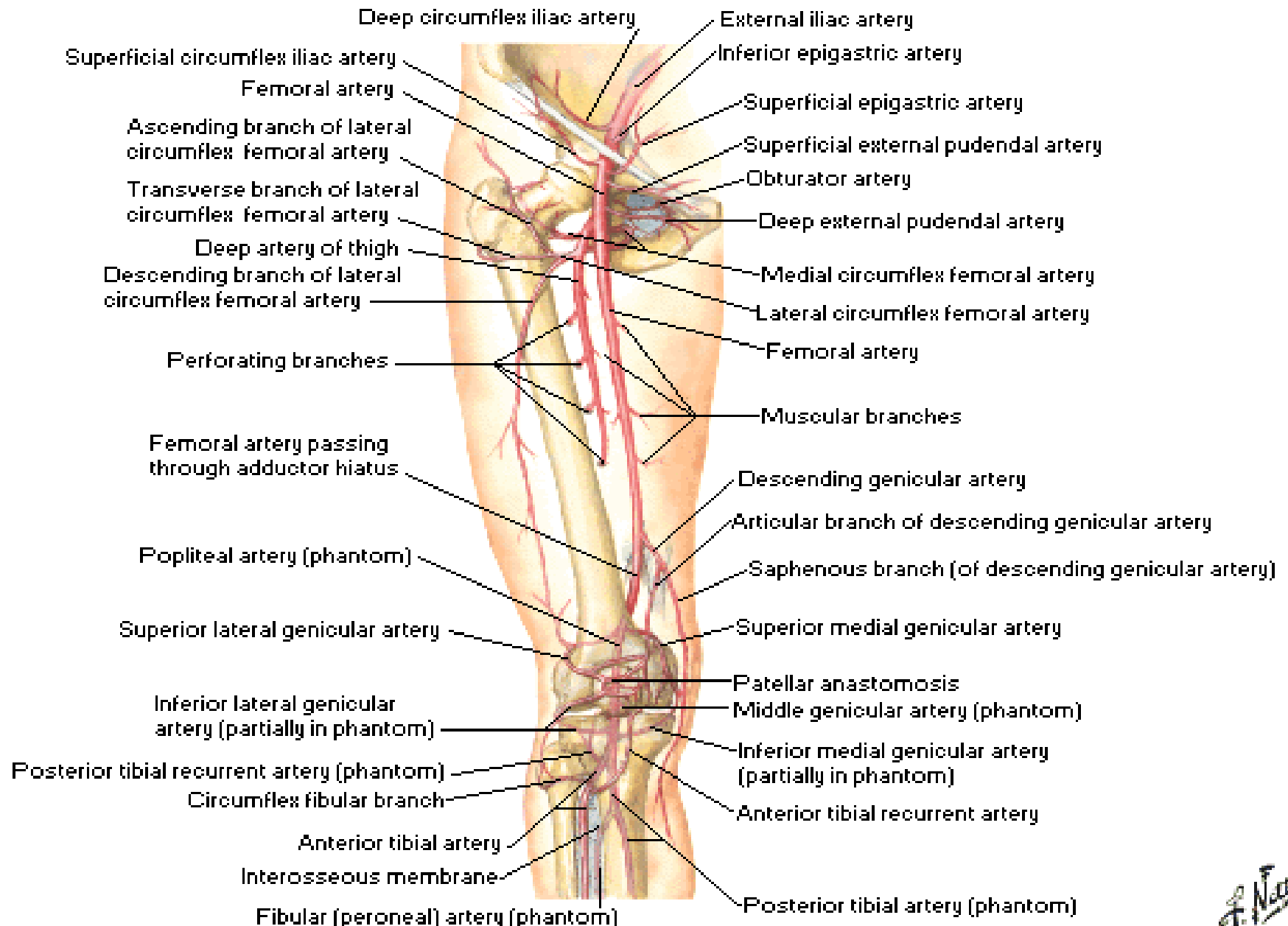
■ N.clunial :

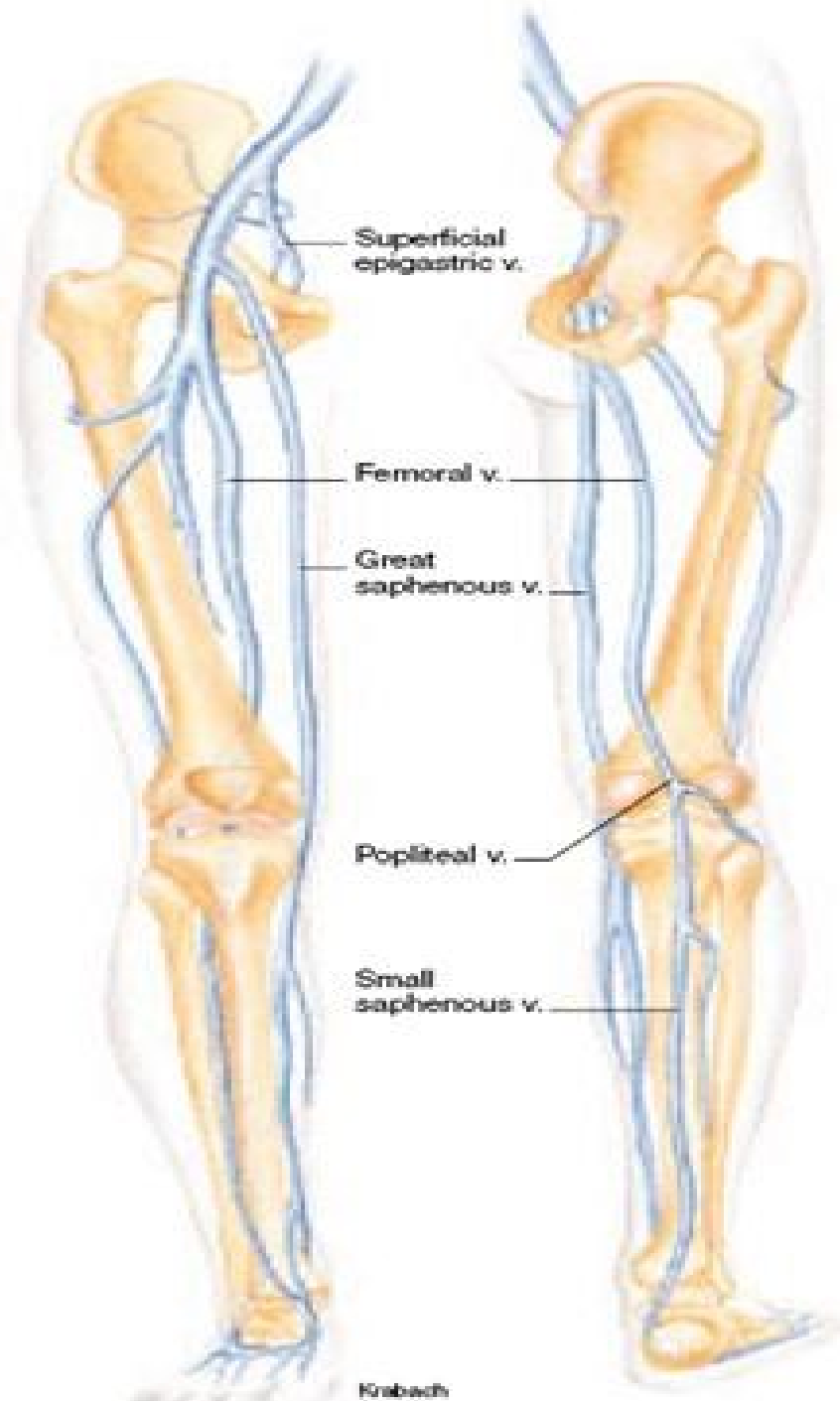
■ Terdiri atas n.clunius superior, medial dan inferior.

■ Menginnervasi kulit regio glutea

Arteries of Thigh and Knee

Schema

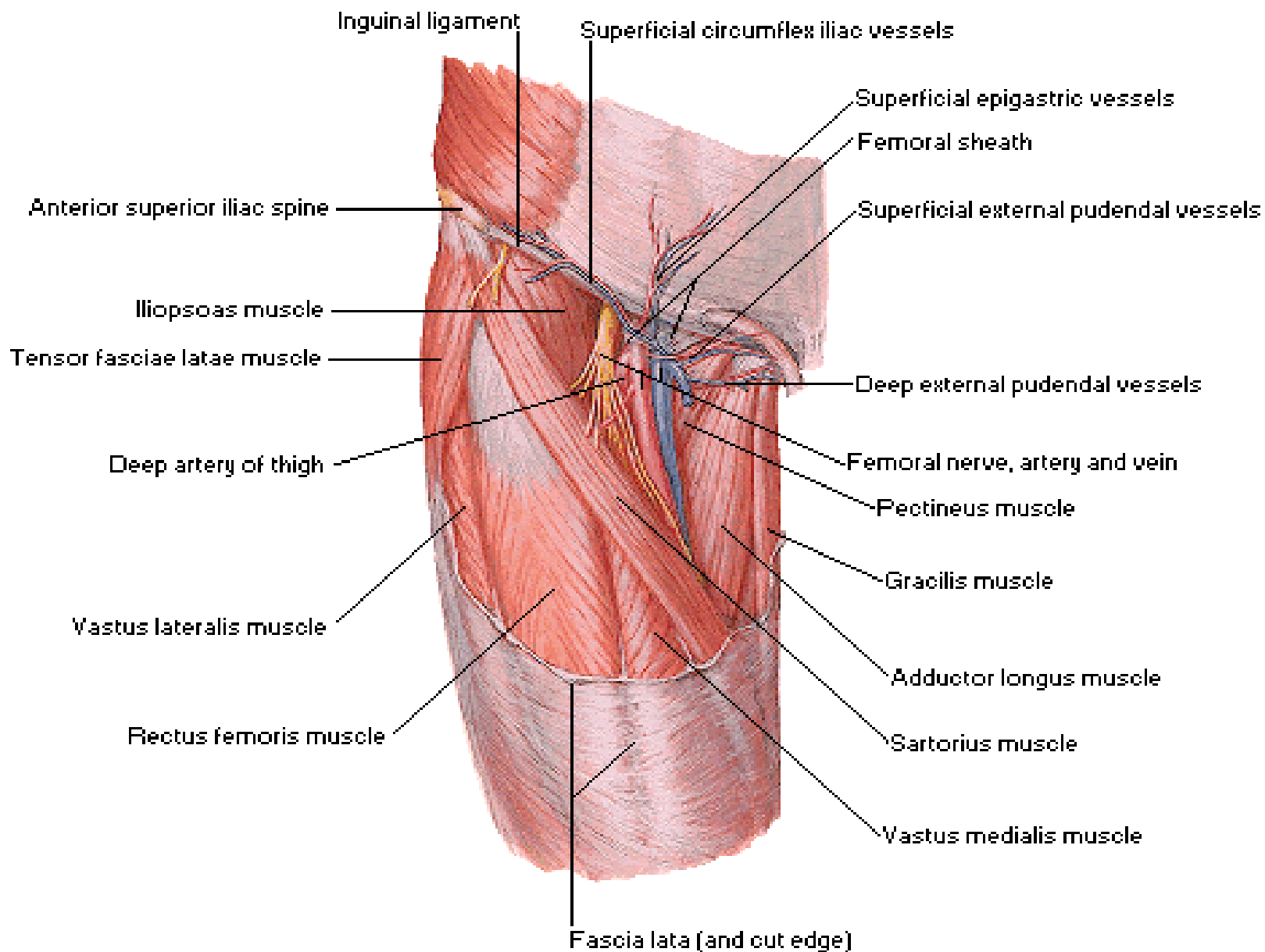




PEMBULUH DARAH VENA EXTREMITAS INFERIOR

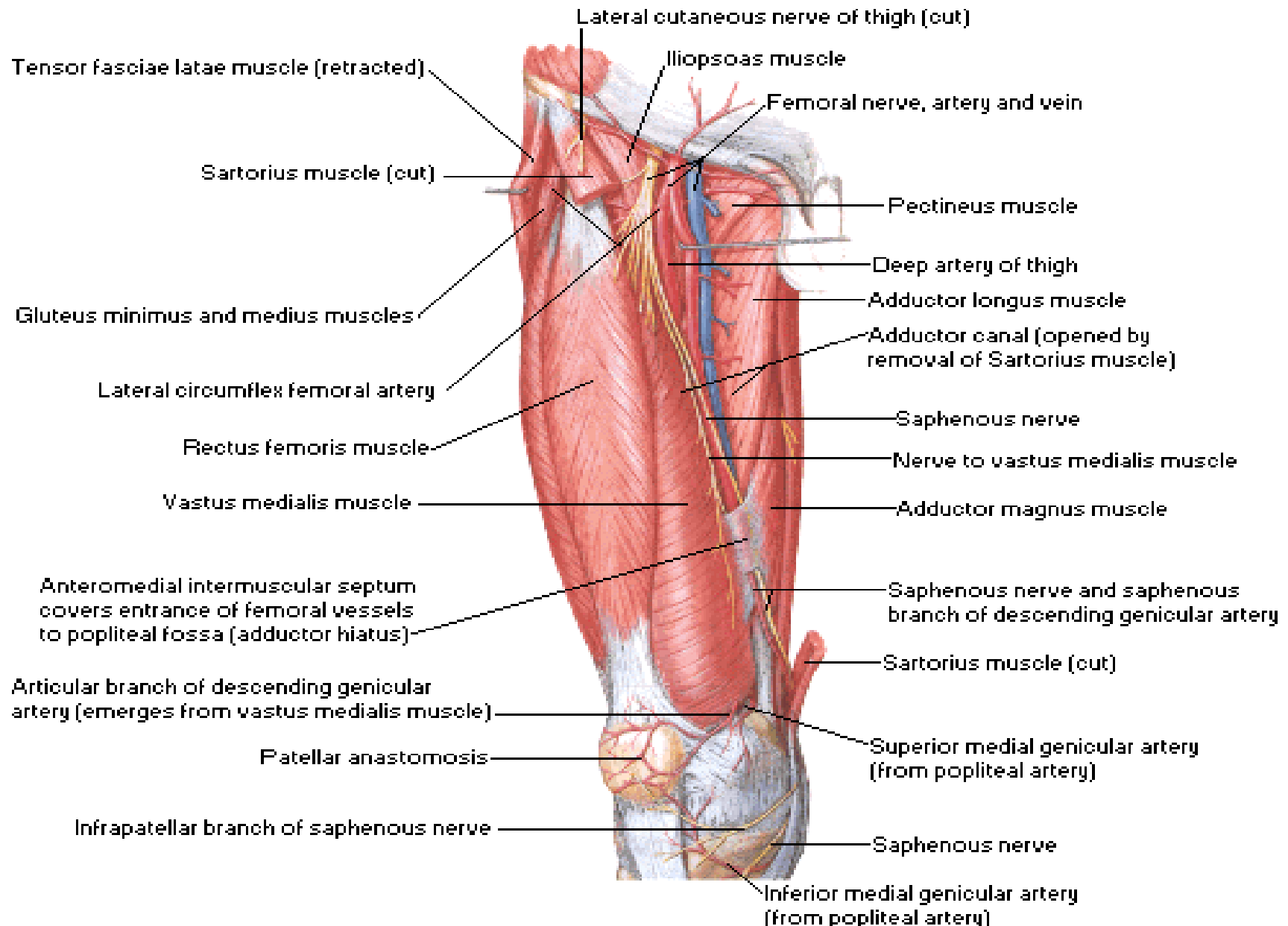
Arteries and Nerves of Thigh

Superficial Anterior View



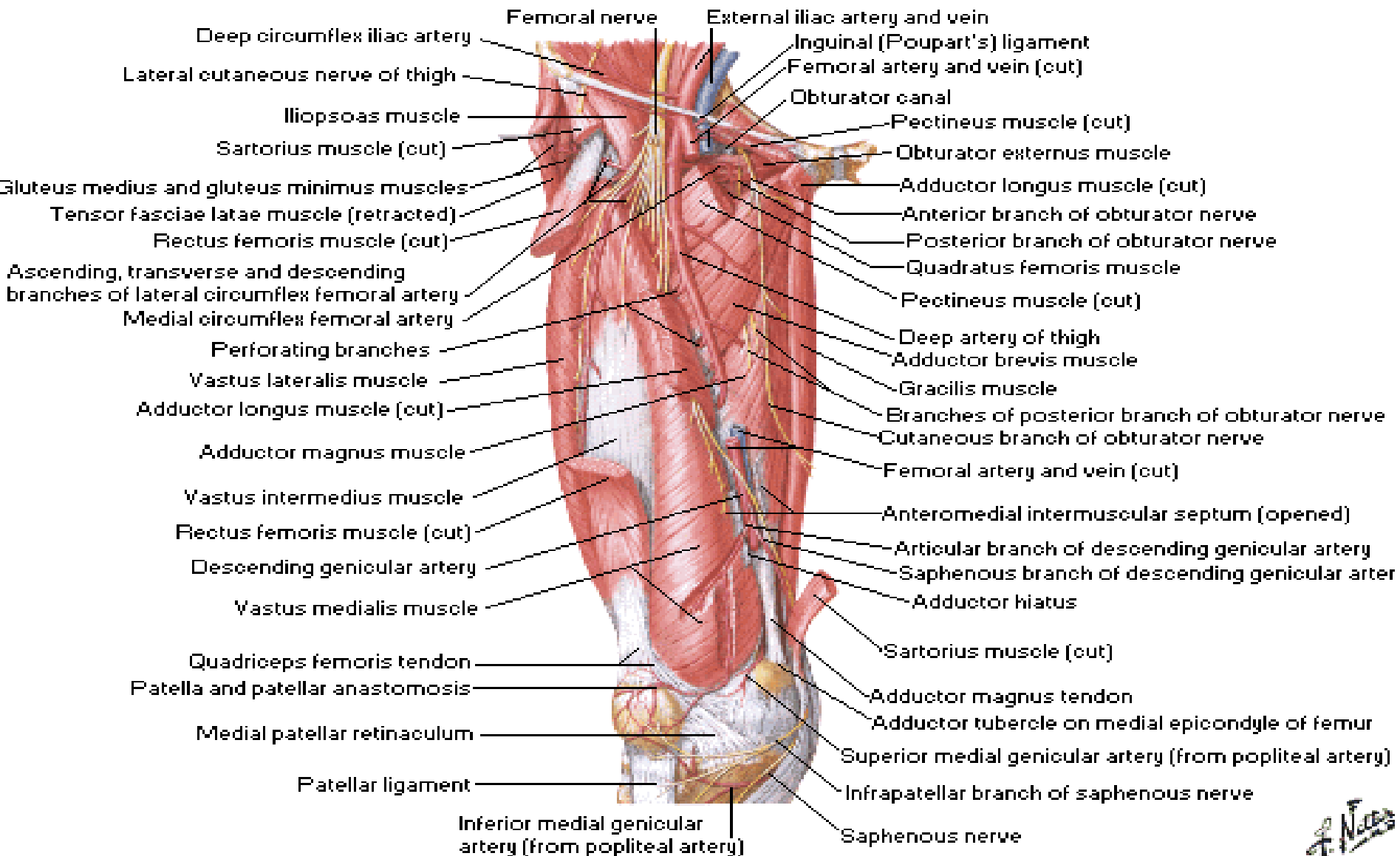
Arteries and Nerves of Thigh

Deeper Anterior View

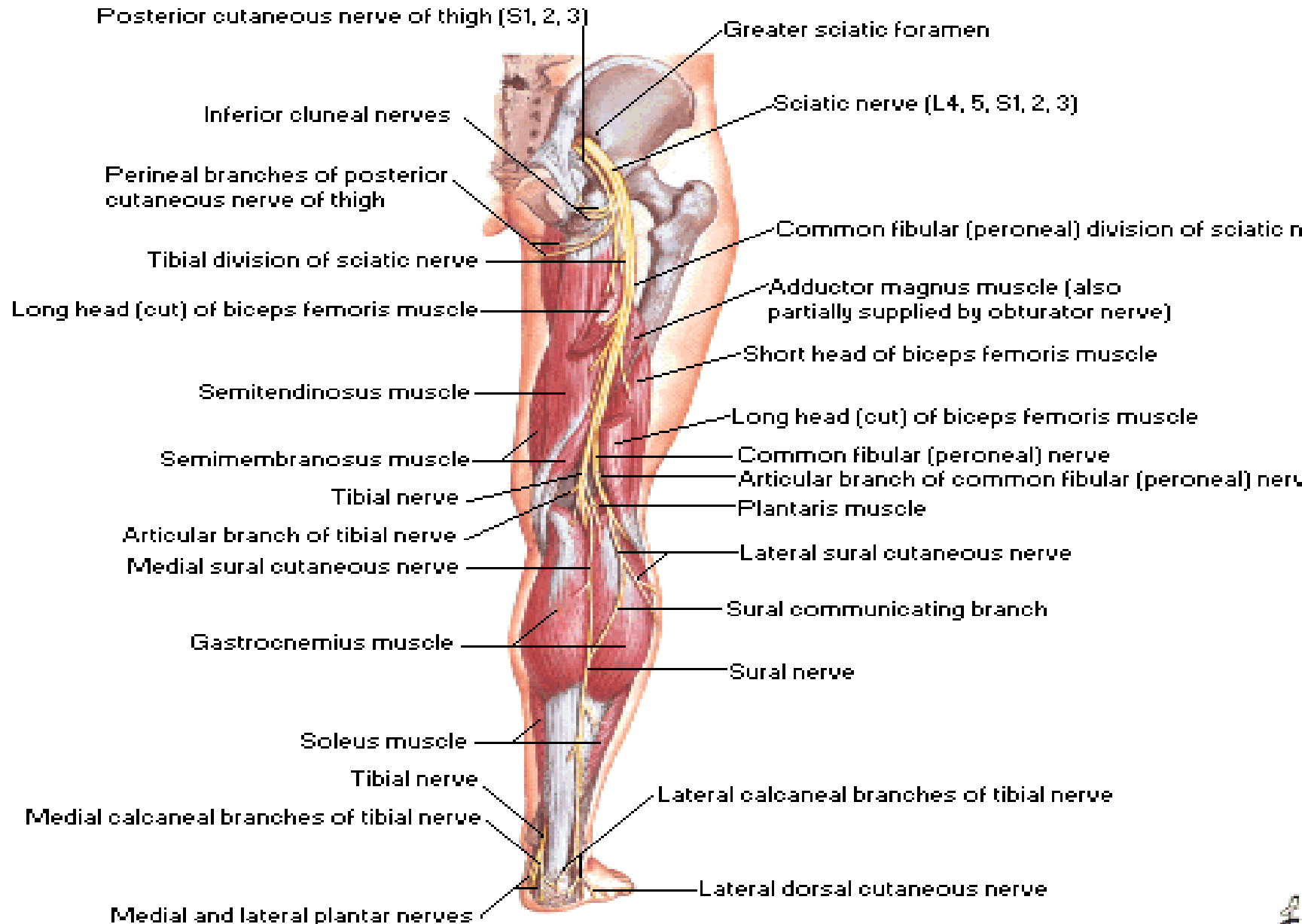


Arteries and Nerves of Thigh

Deepest Anterior View

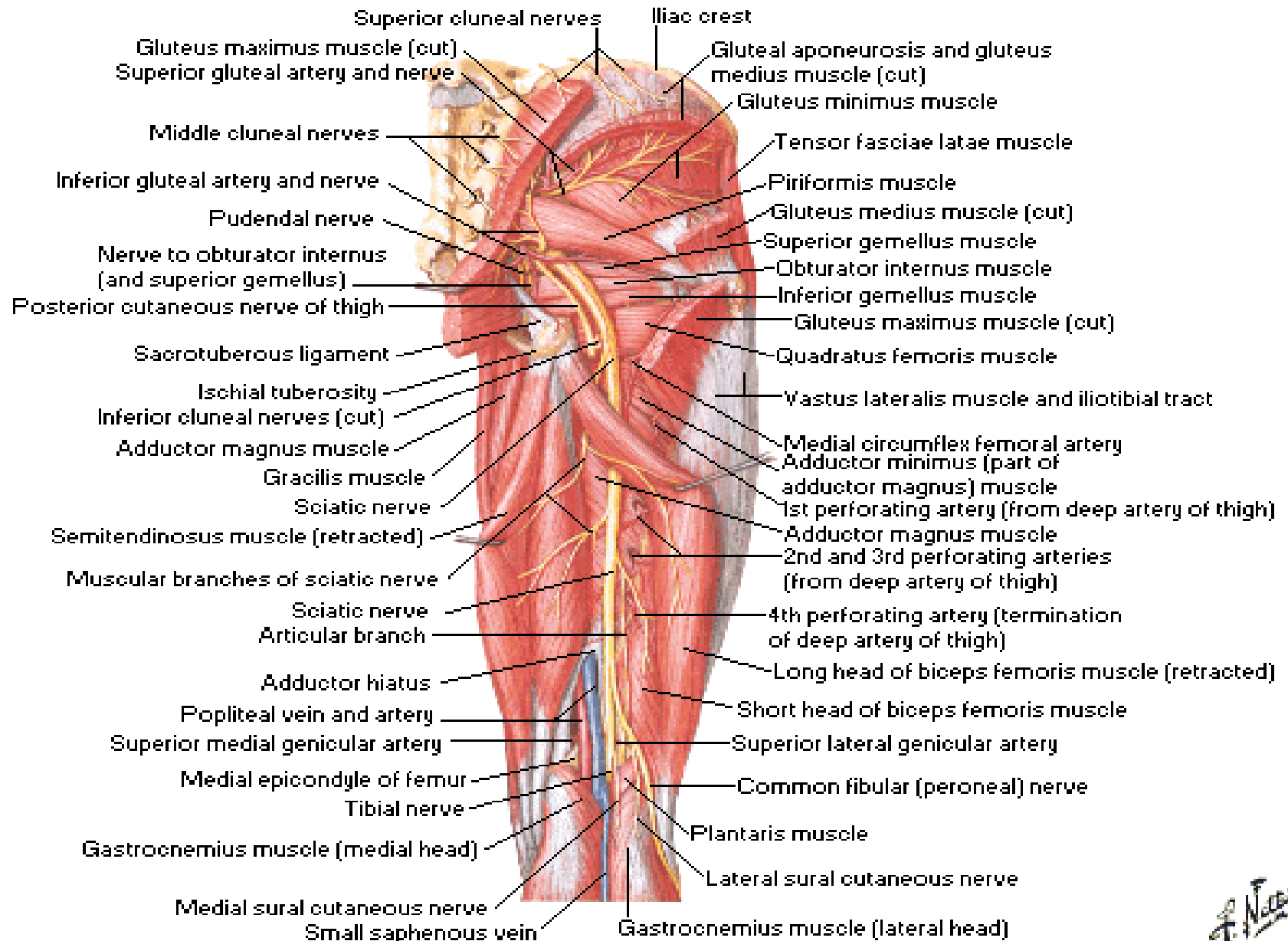


Sciatic and Posterior Femoral Cutaneous Nerves

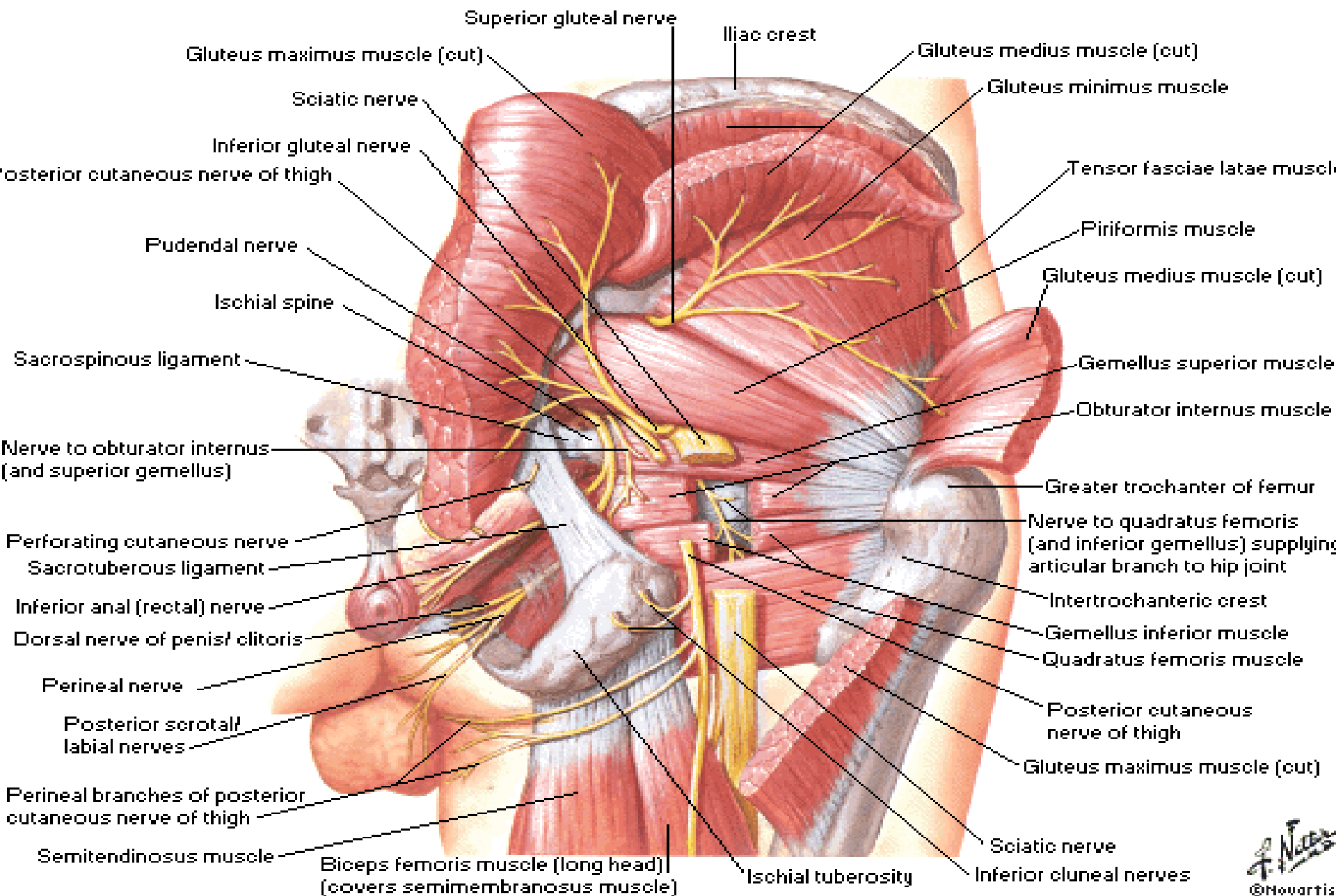


Arteries and Nerves of Thigh

Posterior View

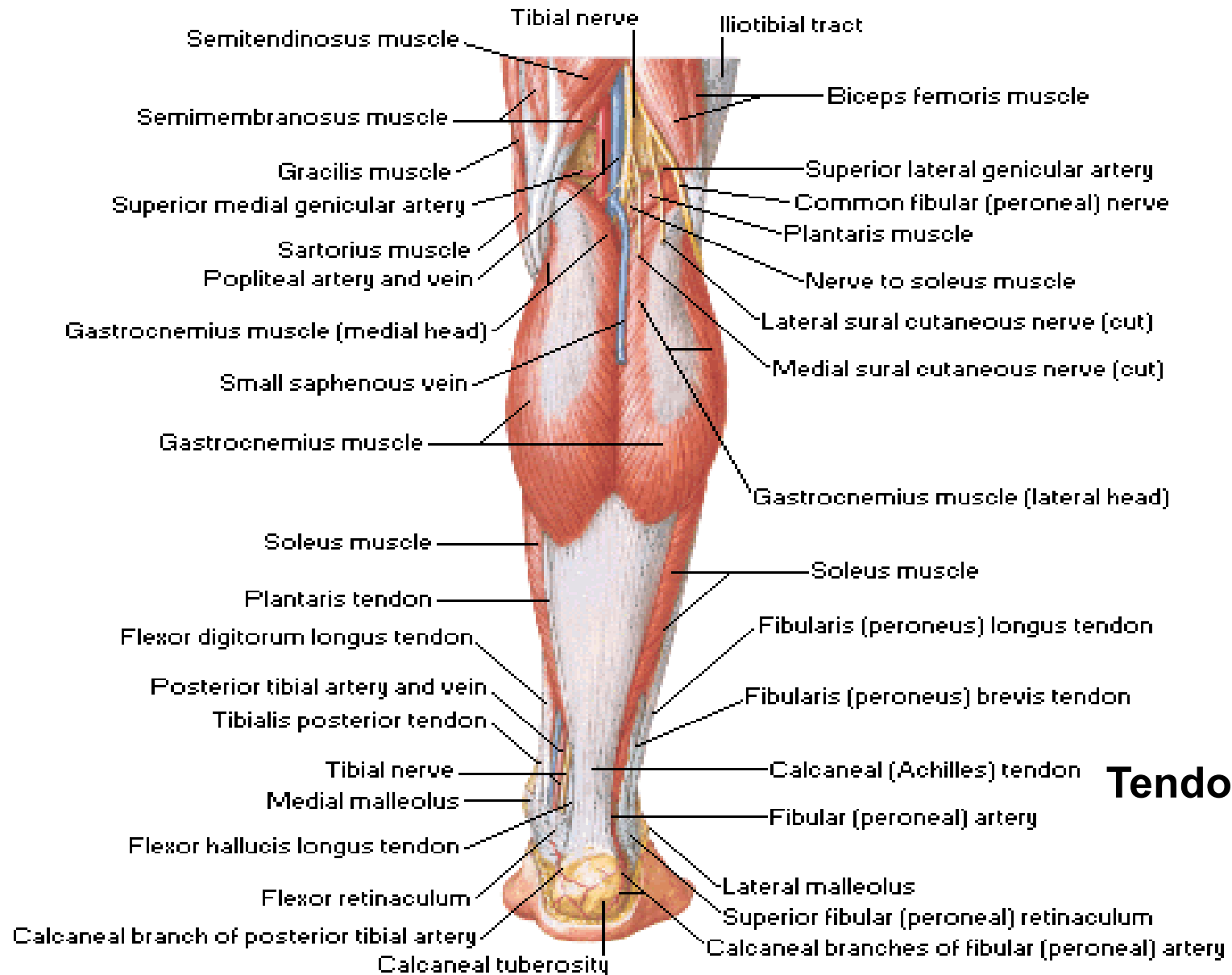


Nerves of Hip and Buttock

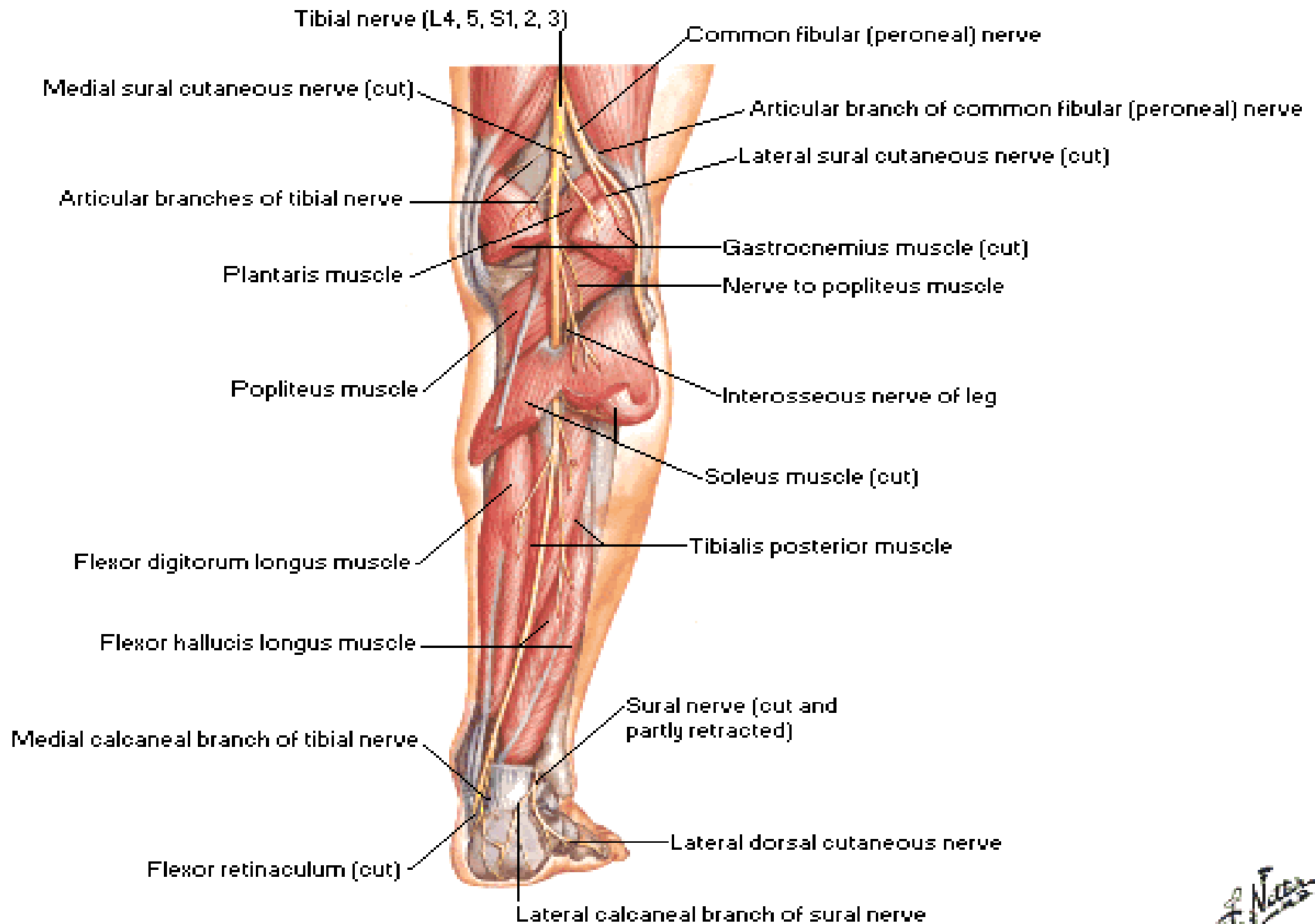


Muscles of Leg [Superficial Dissection]

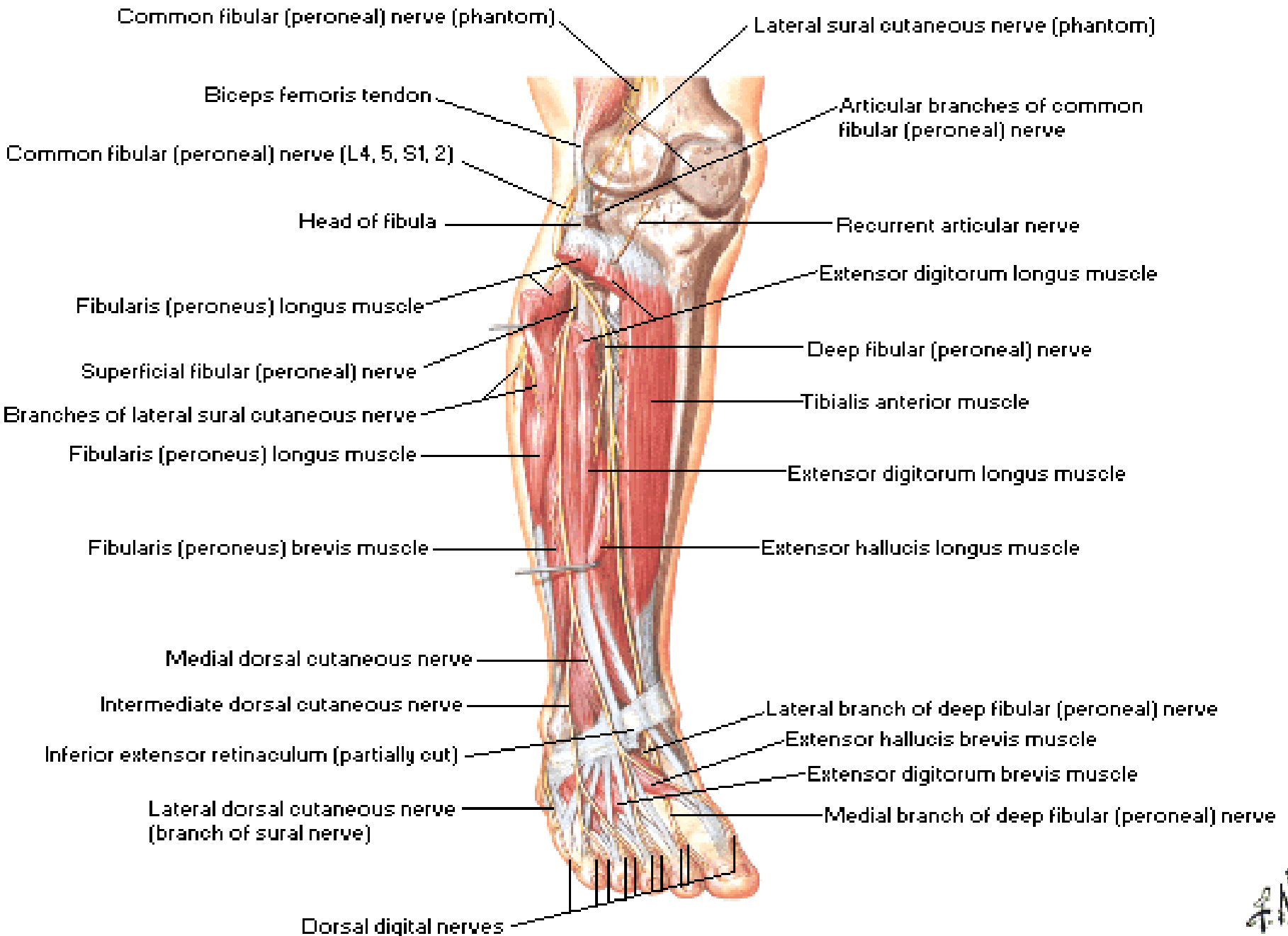
Posterior View



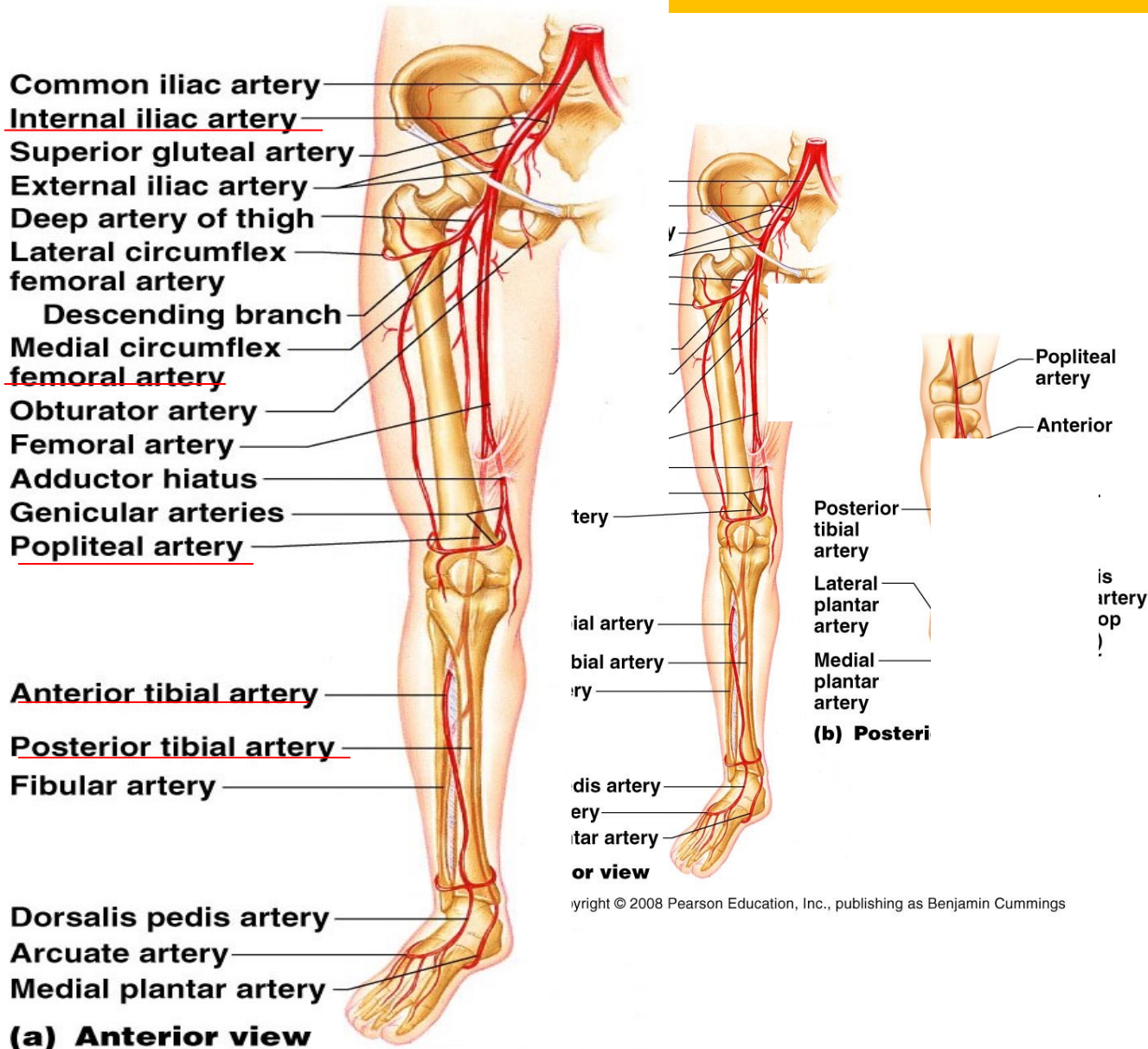
Tibial Nerve



Common Fibular [Peroneal] Nerve



ARTERIES OF THE PELVIS AND LOWER LIMBS



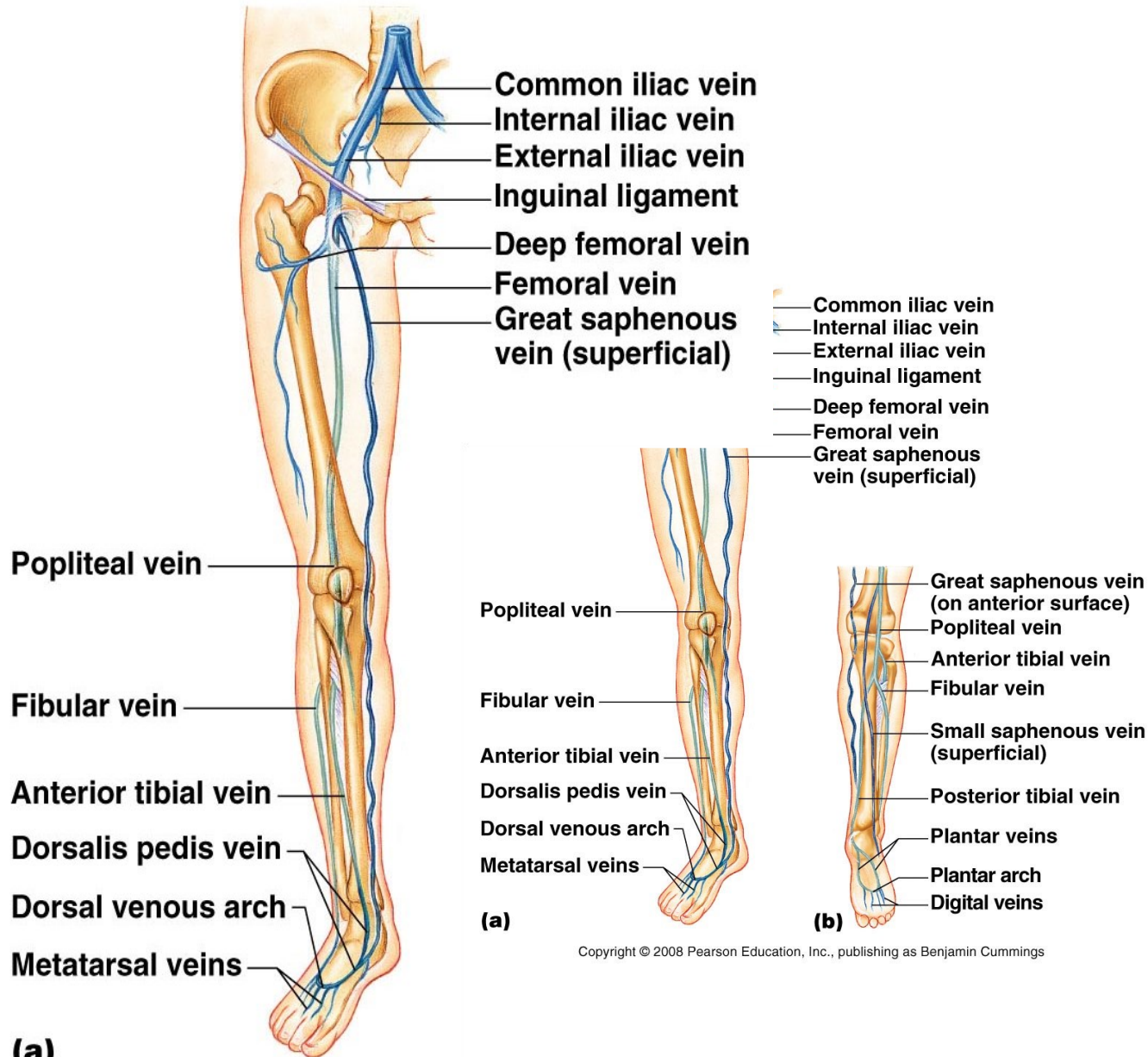
Copyright © 2008 Pearson Education, Inc., publishing as Benjamin Cummings

Figure 19.16a

VEINS OF THE PELVIS AND LOWER LIMBS

- Deep veins
 - Share the name of the accompanying artery
- Superficial veins
 - **Great saphenous vein** empties into the femoral vein
 - **Small saphenous vein** empties into the popliteal vein

VEINS OF THE RIGHT LOWER LIMB AND PELVIS



Copyright © 2008 Pearson Education, Inc., publishing as Benjamin Cummings

Figure 19.26a



**TERIMA KASIH
SELAMAT BELAJAR**