

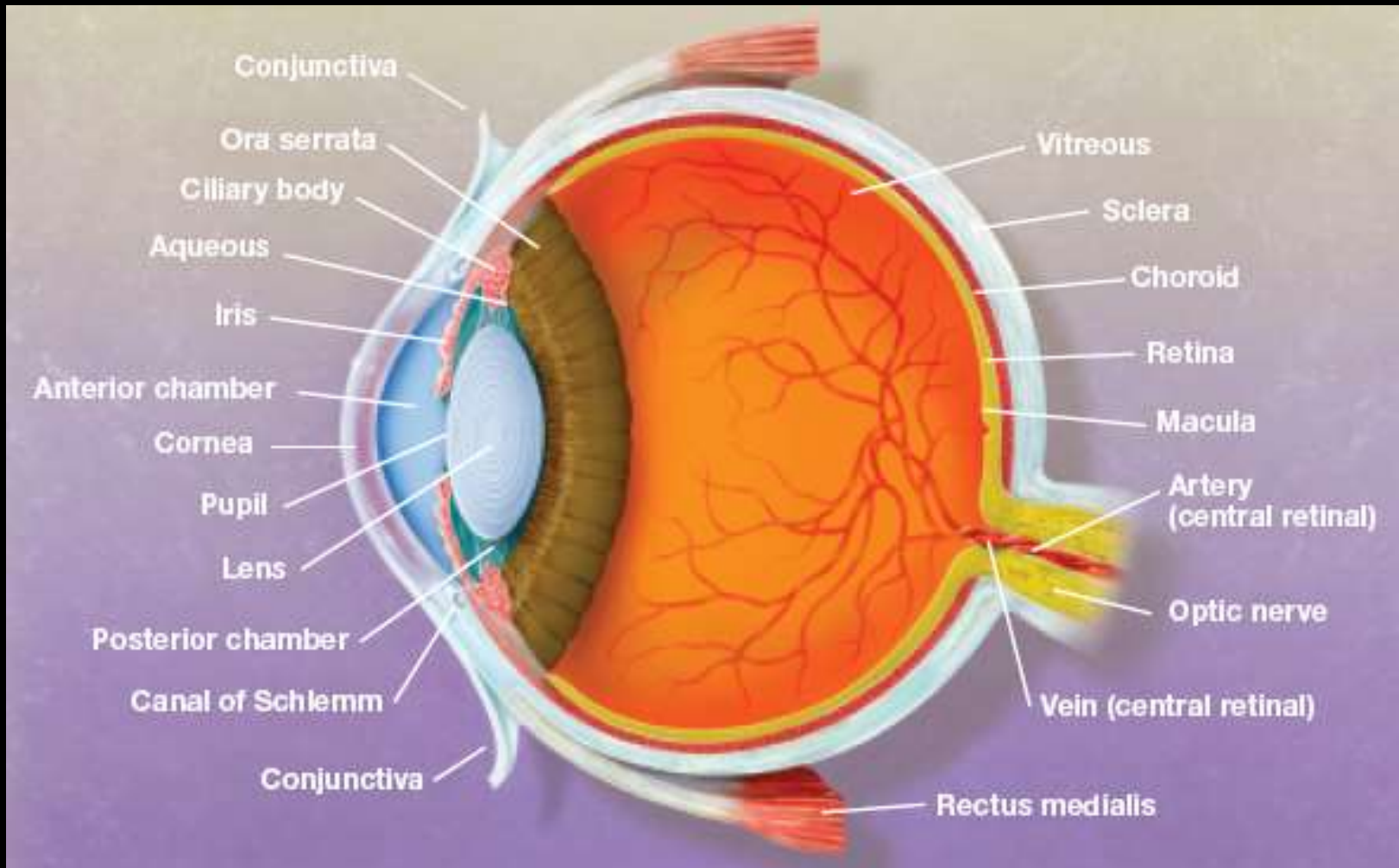
Kegawatan dan Trauma Okuli

ALFA SYLVESTRIS, MD, PhD

Objectives

- Review ocular anatomy
- Understand basic ophthalmic workup
- Know differential for:
 - Red eye
- Recognize and manage common ocular emergencies

Anatomy of the Eye



Useful Tools

- Near vision card
- Penlight with blue filter
- Topical anesthetic
- Fluorescein strips
- Topical mydriatic




Eye Exam

- **Visual acuity** - Snellen eye chart, counting fingers, light perception
- **CN II – VII** - Pupils, visual fields, EOMs, facial droop
- **Inspection/palpation of eye and surrounding structures** - Asymmetry, proptosis, enophthalmos, orbital rim
- **Lids/ducts**
- **Slit lamp** – Anterior segment
- **Fundoscopy** – Posterior segment
 - Contraindications to dilation – significant head trauma, suspected rupture, history of glaucoma
- **Intraocular pressure** - Goldman applanation tonometry, Tonopen

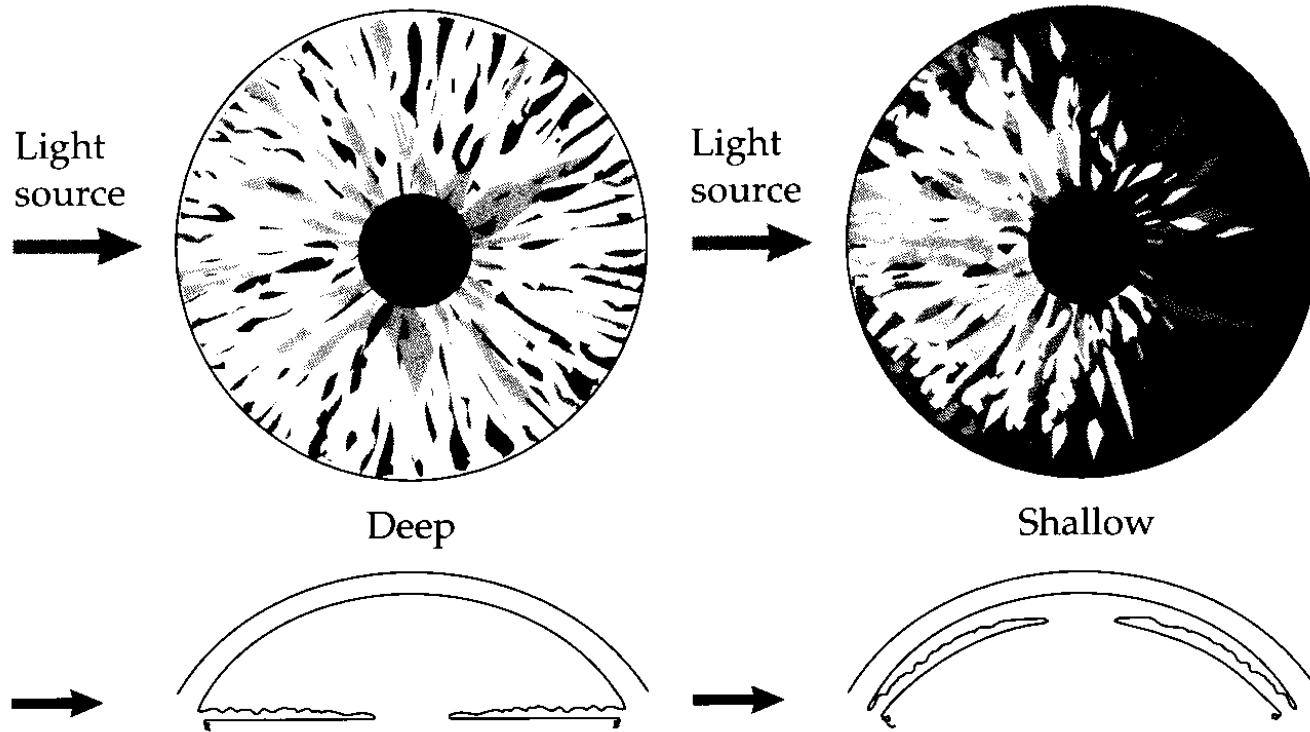
Anterior Segment

- Perform at slit lamp
 - If not available, use ophthalmoscope
- Inspect
 - Conjunctiva
 - Cornea
 - Anterior chamber
 - Iris
 - Lens



Estimating Anterior Chamber Depth

1. Shine a light from the temporal side of the head across the front of the eye parallel to the plane of the iris.
2. Look at the nasal aspect of the iris. If two thirds or more of the nasal iris is in shadow, the chamber is probably shallow and the angle narrow.



Tonometry

- Measures the intraocular pressure by calculating the force required to depress the cornea a given amount with a tonometer.
- IOP 10-20 is considered normal.
- In chronic open angle glaucoma, IOP can be 20-30, and in acute angle closure glaucoma, IOP can be greater than 40.

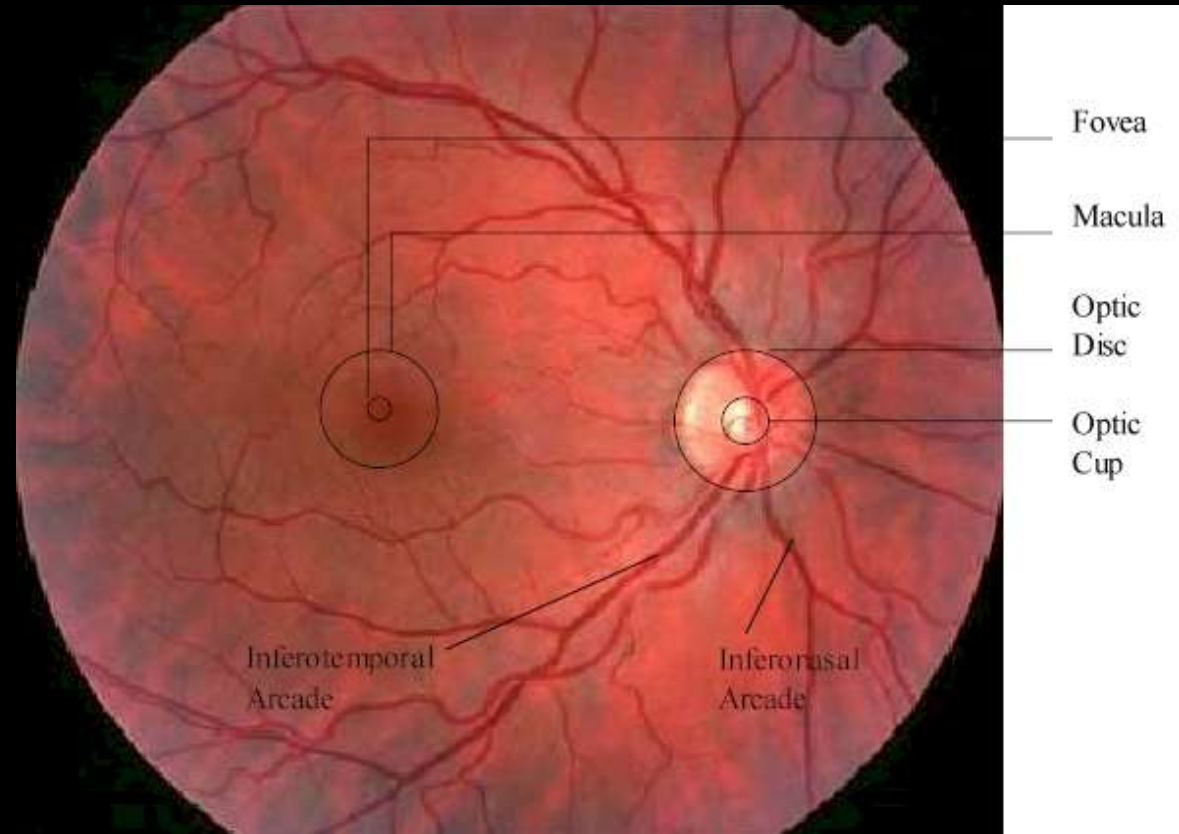
The Swinging Flashlight Test

- Measures both the direct and consensual response of pupil to light.
- Step 1: Shine light in right eye. This will cause BOTH right and left pupils to constrict via CN III through Edinger-Westphal nucleus.
- Step 2: Then swing pen light to left eye and check to make sure the left eye CONSTRICTS. If it constricts, this means that the LEFT CN II is intact and is causing a direct pupillary reflex. *If it dilates, then this is a sign that the LEFT retina or optic nerve is damaged and is called an Afferent pupillary defect. (APD)*

Posterior Segment

■ Examine

- Vitreous
- Optic disc
- Retinal vessels
- Macula

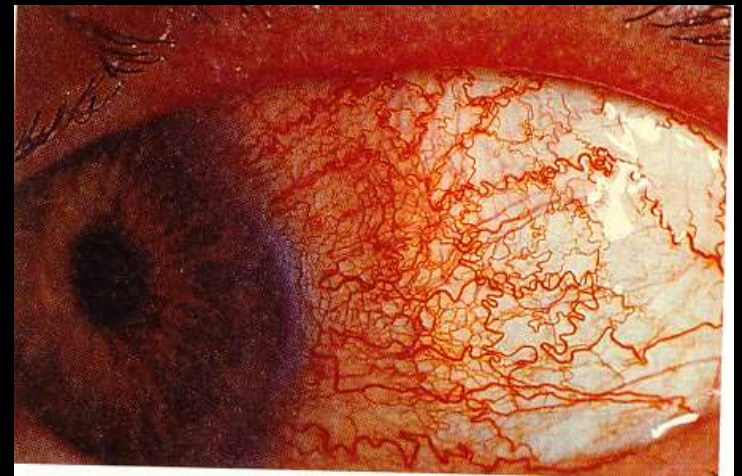


Algorithm for Diagnosing Red Eye

- Key worrisome clinical findings (ophtho referral needed):
 - Pain: Pain in eye often indicates more serious intraocular pathology (iritis, glaucoma).
 - Visual acuity: if decreased, usually more serious cause.
 - Pupil: if sluggish, worry about acute glaucoma
 - Pattern of redness: CILIARY FLUSH (Redness worse near cornea, usually serious intraocular cause: iritis or glaucoma).

Ciliary Flush

- Injection of deep conjunctival vessels and episcleral vessels surrounding the cornea.
- Seen in iritis (inflammation in the anterior chamber) or acute glaucoma.
- NOT seen in simple conjunctivitis



Red Eye: Key historical questions

- DO YOU HAVE PAIN?
Biggest distinguishing factor between emergent and non-emergent
- Do you wear contacts?
(increased risk of keratitis-corneal infection)
- Do you have any associated symptoms?
 - Decreased vision
 - photophobia/diplopia
 - flashes/floaters
 - Halos/N/V/Abd pain
 - Any above require referral
- Main differential of red eye:
 - Conjunctivitis (infectious/noninfectious)
 - Trauma, Foreign body
 - Subconjunctival hemorrhage
 - Angle closure glaucoma
 - Iritis/uveitis
 - Keratitis
 - Scleritis, episcleritis

DIFFERENTIAL DIAGNOSIS OF RED EYE

DIAGNOSTIC FEATURE	INFECTIOUS KERATITIS OR CONJUNCTIVITIS	UVEITIS	CORNEAL ULCER	CLOSED-ANGLE GLAUCOMA	EPISCLERITIS/ SCLERITIS	TRAUMA
Pain	Burning but not severe	Moderately severe ache; photophobia	Can be severe	Very severe ache; associated with nausea and emesis	Episcleritis: irritation Scleritis: severe ache	Usually severe ache or foreign body sensation
Vision	Normal	Moderately decreased	Can be severely decreased	Considerably decreased	Usually normal; can be decreased in posterior scleritis	Usually markedly blurred
Intraocular pressure	Normal	Usually normal or low, occasionally increased	Usually normal	Increased	Normal	May be normal, increased, or decreased
Lacrimation or discharge	Mucous or mucopurulent	Lacrimation	Purulent	Lacrimation	Lacrimation	Lacrimation
Hyperemia	Superficial conjunctival hyperemia of globe and eyelids	Circumcorneal	Diffuse	Circumcorneal and episcleral	Large patch (20–100%) of bulbar hyperemia	Diffuse (hemorrhagic)
Appearance of cornea	Normal	Transparent precipitates may be present on posterior surface	Infiltrate with overlying epithelial defect	Cloudy	Normal	If corneal injury, may be hazy
Anterior chamber	Normal depth	Normal depth	May have sterile hypopyon	Very shallow	Normal depth	Normal depth, may contain blood
Appearance of iris	Normal	Dull and swollen	May have vascular congestion	Congested and bulging	Normal	May be obscured by blood or lacerated
Pupils	Normal	Small, irregular	Normal	Mid-dilated, unreactive	Normal	May be large, normal, small, or irregular
Pupillary response to light	Normal	Minimal	Normal	Minimal	Normal	Usually minimal

Ocular Emergencies

1. Closed-angle glaucoma (3B)
2. Retinal detachment
3. Foreign body (konjunktiva 4A)
4. Orbital fractures
5. Corneal abrasions (3B), lacerations, ulcers
6. Chemical burns
7. Ruptured globe
8. CRAO
9. Retrobulbar hematoma

Kegawatan dan Trauma Mata lain yang masuk SKDI 2019

- Benda asing konjunktiva (4A)
- Sub conjunctival hemmorage (4A)
- Laserasi palpebra (3B)
- Hifema (3A)
- Benda asing kornea (3B)
- Luka bakar kornea (3B)

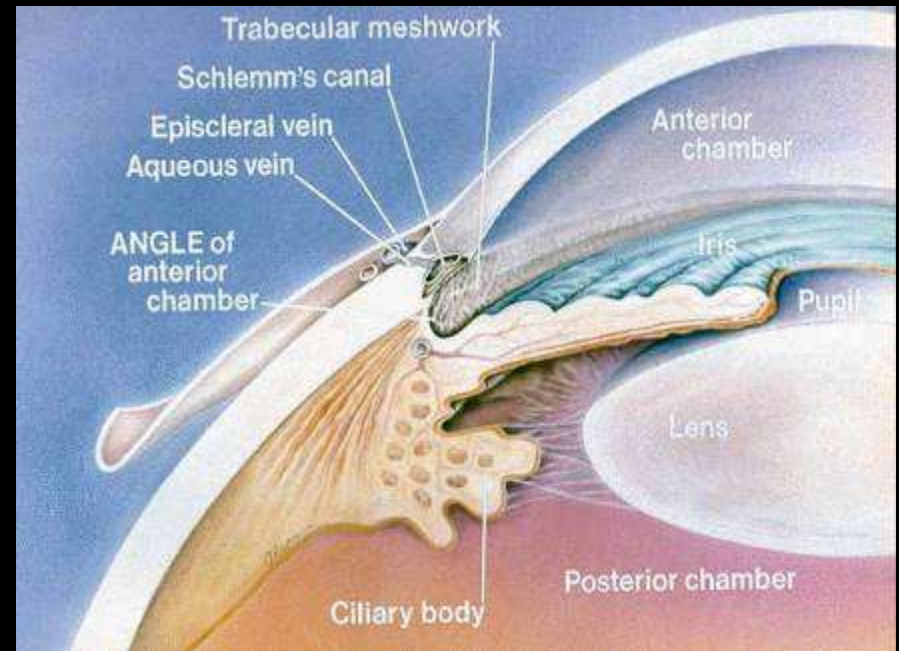
1. Acute Angle Closure Glaucoma (AACG) - Diagnosis

- History: Acute onset, higher risk in far-sighted
- Symptoms:
 - Pain
 - Halos (around lights)
 - Visual loss (usually peripheral)
 - Nausea/vomiting
- Signs:
 - Conjunctival injection
 - Corneal edema
 - Mid-dilated, fixed pupil
 - ↑ IOP (normal: 10 – 20 mmHg)



Glaucoma - Pathophysiology

- Aqueous humor produced by ciliary body, enters ant. chamber, drains via trabecular meshwork at angle to enter canal of Schlemm
- In AACG, iris obstructs trabecular meshwork by closing off angle
- Optic nerve damage 2°
↑IOP



Acute Angle Closure Glaucoma

■ Medical Tx

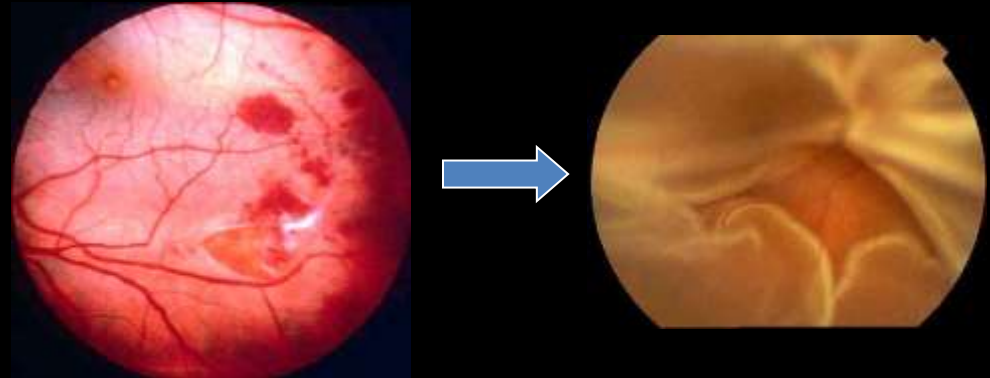
- Reduce production of aqueous humor
 - Topical β -blocker (timolol 0.5% - 1- 2 gtt)
 - Carbonic anhydrase inhibitor (acetazolamide 500mg iv or po)
 - Systemic osmotic agent (mannitol 1-2 g/Kg IV over 45 min)
- Or increase outflow
 - Topical α -agonist (phenylephrine 1 gtt)
 - Miotics (pilocarpine 1-2%)
- Topical steroid (prednisolone acetate 1%), 1 gtt Q15-30 min x 4, then Q1H

■ Definitive Tx

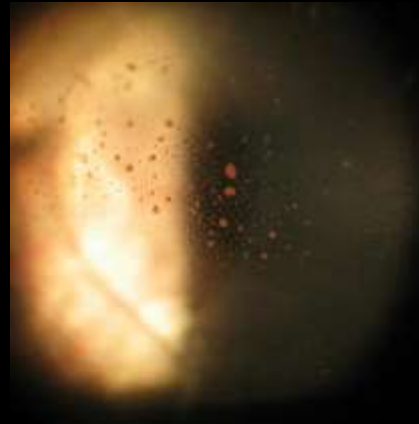- Ophtho referral: Laser peripheral iridectomy

2. Retinal detachment

- Pathophysiology:
 - separation of neurosensory layer of retina from underlying choroid and retinal pigment epithelium.



- “Schaffer’s sign”
 - Presence of vitreous pigment
 - Useful in that it has a NPV of 99% for detachment.



Retinal detachment

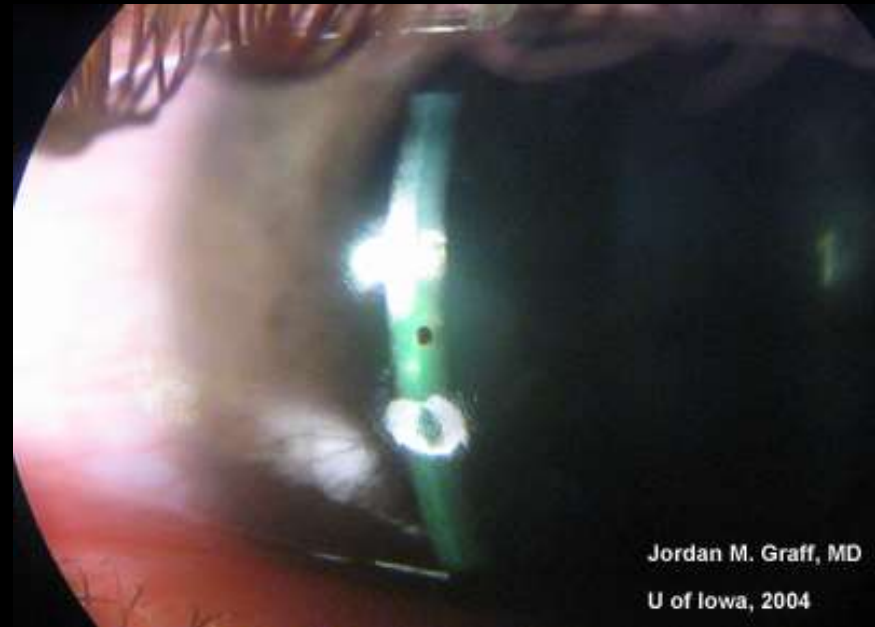
- Risk factors
 - Increasing age
 - History of posterior vitreous detachment
 - Myopia (nearsightedness)
 - Trauma
 - Diabetic retinopathy
 - FHx of RD
 - Cataract surgery.
- Signs and symptoms
 - “**black curtain coming down over visual field**”
 - bright flashes of light (photopsia)
 - increasing floaters
 - decreased visual acuity
 - distortion of objects (metamorphopsia)
 - +APD on exam.

Retinal detachment

- Diagnosis - If direct ophthalmoscopy is inconclusive, refer to ophtho for dilated fundus exam with indirect ophthalmoscope. Direct ophthalmoscopy is not very effective at visualizing periphery where most RD's occur.
- Treatment
 - Surgery to replace retina onto nourishing underlying layers.
 - Surgical options include laser photocoagulation therapy, and scleral buckle with intraocular gas bubble to keep retina in place while it heals.
- **KEY MANAGEMENT POINT-** know “classic” presentation so you can refer to an ophthalmologist quickly.

3. Foreign body

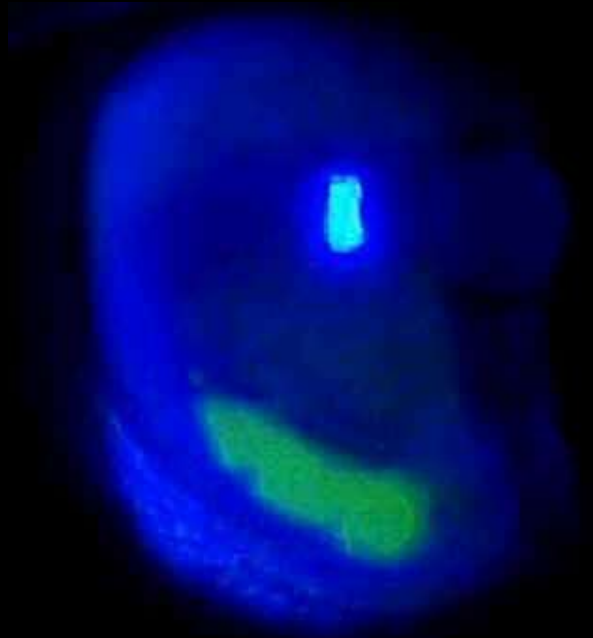
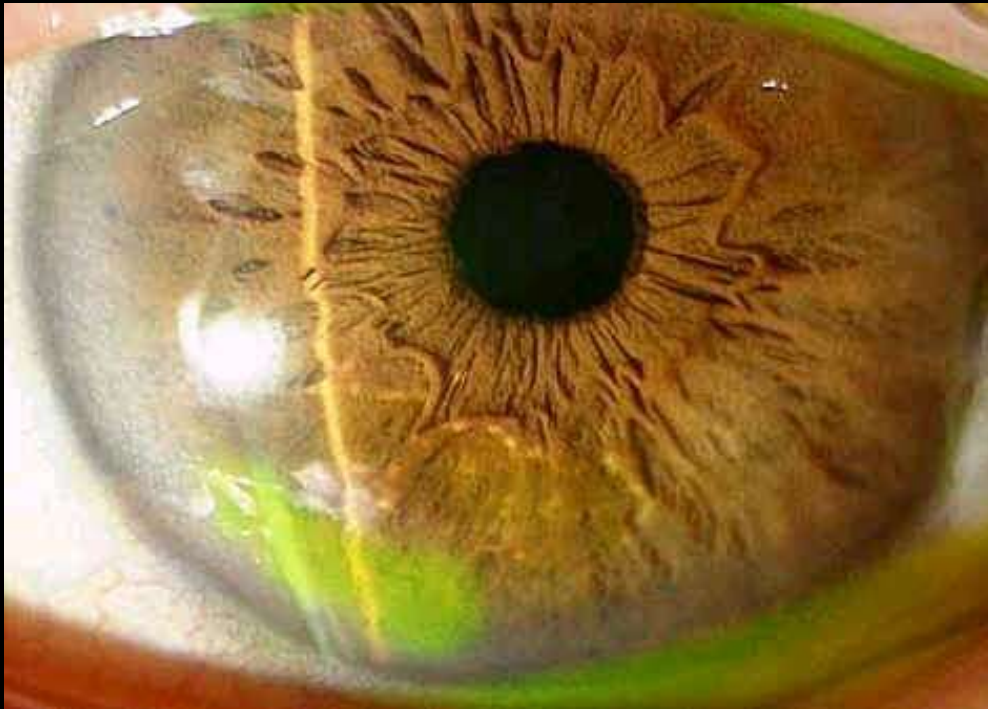
- Often metallic foreign body following work injury.
- Signs and symptoms: foreign body sensation, tearing, red, or painful eye. *Pain often relieved with the instillation of anesthetic drops.*
- Stain with fluorescein stain and illuminate under blue fluorescent light (Wood's lamp) is effective to see corneal epithelial defects.



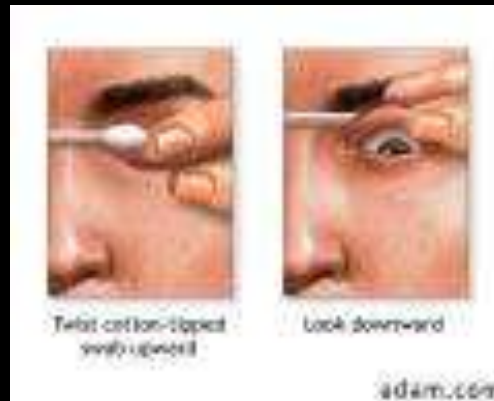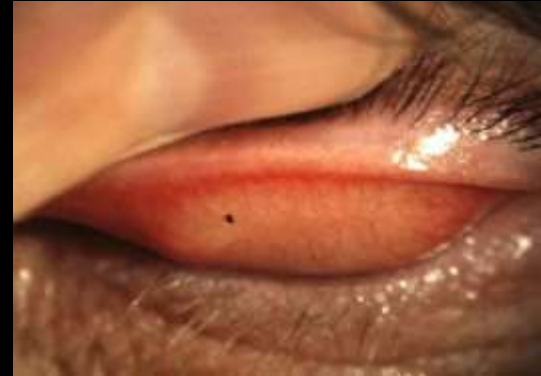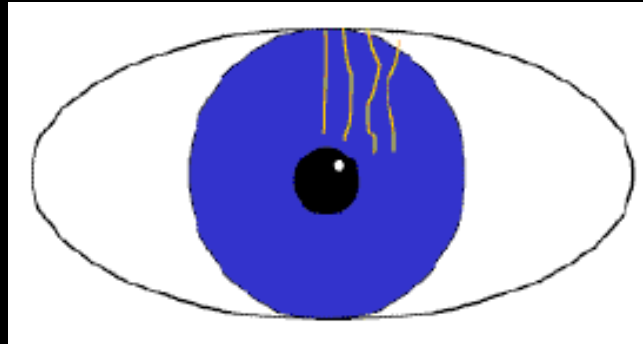
Jordan M. Graff, MD

U of Iowa, 2004

Fluorescein Stain

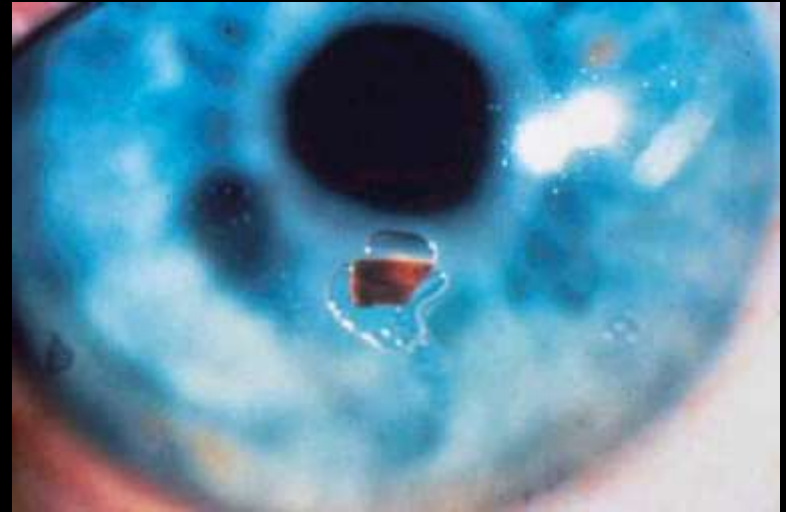

Linear epithelial defects suggestive of foreign body under the eye lid



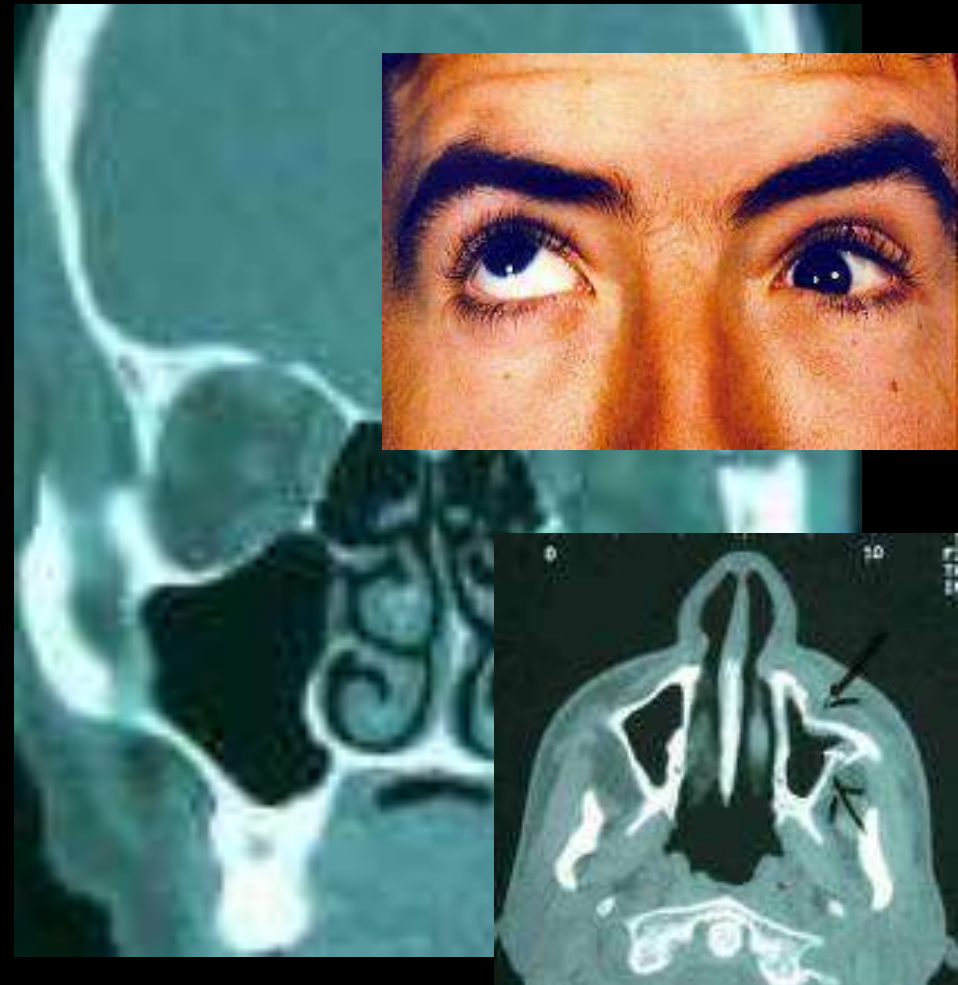Corneal Foreign Body

- Treatment
 - Apply topical anesthetic
 - Remove foreign body with sterile irrigating solution or moistened sterile cotton swab
 - Never use needle
 - Apply antibiotic ointment
 - 24-hour follow-up is mandatory
 - Refer if foreign body cannot be removed



4. Orbital Blowout Fracture

- Signs & Sx' s:
 - Enophthalmos
 - Diplopia
 - Impairment of eye movement 2^o to EOM entrapment, orbital hemorrhage or nerve damage
 - Orbital emphysema
 - Infraorbital n. anesthesia
- CT should include axial and coronal cuts

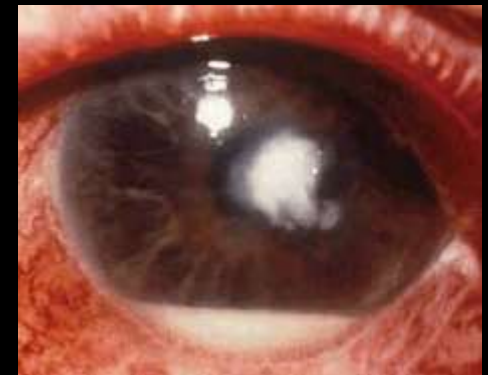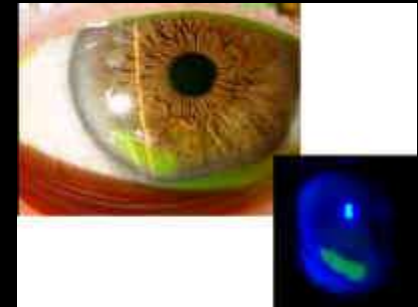
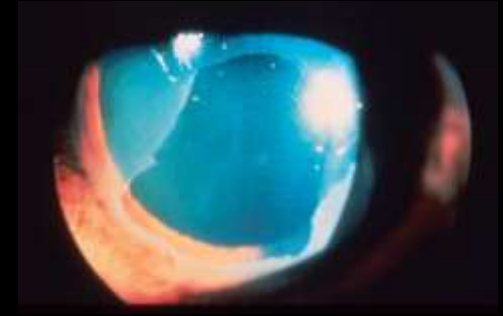


Orbital blowout fracture

- Disposition - If no diplopia, minimal displacement, and no muscle entrapment, discharge with ophthalmology follow up within a week.
- Surgery - For enophthalmos, muscle entrapment, or visual loss.
- Management:
 - Ice packs beginning in clinic/ED and for 48 hrs will help decrease swelling associated with injury.
 - Elevate head of bed (decrease swelling).
 - If sinuses have been injured, give prophylactic antibiotics and instruct patient not to blow nose.
 - Treat nausea/vomiting with antiemetics.

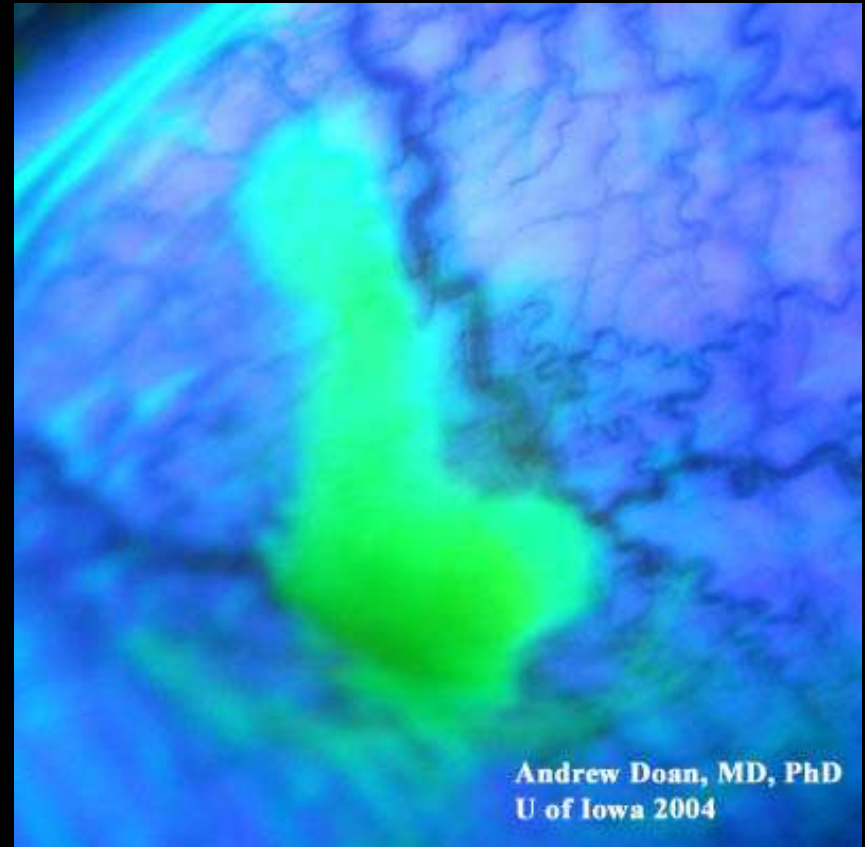
5. Corneal injuries

- Abrasions, lacerations, ulcers
- Symptoms:
 - extreme eye pain, **relieved with lidocaine drops.**
 - Visual acuity usually decreased, depending on location of injury in relation to visual axis.
 - Inflammation leading to corneal edema can decrease VA.
- Diagnosis: fluorescein staining to see epithelial defect.
- Seidel's test for aqueous leakage to diagnose laceration.



Corneal injuries

- **Seidel's test:**
Concentrated fluorescein is dark orange but turns bright green under blue light after dilution.
- This indicates aqueous leakage which is diluting the green dye.



Andrew Doan, MD, PhD
U of Iowa 2004

Management of Corneal Injury

- Topical antibiotics and follow up with ophthalmologist.
- For lacerations, <1 cm, topical antibiotics and discharge with follow up.
- If >1 cm, refer to ophthalmologist to rule out globe rupture and for possible suture placement.
- Avoid contact lenses
- Avoid patching

6. Chemical burns

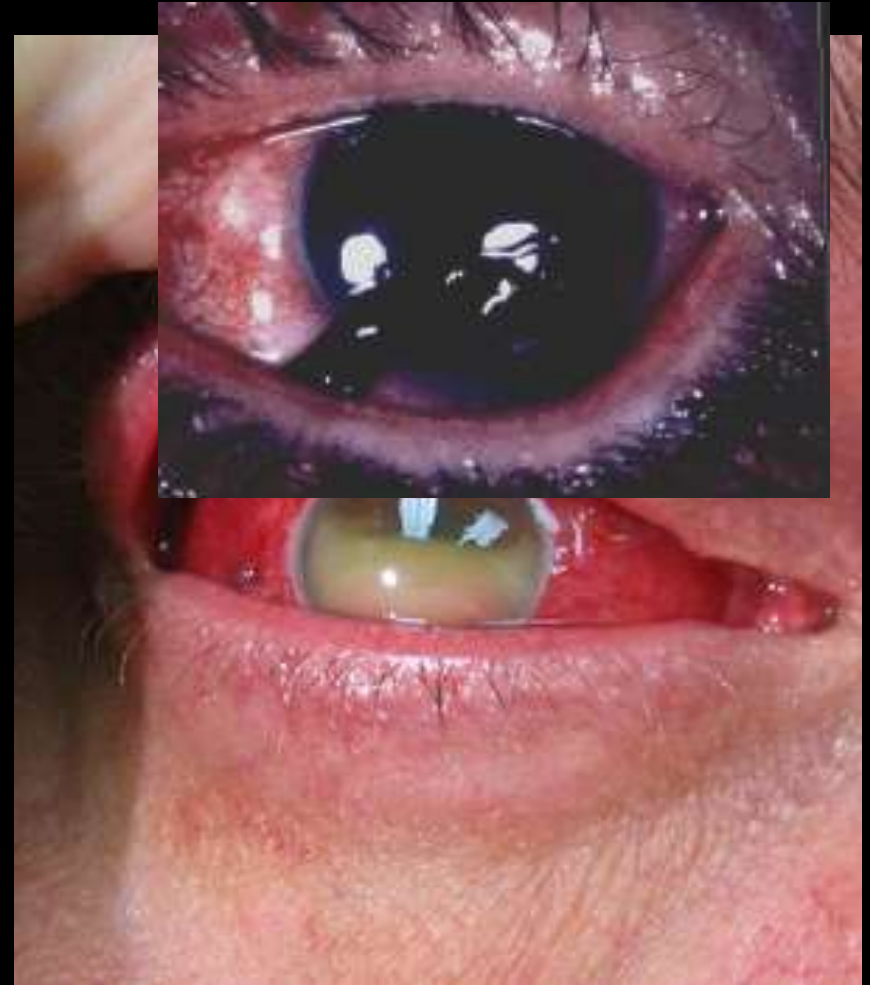- **Emergency!!!** - Every minute counts
- Do not waste time on Hx and PE
- Alkali burns more common and worse than acid
 - Alkali – saponification – denatures collagen, thromboses vessels
 - Household cleaners, fertilizers, drain cleaners
 - Acid – coagulation, H^+ precipitates protein - barrier
 - Industrial cleaners, batteries, vegetable preservatives

6. Chemical burns - Initial Treatment

- Immediate copious irrigation
 - Topical anesthesia (tetracaine)
 - Can use NS, LR, irrigate at least 30 min
 - Angiocath or irrigating lens can be used
 - Lids should be retracted and fornices swabbed for particulate matter
 - Check pH with litmus paper after initial irrigation
 - Continue irrigating until pH 7.0 – 7.3
 - Once pH is stabilized
 - Cycloplegic agent (0.25% scopolamine)
 - Broad-spectrum antibiotic (ciprofloxacin, ofloxacin [Ocuflox], gentamicin, or tobramycin [Tobrex]) should be applied.
 - Refer to ophtho immediately w/o stopping irrigation.

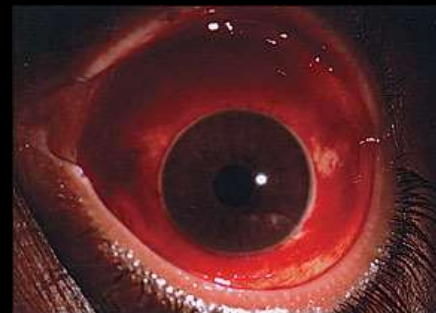
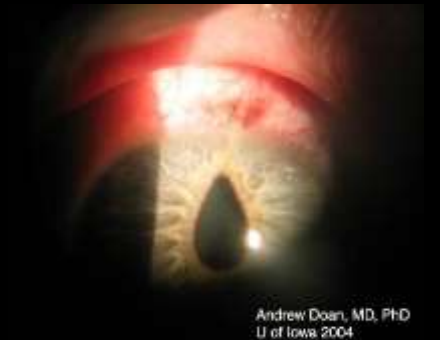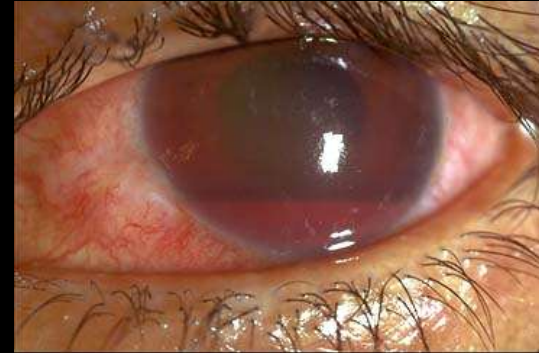
7. Ruptured globe

- Penetrating trauma leads to corneal or scleral disruption and extravasation of intraocular contents.
- Can lead to:
 - Irreversible visual loss
 - Endophthalmitis - *inflammation of the intraocular cavities*



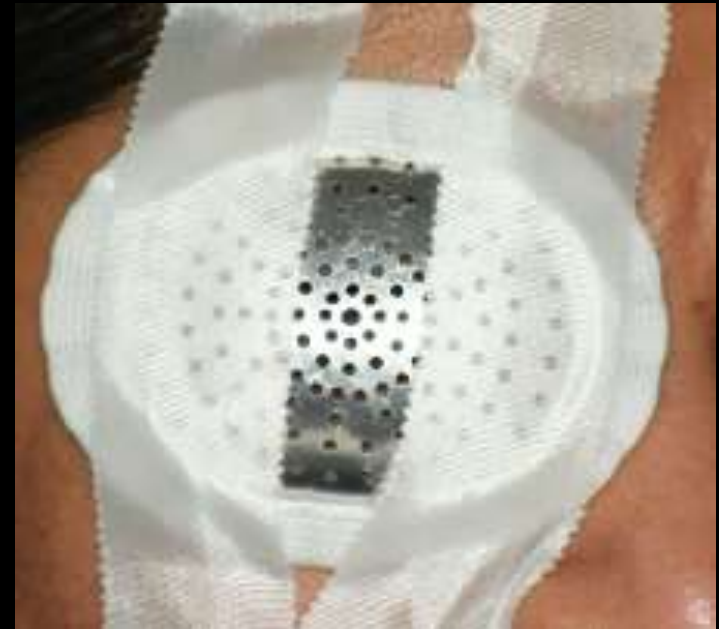Ruptured Globe

- Signs and symptoms:
 - pain, decreased vision
 - hyphema
 - loss of anterior chamber depth
 - “tear-drop” pupil which points toward laceration
 - severe subconjunctival hemorrhage completely encircling the cornea.
- Diagnosis: positive Seidel’s test, clinical exam.



Ruptured Globe Management

- Stop the examination
- Cover with metal eye shield or styrofoam cup. DO NOT PATCH.
- Consult ophthalmology immediately
- Do not perform tonometry.
- CT head and orbit to evaluate for concomitant facial/orbital injury.
- NPO, tetanus
- Antibiotics: Cefazolin + ciprofloxacin provides good coverage.
- Antiemetics and analgesics decrease risk of Valsalva or movement which could increase IOP.

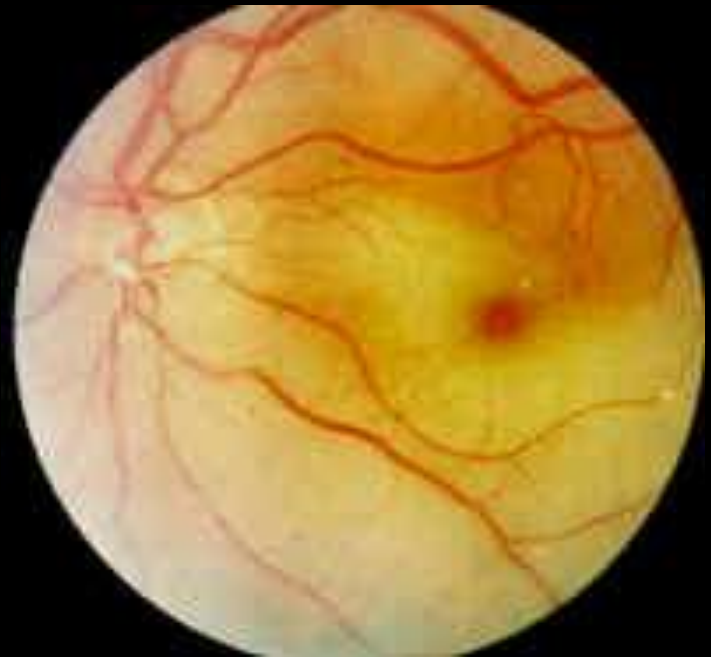

8. Central Retinal Artery Occlusion

- Etiology:
 - Emboli – cardiac, atherosclerotic, fat
 - Vasculitis
 - Coagulopathy
 - Sickle cell
- Signs and Symptoms:
 - Sudden onset severe monocular vision loss over seconds
 - Usually preceded by amaurosis fugax
 - 90% will have visual acuity of counting fingers or less
 - After visual activity, do IOP, pupillary response (APD common)
 - Dilate pupils immediately and perform fundoscopic exam

CRAO

- Narrow arterioles
- Optic disc and retinal pallor
- **Cherry red spot** at fovea (due to maintained perfusion of cilio-retinal artery)
- Emboli seen – 20%

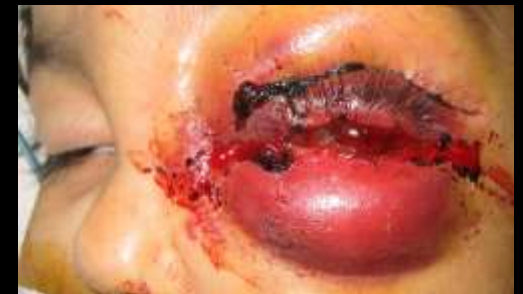
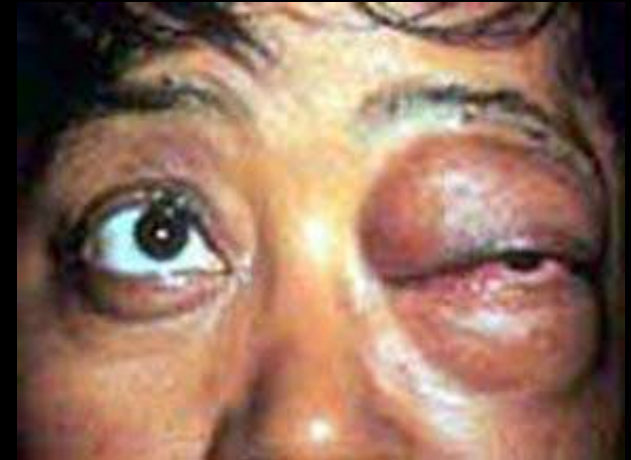
Treatment of CRAO

- Must have VERY high index of suspicion, especially in patients with appropriate risk factors.
 - Immediate referral to an ophthalmologist. Retina can become irreversibly damaged in 100 min.
 - Mannitol 0.25-2.0 g/kg IV or acetazolamide 500 mg PO once to reduce IOP.
 - Carbogen inhalation (95 percent oxygen and 5 percent carbon dioxide)
 - Oral nitrates
 - Lay the patient flat on his/her back
 - Massage orbit. This is thought to help dislodge the clot from a larger to smaller retinal artery branch, minimizing area of visual loss.
 - Ophthalmologist may perform paracentesis of aqueous humor to reduce IOP.

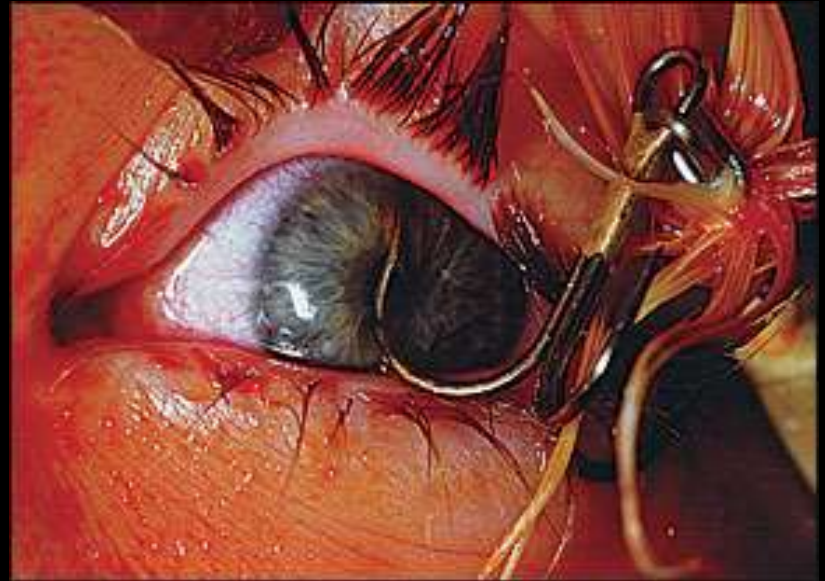9. Retrobulbar hematoma

- Acute orbital compartment syndrome 2° to blunt or penetrating trauma
- Hemorrhage into closed space of orbit
- ↑ IOP leading to vision loss from optic nerve damage / retinal ischemia
- **Clinical diagnosis:**
 - Ocular pain, APD, proptosis, ophthalmoplegia, diminished vision, ↑ IOP
- Immediate lateral canthotomy and cantholysis indicated if IOP > 40mmHg or vision loss



What Do You Do?

1. Stabilize hook
2. Brief exam to document visual acuity, pupillary responses, visual fields
3. Protect eye from further damage
4. NPO, Tetanus, IV Abx
5. Pain control, antiemetics
6. Send to Ophtho!



References

- Rodriquez J. Prevention and Treatment of Common Eye Injuries In Sports. *American Family Physician*. April 2003.
- <http://eyelearn.med.utoronto.ca/default.htm>
- www.cgi.ualberta.ca
- <http://www.opt.pacificu.edu/ce/catalog/10310-SD/Triage.html>
- Bashour, Mounir. *Corneal Foreign Body*. www.emedicine.com. Accessed: November 8, 2007.
- Goodall, KL et al. *Lateral canthotomy and inferior cantholysis: an effective method of urgent orbital decompression for sight threatening acute retrobulbar hemorrhage*. *Injury* 1999 30(7): 485-90.
- Leibowitz HM. *The red eye*. *N Engl J Med*. 2000 Aug 3;343(5):345-51.
- Melsaether, Cheri. *Ocular Burns*. www.emedicine.com. Accessed: November 9, 2007.
- Pokhrel, Prabhat K, et al. *Ocular Emergencies*. *American Family Physician*. 2007 Sep 15; 76(6).
- Vernon, Steven Andrew. **Differential Diagnosis in Ophthalmology: Chapter 5**. McGraw Hill: 1999.
- Wiler, Jennifer. *Diagnosis: Orbital Blowout Fracture*. *Emergency Medicine News*. 2007 Jan. 29(1) p 33.